



Journal Homepage: - [www.journalijar.com](http://www.journalijar.com)

## INTERNATIONAL JOURNAL OF ADVANCED RESEARCH (IJAR)

Article DOI: 10.21474/IJAR01/10468

DOI URL: <http://dx.doi.org/10.21474/IJAR01/10468>



### RESEARCH ARTICLE

#### MANAGEMENT OF FRACTURED FUNCTIONAL CUSP OF MAXILLARY FIRST MOLAR: A CASE REPORT

Dr. Anwetakshmi Ray, Dr. Karthik Shetty, Dr. Anirudh Garg and Dr. Sreelakshmi Pradeep

#### Manuscript Info

##### Manuscript History

Received: 07 December 2019

Final Accepted: 10 January 2020

Published: February 2020

##### Key words:

Cast Metal Restoration, Fracture, Inlay

#### Abstract

Loss of tooth structure has been a common mishap, occurring due to various reasons like fracture, caries or mechanical preparation. Maxillary and mandibular molars have been the most common teeth experiencing a major amount of masticatory load, therefore facing an increased risk of fracture. The most commonly fractured cusps have been the functional cusps as the load bearing has always been high. Loss of such areas may not be restorable with direct techniques and restorative materials like amalgam or composite. Therefore, a need to replace the functional cusp requires replacement through indirect restorative procedures using cast metal restorations like inlay.

Copy Right, IJAR, 2020, All rights reserved.

#### Introduction:-

Inlay in dentistry was first introduced by Dr. Philbrook, in 1897. This followed the introduction of cast gold restoration technique, given by Taggart.<sup>1</sup> The amount of tooth structure that remains, dictates the choice of restoration. Such teeth with extensive loss of tooth structure cannot be restored by direct restoration due to its inability to provide the required resistance and retention form. Therefore, indirect restorations such as inlay, onlay, and overlay are the solution to such teeth. These restorations provide sufficient resistance and retention form for the overall function and form of the debilitated tooth.<sup>2</sup>

#### The indirect restorations can be considered in the following case scenarios:<sup>1</sup>

1. Extensive tooth involvement
2. Restoration of endodontically treated teeth
3. Occlusal correction
4. Subgingival restoration
5. For better control over contact and contours
6. Teeth at risk of fracture

#### Case Report:

A 56 years old man reported to the Department of Conservative Dentistry and Endodontics with a chief complaint of sensitivity in his left upper back tooth region since 7 to 8 days, prior to his visit. His medical history and family history were non-contributory. Past dental history revealed restored teeth with respect to 27 and 28. On general examination patient was conscious and well oriented in terms of time, place and person. Extra oral examination revealed no abnormality. Intra oral examination showed fractured cusp with respect to 26, cervical abrasion 25, 26, root caries with respect to 27, 28. Pulp sensibility test showed 26 as vital which responded normally to EPT (Electric Pulp Test). The diagnosis was given as cusp fracture of 26 involving enamel and dentin.

Corresponding Author:- Dr. Anwetakshmi Ray

**The suggested treatment options give to the patient were as following:**

1. Amalgam restoration
2. Direct and indirect composite restoration
3. Indirect inlay

Indirect inlay was the choice of treatment for this case. Local anesthesia was administered to prevent sensitivity and discomfort. Occlusal divergence was achieved by using by using No.271 carbide bur [figure 6: (b)] and finishing of the cavity was performed by using 169L carbide bur [figure 6: (a)], with the final cavity depth of 1.5mm. Bevel was placed with a flame shaped bur. MTA (Mineral Trioxide aggregate) was placed at the pin point exposure site of the axial wall, followed by temporary restoration. Preliminary impression for upper and lower arch were made and casts were poured. Custom tray was fabricated for the upper arch. In the next visit, temporary restoration [Figure 6: (d)] was removed and final impression was made using polyether elastomeric impression [figure 2] and cast was poured. Wax pattern was fabricated and invested using type II inlay wax after the die cutting [figure 5: (a), (b)], followed by casting. The metal inlay was then polished and finished along with the evaluation for the fit, using the cast. This final inlay was then placed in patient's mouth and checked for occlusion and high points followed by final cementation of the restoration [Figure 5: (c)] using type I, luting GIC [Figure 6: (c)]. The excess cement was removed with the help a sharp explorer and dental floss. Following cementation, patient was given oral hygiene instructions along with demonstration of brushing technique and flossing, on a model.

**Discussion:-**

Silver amalgam being the oldest restorative material, has been time tested for its good compressive strength but it has the disadvantage of getting fractured due to weak marginal strength. Composite restoration despite being esthetic and operator friendly, undergoes unavoidable polymerization shrinkage leading to hypersensitivity.<sup>2</sup> Therefore, these options were surpassed. Porcelain fused to metal or full ceramic crown can be considered for large and extensive cavities, such as the present case but the only disadvantage being, requirement of excessive tooth cutting for accommodating the ceramic.<sup>3</sup>

Cast metal inlay is considered as one of the best possible restoration in cases such as the present one. This is attributed to the good compressive strength and marginal integrity, providing the ability to withstand heavy masticatory forces.<sup>4</sup> In the present case, the same was required for the restoration of 26 that had undergone fracture.

**Few other added advantages of cast metal inlay are enumerated as following:**

1. Cost effective
2. Patient's compatibility and preference
3. Longevity
4. Better margin visualization
5. Better control and production of contact and contours

The maintenance of gingival and periodontal health is important for the long run survival of the restoration and for the functional purpose. Care should be taken to avoid over or under contouring, since it is injurious to gingival health. Opting for the indirect method allows better control over the contact and contours hence, maintaining the gingival and periodontal health. For the same reasons, margins were kept supragingival, as they are best suited for adaptation and gingival health.

**Conclusion:-**

Cast metal inlay provides remarkable restoration that might be overlooked and under used in dentistry. The technique definitely requires multiple patient visits and good laboratory support but results in a highly durable and long-lasting restoration. In the present case, cast metal inlay was preferred as the choice of treatment since, clinical situations such as this, were beyond the capability of amalgam or composite restorations. Cast metal restorations also provides a source for restoring an ideal occlusal anatomy, including contact and contours, keeping them in service for years.

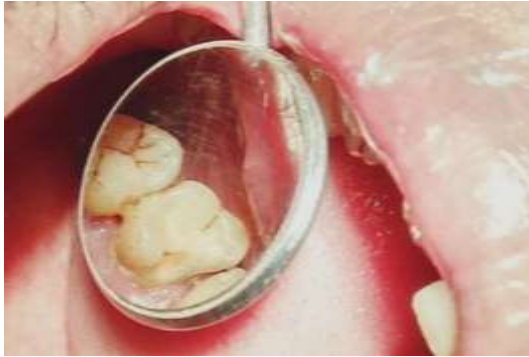

Fig 1:- Fractured cusp.

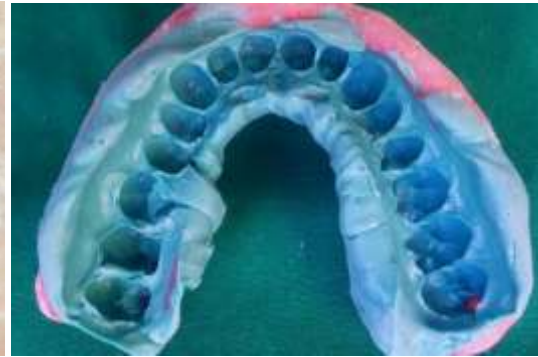

Fig 2:- Polyether impression.

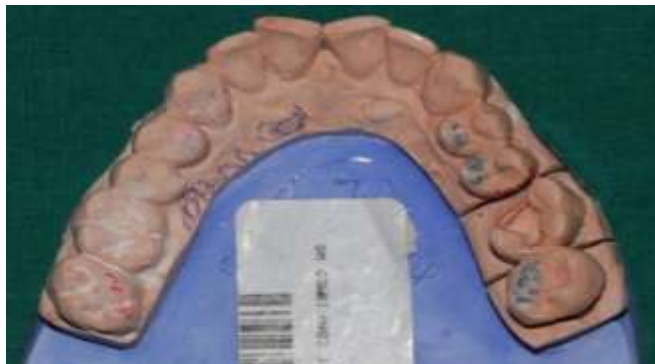

Fig 3: Maxillary cast.

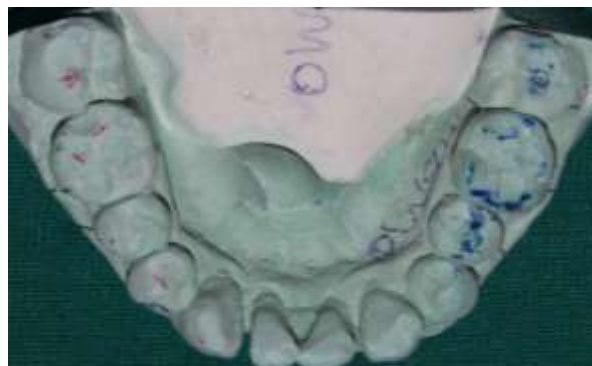

Fig 4:- Mandibular cast.

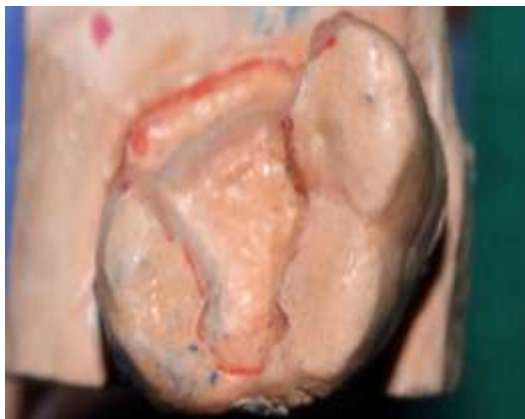

Fig 5:- (a) Die in occlusal view.

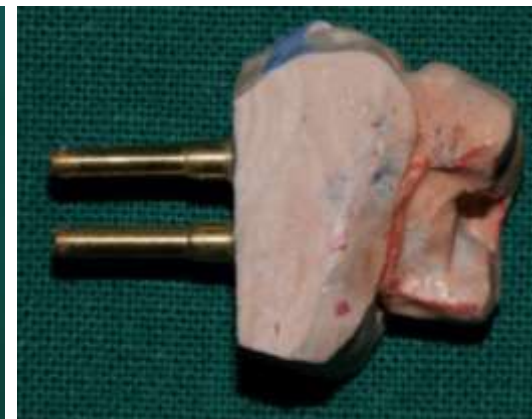


Fig 5:- (b) Die in proximal view.

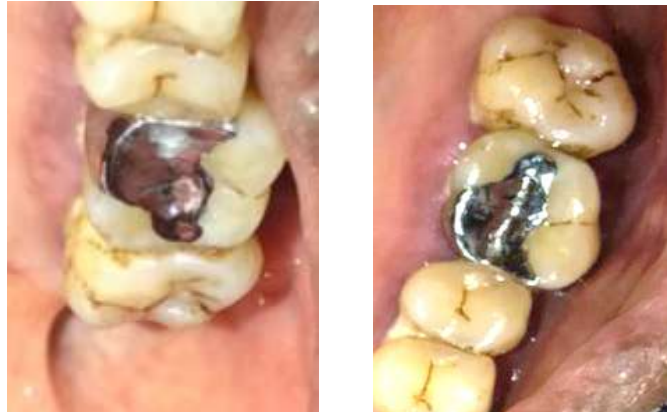

Fig 5:- (c) Post-operative photograph of 26 with the cemented inlay.



Fig 6:- (a) No.169L carbide bur, Burs and materials used.




Fig 6: (b) No.271 carbide bur.

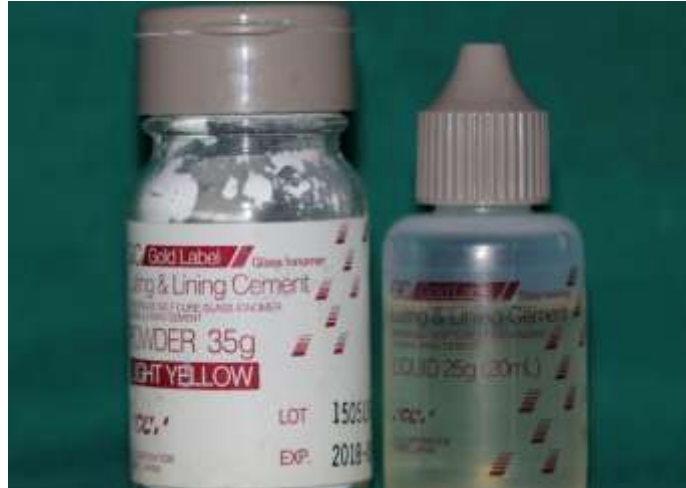

Fig 6: (c) Glass Ionomer Cement

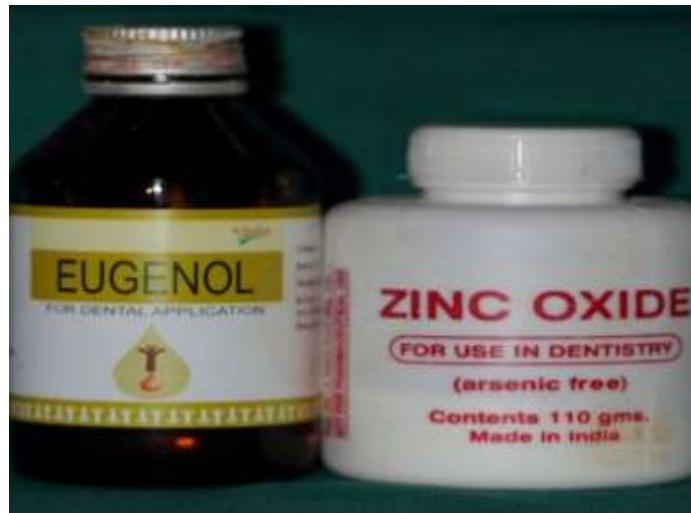

Fig 6: (d) Zinc Oxide Eugenol Cement.

#### References:-

1. Deshpande PM, Metta K, Prashanth BR, Naik RR. Adjacent Interproximal caries–The best treatment of choice is mod inlay: A case report; 2016.
2. Marzouk MA, Simonton AL, Gross RD. Operative dentistry: modern theory and practice. Ishiyaku EuroAmerica, Incorporated; 1985.
3. Prasad P, Gaur A, Kumar V, Chauhan M. To evaluate and compare postcementation sensitivity under Class II composite inlays with three different luting cements: An In vivo study. Journal of International Oral Health. 2017 Jul 1;9(4):165.
4. Ritter AV. Sturdevant's art & science of operative dentistry-e-book. Elsevier Health Sciences; 2017 Dec 20.