



ISSN NO. 2320-5407

Journal Homepage: - www.journalijar.com

INTERNATIONAL JOURNAL OF ADVANCED RESEARCH (IJAR)

Article DOI: 10.21474/IJAR01/3287
DOI URL: <http://dx.doi.org/10.21474/IJAR01/3287>



INTERNATIONAL JOURNAL OF
ADVANCED RESEARCH (IJAR)
ISSN 2320-5407
Journal homepage: <http://www.journalijar.com>
Journal DOI: 10.21474/IJAR01

RESEARCH ARTICLE

FOURNIERS GANGRENE CAUSED BY BACTERIA AND FUNGY (CASE REPORT).

Didbaridze T.¹, Kochiashvili D.², Kvakhajelidze V.³, Kochiashvili G.³ and Gogokhia N.⁵

1. Microbiologist MD. PhD. TSMU The First University Clinic (Tbilisi, Georgia).
2. Head of Department of Urology, TSMU Professor. MD. PhD (Tbilisi, Georgia).
3. Urologist. TSMU Department of Urology (Tbilisi, Georgia).
4. TSMU Department of Urology. Assistant professor. MD. PhD(Tbilisi, Georgia).
5. Head of Clinical laboratory MD. PhD. TSMU the First University Clinic (Tbilisi, Georgia).

Manuscript Info

Abstract

Manuscript History

Received: 14 December 2016
Final Accepted: 16 January 2017
Published: February 2017

Key words:-

Fournier,s gangrene(FG), Candida albicans, diabetes mellitus .

Copy Right, IJAR, 2017,. All rights reserved.

Introduction:-

Fournier's gangrene characterized by fulminant necrotizing fasciitis of the perineal, genital or perianal regions, is generally caused by aerobic and anaerobic bacteria. Although it is thought to be an idiopathic process, Fournier's gangrene has been shown to have a predilection for patients with diabetes mellitus is reported to be present in 20–70% and chronic alcoholism in 25–50% patients and immunocompromised patients%. [1] The focus of infection is usually located in the genitourinary tract(20-40%), lower gastrointestinal tract(30-50%) or skin(20%). The development and progression of the gangrene is often fulminating and can rapidly lead to multiple organ failures and death(7.5-50%). Characteristically in Fournier's gangrene exists synergism between theoretically low aggressive bacteria alone. For example, one microorganism might produce the enzymes necessary to cause coagulation of the nutrient vessels. Thrombosis of these nutrient vessels reduces local blood supply. Thus, tissue oxygen tension falls. The resultant tissue hypoxia allows growth of facultative anaerobes and microaerophilic organisms. These latter microorganisms, in turn, may produce enzymes (e.g., lecithinase, collagenase), which lead to digestion of fascial barriers, thus fueling the rapid extension of the infection [2,3]. The most commonly isolated aerobic microorganism are *Escherichia coli*, *Klebsiella pneumonia*, *Staphylococcus aureus*, *Proteus* spp, *Corynebacterium* spp, *Enterococcus* spp. The most commonly isolated anaerobic microorganism is *Bacteriodes fragilis*, *Clostridium*, *Fusobacterium*. [4,5]. Actually both aerobes and anaerobes are present in the tissues but anaerobes are less frequent isolated because these samples are more difficult to preserve. In some series, a mean of four different organisms is cultured from each patient [6]. Rare reports of other organisms being cultures include *Candida albicans* and *Lactobacillus gasseri* . [7.8]

Clinical Case Report:-

We report a case of Fournier's gangrene caused by *Candida albicans* and *Klebsiella pneumoniae*. A 41-year-old man with diabetes mellitus was admitted to the First University Hospital at Urology Department with following

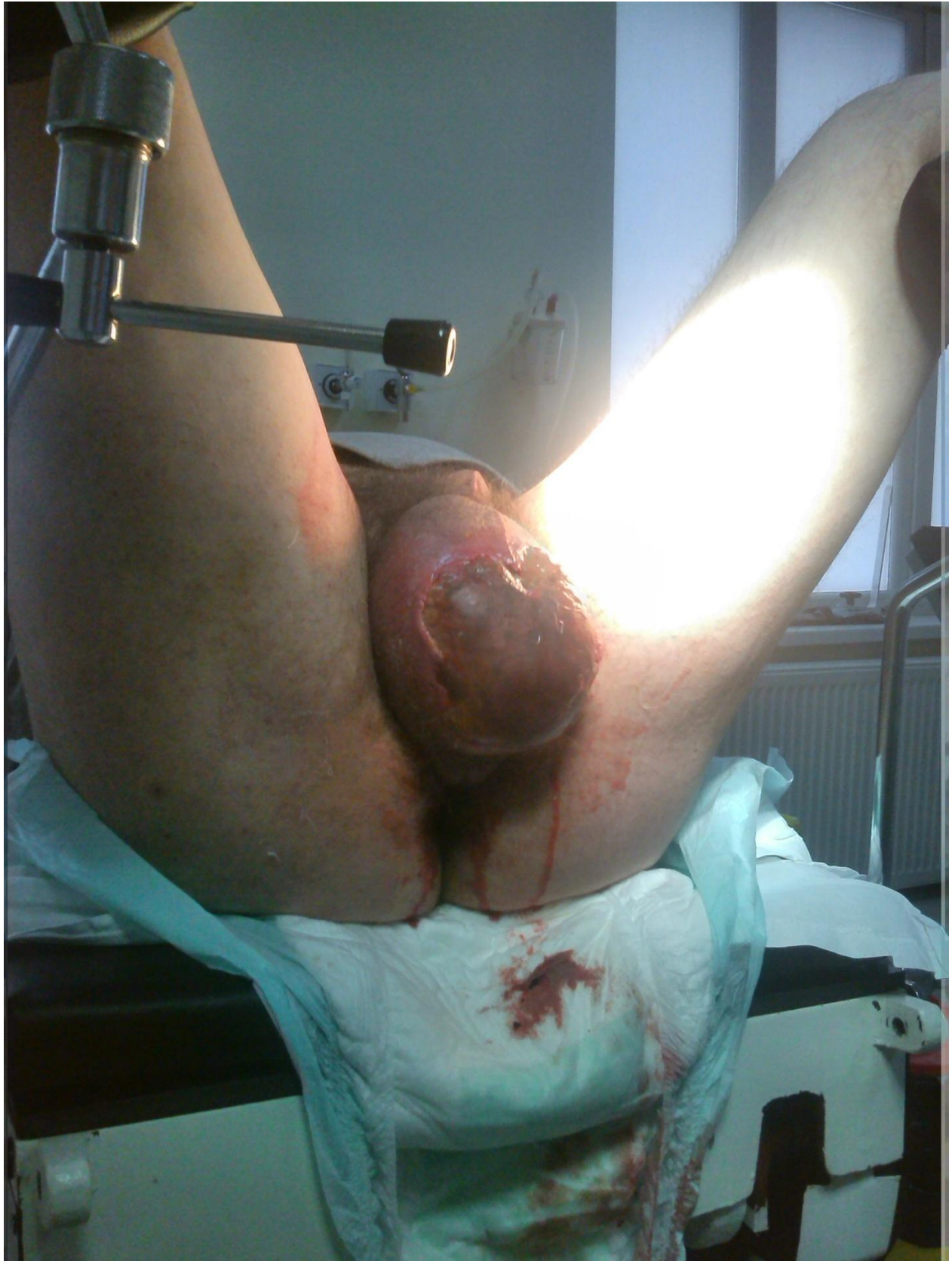Corresponding Author:- Didbaridze T.

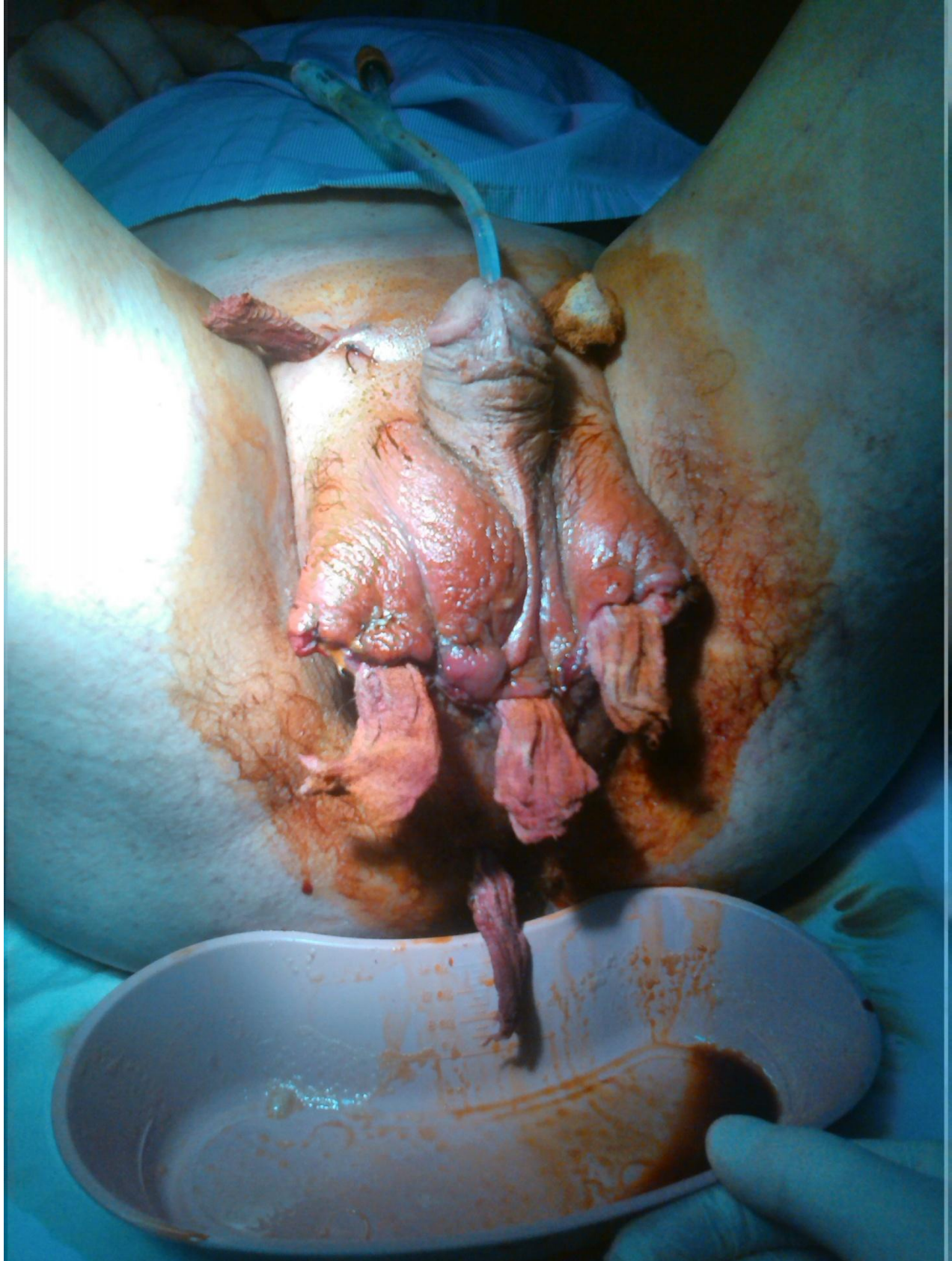
Address:- Microbiologist MD. PhD. TSMU The First University Clinic (Tbilisi, Georgia).

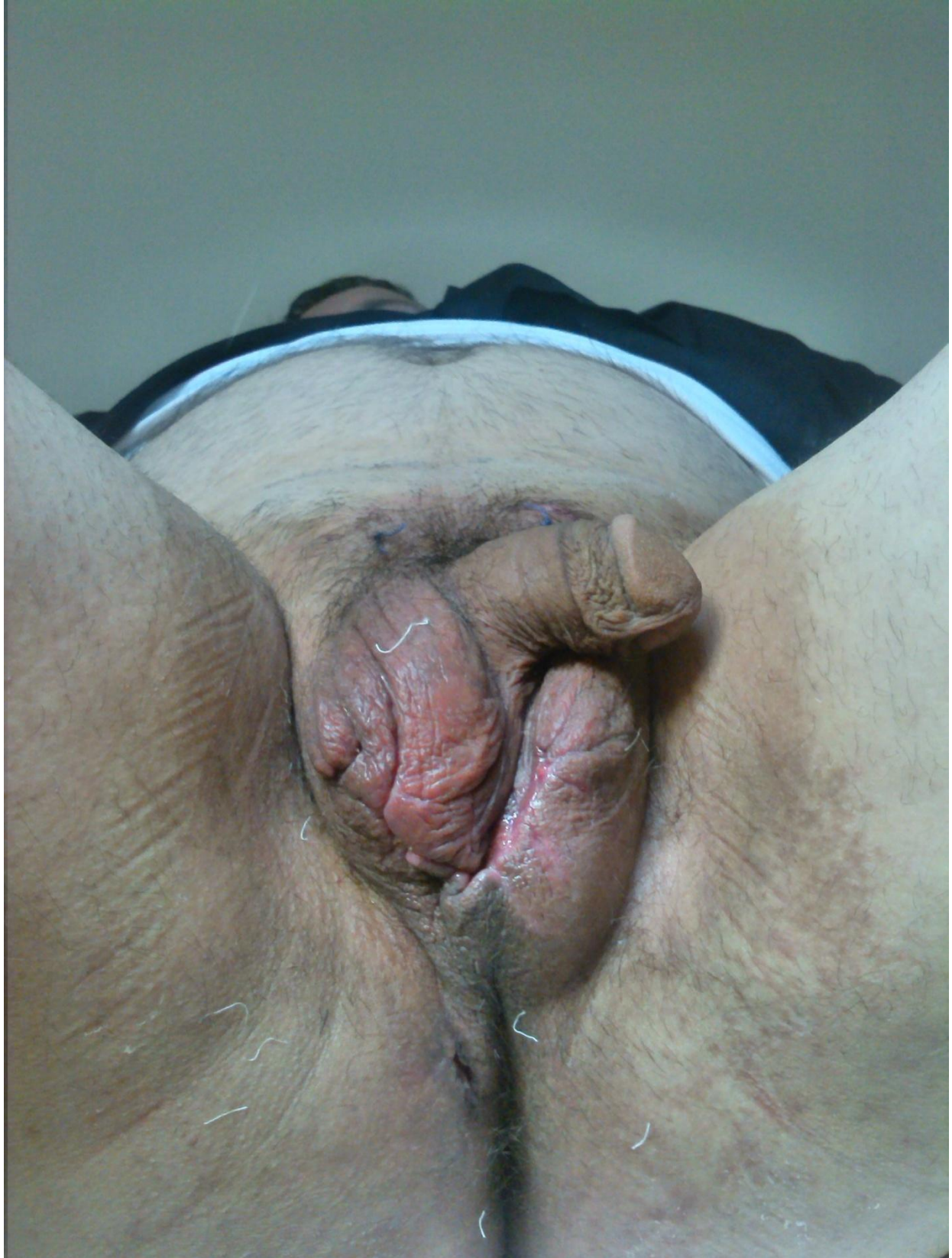
complains: common weakness, body temperature 39°C, pain in the scrotal region. A 10 days before he was hospitalized, a patient started suffer from 2 cm perineum erythema and pain in the perianal region. On examination, he was conscious. There was no pallor, icterus, and lymphadenopathy. His pulse was 105 /min, regular, and good volume. His blood pressure was 150/90 mm Hg. Systemic examination revealed no abnormality. Local examination of the scrotum revealed that scrotum was enlarged, edematous, and tender along with palpable crepitations. There was 8 cm necrotic skin lesions over the scrotum and foul-smelling purulent discharge. A provisional diagnosis of FG was made. Fournier's gangrene severity index (FGSI) was 8. A score of less than 9 is associated with 78% probability of survival. (Picture 1) He was prepared for emergency surgical debridement. Blood haemogram revealed hemoglobin 15.5g/dl, white cell count— $12.0 \times 10^3/\mu\text{l}$. Biochemical parameters: serum creatinine- $104 \mu\text{m/l}$, random blood sugar- 500mg%. Operative techniques under general anesthesia included: revision of scrotum and testicles with opening tunica vaginalis, drainage, resection of scrotum, necrectomy. Pus was taken for a bacteriological research under compliance with the appropriate protocol and sent for culture and sensitivity test. Empirical treatment was started with Piperacilline and Tazobactam and metronidazole. The bacteriological research included: isolation of a pure culture, Gram staining, use of the rapid identification systems (api20E, api20Caux, biomérieux) and Antimicrobial Susceptibility Testing (AST) determination through Kirby-Bauer method by using of standard discs (EUCAST guidelines). Pus was cultured on the enrichment and differential-diagnostic medium. After 18-24 hours of aerobic and anaerobic (Gen-Bag biomérieux) incubation at 37 °C, appeared growth of mucoid colony on the bloody agar (TSA 5% with sheep blood) and on Endo agar (for Enterobacteriaceae family) which were stained by use of Gram procedure and bacteria were identified by the amplification profile index special panel (api20E), identification of the bacteria was determined by Apiweb. The isoaited was a Gram-negative, nonmotile, encapsulated, lactose-fermenting, facultative anaerobic, rod-shaped bacterium *Klebsiella pneumoniae* $10^5/\text{ml}$. Fungi *Candida albicans* $10^8/\text{ml}$ was isolated on Sabouraud dextrose agar. Since pus culture revealed *C. albicans*, fluconazole was added to the therapy. Antibiotic therapy regimen included Piperacillin and Tazobactam, metronidazole and fluconazol. He responded to the treatment very well. Regular wet dressing was done along with topical application of povidone iodine. (Picture 2) He was discharged on 6nd postoperative day with pentose drain to prevent the build up of fluid, which was removed after three days from discharg. After 2 weeks the wound was completely healed, scrotum return in the normal size and shape, painless (Picture 3).

Conclusion:-

In our opinion this case is interesting because of *Candida albicans* caused Fournier's gangrene is very rare; This case has been reported to emphasize that yeasts should be considered as pathogenic agents in diabetic patients with gangrene. Fungal infections should be considered as rare causes of necrotizing fasciitis and antifungal treatment considered in at-risk immunodeficient individuals. FG with diabetes mellitus always poses a greater challenge in reducing morbidity and mortality. It is recommended to adopt a multidisciplinary approach in treating a case of FG to achieve a low morbidity and mortality, especially in presence of the comorbidity like diabetes and multi organ failure.







Reference:-

1. Corcoran AT, Smaldone MC, Gibbons EP, et al. Validation of the Fournier's gangrene severity index in a large contemporary series. *J Urol*. 2008
2. Durand CM, Alonso CD, Subhawong AP, et al. Rapidly progressive cutaneous *Rhizopus microsporus* infection presenting as Fournier's gangrene in a patient with acute myelogenous leukemia. *Transpl Infect Dis*. 2011
3. Grabe M, Bishop M, Bjerklund-Johansen T, et al. Guidelines on urological infections. European Association of Urology. 2010. [Accessed April 28, 2014]. Available at <http://www.uroweb.org/gls/pdf/Urological%20Infections%202010.pdf>. Weinfeld A B, Kelley P, Yuksel E. *et al* Circumferential negative-pressure dressing (VAC) to bolster skin grafts in the reconstruction of the penile shaft and scrotum. *Ann Plast Surg* 2005;54:178–183.
4. Hejase M J, Simonin J E, Bihrl R. *et al* Genital Fournier's gangrene: experience with 38 patients. *Urology* 1996;47:734–739.
5. Capelli-Schellpfeffer M, Gerber G S. The use of hyperbaric oxygen in urology. *J Urol* 1999;162:647–654.
6. Stephens B J, Lathrop J C, Rice W T. *et al* Fournier's gangrene: historic (1764–1978) versus contemporary (1979–1988) differences in aetiology and clinical importance. *Am Surg* 1993;59:149–154.
7. Martinelli G, Alessandrino E P, Bernasconi P. *et al* Fournier's gangrene: a clinical presentation of necrotizing fasciitis after bone marrow transplantation. *Bone Marrow Transplant* 1998;22:1023–1026.
8. Nisbet A A, Thompson I M. Impact of diabetes mellitus on the presentation and outcomes of Fournier's gangrene. *Urology* 2002;60:775–779.