



Journal Homepage: -www.journalijar.com
**INTERNATIONAL JOURNAL OF
 ADVANCED RESEARCH (IJAR)**

Article DOI:10.21474/IJAR01/8197
 DOI URL: <http://dx.doi.org/10.21474/IJAR01/8197>



RESEARCH ARTICLE

EVALUATION OF THE EFFECTIVE SAFE DOSE OF VITAMINA ADMINISTRATION AGAINST EHRlich ASCITES CARCINOMA (EAC) IN MICE.

Nesreen Ahmed Hassaneen¹, Soad Shaker Ali², Sabah M. Hassan^{1,3} and Samar Rabah¹.

1. Biology Department, Science College, King Abdulaziz University, Jeddah Saudi Arabia.
2. Anatomy Department, King Abdulaziz University, Jeddah Saudi Arabia.
3. Department of Genetics, Faculty of Agriculture, Ain Shams University, Cairo, Egypt.

Manuscript Info

Manuscript History

Received: 12 October 2018
 Final Accepted: 14 November 2018
 Published: December 2018

Key words:-

Vitamin A, Olive oil, Cancer, Tumor, antioxidant.

Abstract

Vitamin A is well known as fat soluble vitamin with marked beneficial effects for human health. However, there is contradictory data regarding its safety in cancerous cases.

Purpose: The main objective of the present study was to highlight the importance of searching for the optimum dose of vitamin A that could be considered safe and effective in controlling cancerous growth using Ehrlich ascites carcinoma (EAC) in mice model.

Experimental Design: Healthy 45 male Swiss albino mice, weighing from 30 to 35 g and aged from 8 to 10 weeks old were acclimatized to laboratory conditions for 10 days. Solid tumors were induced by subcutaneous injection of EAC cells (2.5×10^6 cells/mice) in the right thigh of the mice. Different doses of Vitamin A (0.2214, 0.4428 and 0.8856 μ l) were dissolved in olive oil and given to experimental mice. Body weight and tumor size were recorded at 0, 2, 3 and 4 weeks and statistically analyzed. Histological studies for tumor tissues were done after 4 weeks.

Results: Insignificant differences in body weight were found between untreated and treated animals in all groups. Solid tumor size was significantly increased in non-treated mice throughout the experimental duration. Administration of olive oil (O) before and after tumor found to significantly reduce the tumor size compared to untreated mice. The O+T+O group found to have the most decreased tumor size followed by O+T+A, O+T+2A and O+T+4A groups. Histological studies showed degenerative apoptotic changes in all treated groups with mild response in animals receiving 4 doses of Vitamin A.

Conclusion: Administration of vitamin A by cancerous cases must be critically controlled but not decrease tumor size. In the current study, recommended daily dose was found to be controlling EAC solid tumor growth as evidenced by both gross and microscopic examination. High doses must be avoided as it will act as pro-oxidant agents hindering the action of anticancer drugs. The gene expression analysis using some cancer and apoptotic related genes will be done using the same tumor samples for further investigation of vitamin A potential role in tumorigenesis.

Corresponding Author:- Nesreen Ahmed Hassaneen.

Address:- Biology Department, Science College, King Abdulaziz University, Jeddah Saudi Arabia.

Introduction:-

Cancer is a generic term for a large group of diseases that can affect any part of the body [1]. It is defined as an abnormal cell growth with tendency to invade or spread to other parts of the body. Cancer ranks as the fourth leading cause of death in Mediterranean Region [2].

Abnormally high concentrations of free radicals in the body can be caused by exposure to ionizing radiation and other environmental toxins. The production of abnormally high levels of free radicals is the mechanism by which ionizing radiation works and results in tissue damage or cellular transformation [3].

Antioxidants are chemicals that interact with and neutralize free radicals, thus preventing them from causing damage and they are known as free radical scavengers [3]. The body usually makes its own antioxidants, which neutralize body free radicals. These antioxidants are called endogenous antioxidants. However, the body relies on external (exogenous) sources, primarily the diet, to obtain the rest of the antioxidants it needs. These exogenous antioxidants are commonly called dietary antioxidants. Fruits, vegetables and grains are rich sources of dietary antioxidants. Exogenous antioxidants are commonly worldwide taken as dietary supplements. Micronutrient such as vitamin A, C and E are reported to be potent antioxidant [3].

Vitamin A is the name of a group of fat-soluble retinoid, including retinol, retinal and retinyl esters. Vitamin A is involved in immune function, vision, reproduction and cellular communication [4, 5, 6].

Botanical and natural dietary agents have been used for the treatment of cancer throughout history. These dietary agents also can be useful in the prevention of cancer. Epidemiological studies suggest that reduced risk of cancer is associated with high consumption of vegetables and fruits. The major part of total antioxidant activity is from the combination of phytochemicals [7].

Facts that must be taken in mind regarding some previous studies, which find out that, antioxidants accelerate the growth of some cancers [8]. A clinical study showed that supplementing the diet with the antioxidants N-acetylcysteine (NAC) and vitamin E increases the tumor progression and reduces survival in mouse models of B-RAF and K-RAS-induced lung cancer [9]. The authors reported that, RNA sequencing revealed NAC and vitamin E, which are structurally unrelated, produce highly coordinated changes in tumor transcriptome profiles, dominated by reduced expression of endogenous antioxidant genes. NAC and vitamin E increase tumor cell by reducing ROS, DNA damage and P53. Antioxidants accelerate tumor growth by disrupting the ROS-p53 axis [9].

Smokers and other people at high risk for lung cancer could make it worse if they take antioxidant supplements when they developed lung cancer. Mice with lung cancer was found to develop more aggressive tumors and die faster when their diet is supplemented with antioxidants via deactivation of P53, the protein that neutralizes free radicals effect on tumors [10].

Several randomized controlled trials have investigated the effect of antioxidant supplements during cancer treatment and reported that they alter the effectiveness or reduce the toxicity of specific therapies and worsen the outcome of cancer especially in smoker persons [11].

In some preclinical studies, antioxidants have been found to promote tumor growth and metastasis in tumor-bearing mice and increase the ability of circulating tumor cells to metastasize [12]. Therefore, antioxidant supplements should be used with caution. Cancer patients should inform their doctors about their use of any dietary supplement.

Research Objective:-

The main objective of the present study was to highlight the importance of searching for the optimum dose of vitamin A and its dosage regimen that could be considered safe and effective in controlling cancerous growth using Ehrlich carcinoma in mice model.

Materials and Methods:-**Animals:-**

Healthy 45 male Swiss albino mice were obtained from King Fahd Medical Research Center, weighting 30 to 35 g and aged 8 to 10 weeks old. The animals were housed under conditions of controlled temperature (25-30c) with a 12h day/night cycle. They were fed standard mouse pellet diet and given free access to water and were acclimatized to laboratory condition for 10 days before commencement of the experiments.

Animals were divided into five groups (each with 5 animals):

Group I:-

Inoculate with EAC cells (0.2 ml of ascetic fluid containing 2.5×10^6 cells) via intramuscular (IM) and observed for 14 days for tumor size .

Group II:-

Received olive oil (0.2214 μ l) accord to [13] for 14 days and then inoculate with EAC cells (0.2 ml of ascetic fluid containing 2.5×10^6 cells) via intramuscular (IM) and then divided into 4 subgroups:

Group IIa (O+T+A):-

Received olive oil (0.2214 μ l) for 14 days + IP EAC cells inoculation + vitamin A (0.2214 μ l) for 14 days .

Group IIb (O+T+2A):-

Received olive oil (0.2214 μ l) for 14 days + IP EAC cells inoculation + double dose vitamin A (0.4428 μ l) for 14 days

Group IIc (O+T+4A):-

Receive olive oil (0.2214 μ l) for 14 days + IP Ehrlich cells inoculation + 4 time dose Vitamina (0.8856 μ l) for 14 days

Group II d (O+T+O):-

Receive olive oil (0.2214 μ l) for 14 days + IP Ehrlich cells inoculation + olive oil (0.2214 μ l) for 14 days.

Ehrlich Solid Tumor (EST):-

Peritoneal fluid from Ehrlich bearing mice was collected and re-inoculated in the experimental animals and left for 7-10 days. The number of tumor cells per ml of ascetic fluid was determined by counting the cells with the help of hemocytometer. Ehrlich ascites carcinoma (EAC) fluid was injected in to mice intramuscularly in the right thigh in a dose of 0.2 ml of ascetic fluid containing 2.5×10^6 cells. These cells were originally from American Type Tissue Culture Collection (Manassas, VA, USA).

Vitamin A:-

Retinyl acetate powder was purchased from sigma chemicals, St Louis, USA. 0.2214 μ g has been dissolved in 100 μ g olive oil and given to the treatment mice orally, the selected dose of retinyl acetate were equivalent to [13] study.

Study design plan:-**Body Weight changes:-**

Body weights were taken once a week for week one, two, three and four weeks. Animals were examined for BW changes (initial BW on day 0, and final BW on day 30). Net final BW = (final BW - tumor weight).

Determination of tumor circumference:-

Tumor circumference was measured twice a week for week one, two, three and four, using caliper throughout the experiment.

Percent tumor growth inhibition (IR):-

The tumor growth inhibition rate (IR) is calculated using the formula $IR (\%) = (1 - TWt/TWc) \times 100$, where TWt and TWc are the mean tumor weight of treated and control groups

Histopathological examination of tumor:-

Mice were anesthetized using sodium thiopental (0.5%) and were sacrificed by dislocation, and then tumors were collected from mice. Sample from the solid tumor were washed carefully by normal saline then fixed in 10% formalin solution, processed forembedding in paraffin. Sections of 4- μ m thickness were cut, and stained with hematoxylin and eosin for the histological examination. [14]

Statistical Analysis:-

The data were expressed as mean +/- standard error of differences between the groups were calculating by SPSS Version 21 using Person correlation between body weight and thigh size.

Result:-

Body Weight changes:-

Figure (1) showed body weight changes among non-treated and different treated group all through duration of the experiment. Untreated group showed steady Increase over time. Reduction in body weight for all group was observed however , significant (P >0.05) reduction occurred in animal group O+T+O and O+T+A. compared to the untreated and other treated groups

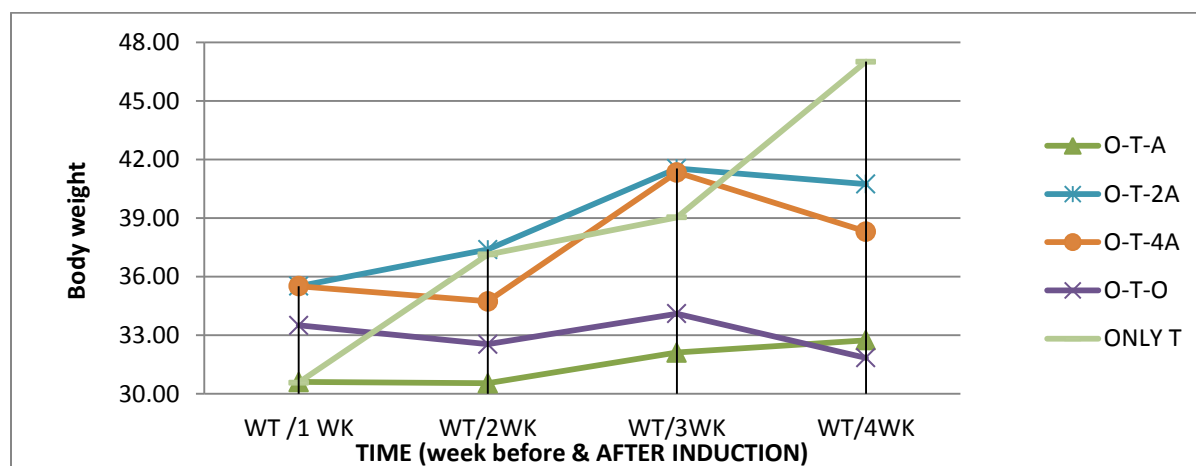


Figure 1:-Body weight changes throughout the experiments of untreated and treated animal groups.

Change in body weight in all groups compared to untreated mice was shown in (Table 1). Marked effect was observed in animals receiving the recommended dose of vitamin A compared to other used doses.

Table 1:-Body weight changes in different mice groups received different doses of vitamin A.

Parameters	ONLY TUOMR group	O+T+O group	O+T+A group	O+T+2A group	O+T+4A group
Initial body weight (g) at day 0	30.57±0.06	33.50±1.93	30.60±1.78	35.51±1.25	35.51±1.25
P-Value		¹ P =0.567	¹ P =0.079 ² P =0.203 ³ P =0.943	¹ P =0.070 ² P =0.182	¹ P =0.242 ² P =0.530 ³ P =0.451

			⁴ P =0.494		
Final body weight (g) at day 30	47.00±1.74	31.84±5.84	32.74±4.28	40.74±0.70	40.74±0.70
P-Value		¹ P =0.486	¹ P =0.059 ² P =0.059 ³ P =0.305 ⁴ P =0.135	¹ P =0.319 ² P =0.319	¹ P =0.627 ² P =0.627 ³ P =0.596

Data are expressed as mean +/- standard error of mean. 1P: significance versus O+T+A group; 2P: significance versus O+T+O group; 3P: significance versus O+T+2A group; 4P: significance versus O+T+4A

From this table it was observed that there were insignificant differences in initial body weight between groups. After 2 weeks of EAC inoculation, significant increase in body weight was observed in un-treated group compared to initial weight (47.00±1.74 versus 30.57±0.06).

Significant reduction in body weight was observed in the 2 groups (O+T+O & O+T+A) compared to untreated groups while insignificant decrease was observed with other vitamin A doses.

Tumor circumference:-

Table (2) &Figure (2) showed tumor circumference (TC) and its correlation to body weight at different periods of experiment. There was positive significant reduction of TC was observed in all treated groups with more response in O+T+O Group followed by O+T+A compared to control group. Other Vitamin A regimens showed partial decrease in tumor size compared with untreated mice.

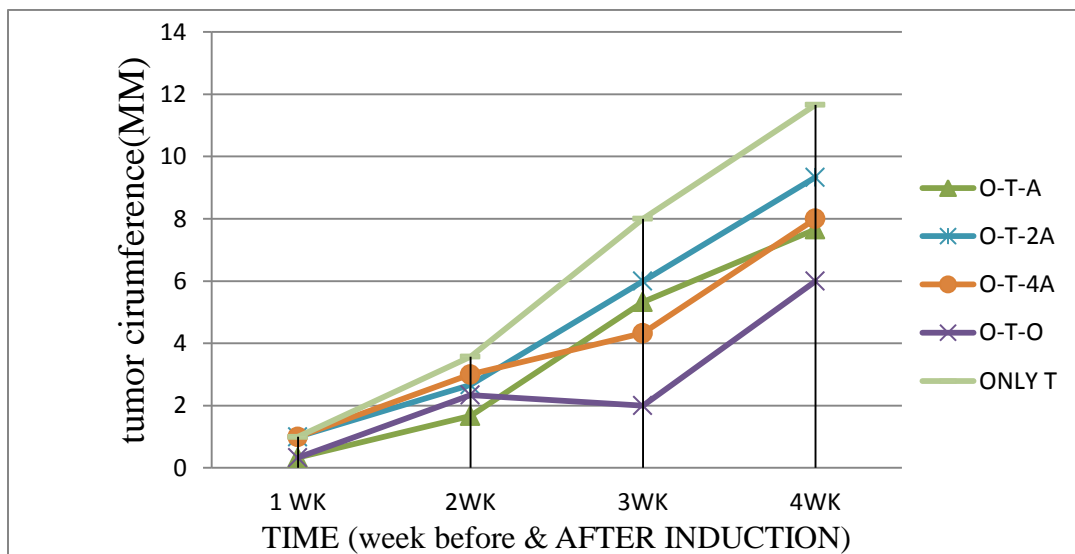


Figure 2:-Tumor size in different mice group received different treatment of vitamin A and olive oil during the experiment.

Table (2) showed tumor circumference (TC) and its correlation to body weight at different periods of experiment. There was positive correlation between tumor circumference and body weight in all groups at the first, 3rd and 4th

Table 2: Correlation between body weight and tumor circumference in different weeks using person correlation

Weeks	Person correlation (r)	Significance (P)
1 st week	0.786	0.001
2 nd week	0.470	0.077
3 rd week	0.688	0.005
4 th week	0.908	0.001

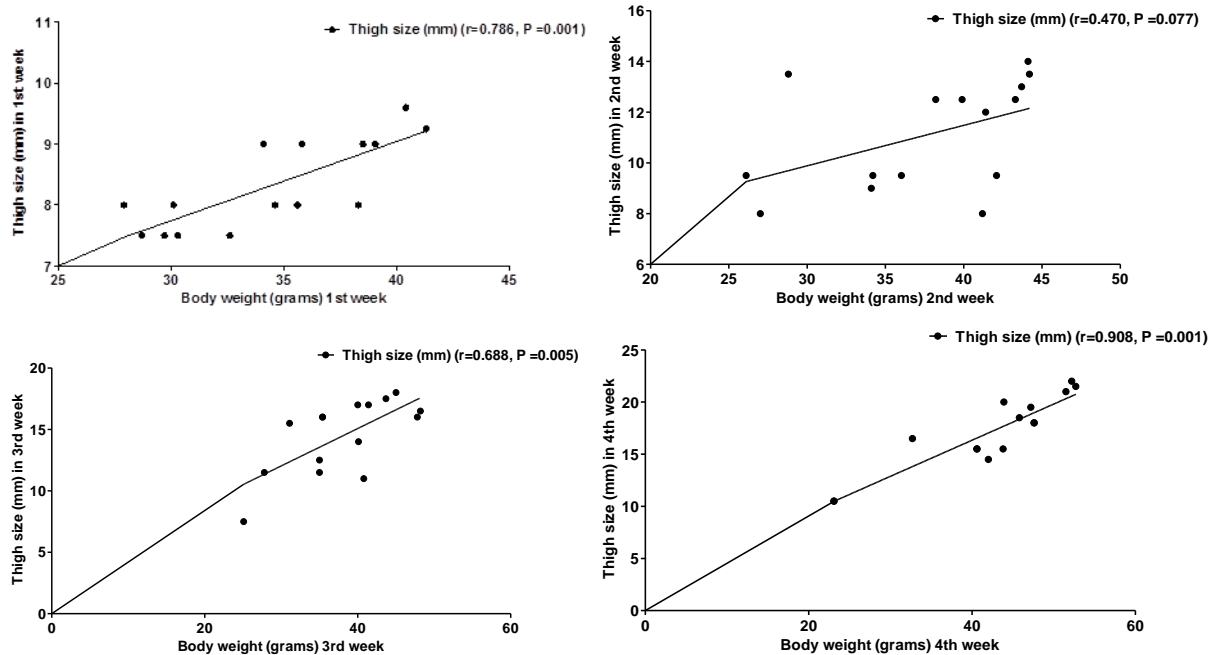


Figure 3:-Correlation between body weight and tumor in circumference in 1rd, 2nd, 3rd.and 4th week Using Person test.

Table 3: Tumor circumference & inhibition rate in treated group

Parameters	untreatedT group	O+T+O group	O+T+A group	O+T+2A group	O+T+4A group
tumor circumference (mm) at day 30	11.66	6	7.66	9.33	8
tumor growth inhibition rate (IR) %	-----	30.87%	21.82%	12.711%	19.96%

As shown in Table (3), the tumor circumference (mm) at day 30 showed decrease in all group campers to untreated group, however the inhibition rate was higher in O+T+O (30.87%, 21.82% respectively) followed by O+T+A camper to other treated groups.

Histological study of solid Tumormass:

In the present study tumor inoculated into mice thigh was observed by light microscope for features of cellular proliferation or degeneration.

In untreated tumor group:-

Tumor tissue showed proliferating cells with pleomorphic euchromtic active nuclei with prominent acidophilic nucleoli (black arrows) .Scattered mitotic figures could be seen (dotted circles). Some of these cells fuse to form giant multi nucleated cells (insert). (Figure3.a)

In olive oil group (O +T+O):-

Tumor tissushowed marked degeneration of most tumor cells are shrunken or with ill-defined outlines (black arrows) .They possess small dark stained nuclei (pyknosis). (Figure3.b)

In the group received recommended daily dose of vitamin A (O+T+A):-

The solid tumor showed apoptotic changes (black arrows) in most regions (small cells with dark pyknotic nuclei). Numerous regions showed tiny apoptotic bodies and areas of necrosis. Cell foci with swollen unstained cytoplasm and dark small nuclei (necrosis) could be also seen (white arrows). (Figure 3, c)

In the double dose of vitamin A group (O+T+2A):-

This dose showed also potential anti-cancer effect [small apoptotic cells with dark cytoplasm and nuclei (dotted black arrows-foci of necrotic cells(white arrows)]. Through the tumor tissue, foci of active pleomorphic tumor cells with large euchromatic nuclei could be seen (insert, black arrow). (Figure 3, d)

In four dose of vitamin a group (O+T+ 4A):-

Show less potential anti-cancer effect (dotted black arrow). Most cells looked active with pleomorphic euchromatic nuclei (black arrows) similar to those observed in untreated group. (Figure 3, e)

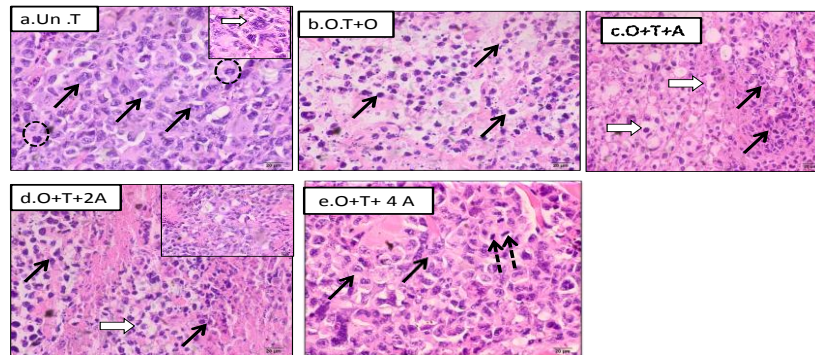


Figure 3:-Sections in the solid tumor stained by H&E and photographed at X600 to show cellular status of .a.untreated tumor b.c.d.e.f. Notice the highly pleomorphic proliferation active cells in non-treated group .Other groups showed various degrees of cell apoptosis (shrunken cells with dark strained pyknotic nuclei).ESPECIAALY in group received olive oil o+t+o and low doses of vitamin A.

a: untreated tumor to show cancer cells with pleomorphic achromatic(active) nuclei with prominent acidophilic nucleoli (black arrows). Some fuse to form giant cells (dotted circles).

b: O +T+O showing marked degeneration of most tumor cells as evidenced by dark staining and decrease nuclear size (pyknosis).

C: O+T+A (Th. dose) showing marked apoptotic changes in most regions of solid tumors (small cells with dark pyknic nuclei (black arrows). Numerous regions showed yiny apoptotic bodies (dotted arrows) and areas of necrosis (star).

d. O+T+A (2 doses); showing potential anti -cancer effect (small apoptotic cells with dark cytoplasm and nuclei) as there still small foci of active cells (large euchromatic nuclei, white arrows).

e. O+T+ A(4 doses) showing less potential anti-cancer effect as most cells looked active with pleomorphic euchromatic nuclei similar to those of untreated tumor

Discussion:-

Dietary supplements such as vitamins and minerals have become widely available to be taken for a variety of reasons. Some people are advised by their doctors or dietitian to take dietary supplements especially if they have certain medical conditions such as pregnancy or those who have a restricted dietary intake. Many people also take vitamins and supplements while they are being treated for cancer; others take them to prevent cancer. Cancer patients are increasingly turning to supplements to strengthen their immune systems and ease nausea from chemotherapy

[15]. Contradictory data regard beneficial versus unwanted potentiating carcinogenic effect of vitamin A. Epidemiological studies have suggested an inverse correlation between cancer development and dietary consumption of vitamin A. Pharmacological concentrations of vitamin A decrease the incidence of chemically induced experimental tumors [16]. Natural and synthetic retinoid have been demonstrated to inhibit the growth and the development of different types of tumors, including skin, breast, oral cavity, lung, hepatic, gastrointestinal, prostatic, and bladder cancers [17-18]. Clinical evidence shows that vitamin A helps to prevent cancer. The role of vitamin supplements in preventing breast cancer still remains unclear. The association of vitamin A and cancer was initially reported in 1926 when rats, fed vitamin A-deficient diet, developed gastric carcinomas. The first investigation showing a relationship between vitamin A and human cancer was performed in 1941 by Abelsetal who found low plasma vitamin A levels in patients with gastrointestinal cancer. [19] Moon et al reported that daily supplemental doses of 25,000 IU of vitamin A prevented squamous cell carcinoma. Studies that use animal models have shown that retinoids (including vitamin A) can act in the promotion-progression phase of carcinogenesis and block the development of invasive carcinoma at several epithelial sites, including the head and neck and lung. [19]. Vitamin A supplementation likely does not reduce chemotherapy efficacy, and for many patients, is unlikely to cause harm. [20].

Vitamin A was advised by clinicians for its antioxidant activity once thought to help preventing or promoting cancer therapy. However, more recent studies showed that high levels of these supplement may increase cases of gastrointestinal cancers, such as stomach, colon, and esophageal, in some populations. [15]

In the present study 3 different doses of Vitamin A were tested for their effect on EAC cells inoculated in mice thigh to develop solid tumors. Recommended dose in literature was reported to be ranged from (900 mcg RAE for male-700 mcg RAE for female). [21] Also double and 4 times of this dose were tested to define if they are safe to be given in case of neoplastic status.

The results of the present study showed that the recommended dose of vitamin A was apparently safe and also potentiate the effect of olive oil as an anti-cancer agent most probably to Polyphenol group [22].

A suicidal cell program to eliminate damaged or cancerous cells known as apoptosis. It is a pathway of cell death induced by activates enzymes that degrade the cell nuclear DNA via activate caspases pathways. In the present study, histological characteristics of cell apoptosis [23] were observed in EAC tumors masses of both olive oil treated animals alone or those given vitamin A after tumor induction, however, in the latter group, some tumor cells appeared swollen and vacuolated as if being entered into necrotic changes. Necrosis is another pathway of cell death

Mainly results from cell membrane damage following lipid peroxidation [24]. Here in the present study, although shrinkage of cells, dark staining of nuclei could point to apoptotic changes but needs to be confirmed by immunohistochemically staining apoptotic markers (caspase 3/P53 specific markers). Investigation is going on for the same samples to determine P53 /P16 using quantitative real time (qRT-PCR) Accord to methodology used by [25].

Conclusion:-

while dietary factors may be crucial in modifying cancer risk, the role of vitamin supplements in preventing cancer still remains unclear. In the present study, recommended doses of Vitamin A seemed to be safe and did not interfere with olive oil suppression of cancer cell proliferation in case of EAC. However high doses must be avoided to protect against any prooxidant effect that may enhance cancer cell proliferation. Further investigations are warranted to elucidate the mechanisms by which vitamin A supplementation may modify cancer development.

References:-

1. Parkin, M., B, L. & Walker, L, (2011). The fraction of cancer attributable to lifestyle and environmental factors in the UK. *British Journal of Cancer*. 105 Suppl 2: S77-81.
2. Ferlay, J., Soerjomataram, I., Ervik, M., Dikshit, R., Eser, S & Mathers, C, (2012). *Cancer Incidence and Mortality Worldwide: IARC Cancer Base No. 11*.
3. Lobo, V., Patil, A., Phatak, A. & Chandra, N., (2010). Free radicals, antioxidants and functional foods: Impact on human health. *Pharmacogn Rev*, 4(8): 118– 126.
4. Vitamin A, (2015). Micronutrient Information Center, Linus Pauling Institute, Oregon State University.
5. Vitamin A, (2016). MedlinePlus, National Library of Medicine, US National Institutes of Health.
6. Vitamin A, (2011). Biomarkers of nutrition for development. *The American Journal of Clinical Nutrition*.
7. Norleena, P., Gullett, A., Ruhul, A., Bayraktar, C., John, M., Pezzuto, D., Dong, B., Fadlo, R., Khuri, B., Bharat, B., Aggarwal, E., Young-Joon, Surh, F. & Omer Kucuk, B., (2010). Cancer prevention with natural compounds. *Seminars in Oncology*, Volume 37, Issue 3, Pages 258-281.
8. Singh, P. P., Chandra, A. N., Farzana, M., Roy, A. & Sharma, P., (2010). Re-convene and Re-connect the Antioxidant Hypothesis in Human Health and Disease. *Indian J Clin Biochem*
9. Sayin, I., Ibrahim, M., Larsson, E., Nilsson, J., Lindahl, P. & Bergo, M., (2014). Antioxidants accelerate lung cancer progression in mice. *Science Translational Medicine* 9;6(221):221ra15.
10. Bergo, M., Lindahl, P. & Campbell, P., (2014). Could antioxidants speed up cancer regression. *American Cancer Society, Science Translational Medicine*.
11. Asuka, Y., Hayato, U. & Toshinori, Ito., (2016). Efficacy and Interaction of Antioxidant Supplements as Adjuvant Therapy in Cancer Treatment. *Integr Cancer Ther*. 15(1): 17–39.
12. Thyagarajan, A. & Sahu, R. P., (2018). Potential Contributions of Antioxidants to Cancer Therapy: Immunomodulation and Radio Sensitization. *Integrative Cancer Therapies*. 17(2): 210–216.
13. Anroop, B. N. & Shery, J., (2016). A simple practice guide for dose conversion between animals and human. *Journal of Basic and Clinical Pharmacy*. 7(2):27- 31.
14. Cyrill, M., Bastian, P., Rieger, A., Rüdiger, W. & Blütke, A., (2018). Practicable methods for histological section thickness measurement in quantitative stereological analyses. www.webmd.com/diet/cancer-guide
15. Niles, R. M., (2004). Signaling pathways in retinoid chemoprevention and Treatment of cancer. *Mutation Research*. 555(1-2):81–96. doi:
16. Arrieta, O., González-De La Rosa, C. H. & Aréchaga-Ocampo, E., (2010). Randomized phase II trial of All-trans-retinoic acid with chemotherapy Based on paclitaxel and cisplatin as first-line treatment in patients with advanced non-small-cell lung cancer. *Journal of Clinical Oncology* 2010; 28(21):3463–3471.
17. Bryan, M., Pulte, E. D. & Toomey, K. C., (2011). A pilot phase II trial of all-Trans-retinoic acid (Vesanoide) and paclitaxel (Taxol) in patients with Recurrent or metastatic breast cancer. *Investigational New Drugs*. 2011; 29(6):1482–1487. www.bccancer.bc.ca/PPI/UnconventionalTherapies/VitaminARetinol.htm
18. Andrea, S. & Blevins, P., (2017). Vitamin A and Cancer. *Cancer Therapy Advisor* www.ods.od.nih.gov/factsheets/VitaminA-HealthProfessional
19. Monika, G. D., Paulina, P., Francesco, C., Alicja, K., J. Antonella, M., G. Narcyz, K., Michal, W. & Magdalena, G., P., (2018). Potential Health Benefits of Olive Oil and Plant Polyphenols. *International Journal of Molecular Sciences*.
20. Areida, K. S., Abdel-azim, A. O. & Amer, M. E., (2015). Protective and curative effect of thymoquinone on Ehrlich solid carcinoma inoculated mice. *The Egyptian Journal of Hospital Medicine*. Vol. 58, page 129-142
21. Ayala, A., Muñoz, M. F. & Argüelles, A., (2014). Lipid Peroxidation: Production, Metabolism, and Signaling Mechanisms of Malondialdehyde and 4-Hydroxy-2-Nonenal. *Oxidative Medicine and Cellular Longevity Journal*.
22. Bassiony, H., Sabet, S., Salah El-Din, T., Mohamed, M. & El-Ghor, A., (2014). Magnetite Nanoparticles Inhibit Tumor Growth and Upregulate the Expression of P53/P16 in Ehrlich Solid Carcinoma Bearing Mice.