



Journal Homepage: [-www.journalijar.com](http://www.journalijar.com)

INTERNATIONAL JOURNAL OF ADVANCED RESEARCH (IJAR)

Article DOI:10.21474/IJAR01/20432
DOI URL: <http://dx.doi.org/10.21474/IJAR01/20432>



RESEARCH ARTICLE

NEUROMENINGEAL TUBERCULOSIS IN INFANTS: A SEVERE PRESENTATION COMPLICATED BY DIFFUSE CEREBRAL ISCHEMIA. A CASE REPORT

I. Jarir, K. El Ouafi, H. Darouiche, K. Elfakhr, W. Aissaoui and S. Kallouche

Pediatric Intensive Care Unit, Abderrahim Harouchi Hospital, Ibn Rochd University Hospital, Casablanca, Morocco.

Manuscript Info

Manuscript History

Received: 14 December 2024

Final Accepted: 17 January 2025

Published: February 2025

Key words:-

Neuromeningeal Tuberculosis, Febrile Encephalopathy, Stroke, Infant

Abstract

Neuromeningeal tuberculosis is a serious complication, particularly in children. We report the case of a 7-month-old Moroccan infant admitted for severe febrile encephalopathy, beginning with high fever, irritability and refusal to eat, rapidly progressing to neurological deterioration. Biological workup revealed hyperleukocytosis, elevated CRP and procalcitonin, and cerebrospinal fluid analysis showed hyperproteinorachia, hypoglycorachia and pleiocytosis, without bacterial isolation. The diagnosis of tuberculosis was confirmed by Xpert® MTB/RIF Ultra on a bronchial swab. Cerebral imaging revealed diffuse ischemic lesions and cerebral involvement, indicating severe vascular complications. Despite intensive intensive care, including anti-tuberculosis treatment and external ventricular bypass, the outcome was fatal. This case highlights the urgent need for early diagnosis and multidisciplinary management.

Copyright, IJAR, 2025., All rights reserved.

Introduction:

Methodology:

This is a retrospective case report conducted in October 2024 at the Pediatric Intensive Care Unit of AbderrahimHarouchi Mother-Child Hospital, Ibn Rochd University Hospital, Casablanca. The study is based on a detailed analysis of the medical records of a 7-month-old infant admitted for severe febrile encephalopathy. The patient presented with high fever, irritability, and refusal to feed, which rapidly evolved into neurological deterioration.

Clinical data were comprehensively collected from the patient's medical records, including medical history, clinical and paraclinical findings, as well as diagnostic and therapeutic interventions performed during hospitalization. This included laboratory results, cerebrospinal fluid analysis, imaging studies, and the confirmation of tuberculosis through Xpert® MTB/RIF Ultra. The patient's clinical course, including complications such as diffuse ischemic brain lesions and the management provided in the Pediatric Intensive Care Unit, was reviewed chronologically to identify factors contributing to the fatal outcome.

Results:

A 7-month-old Moroccan infant, born at term, with an up-to-date vaccination schedule and no notable medical or family history, was admitted for progressive febrile encephalopathy. Eight days prior to admission, the child presented with an isolated fever of 39.5°C, associated with irritability and refusal to eat. The neurological state deteriorated over time, with decreased alertness (GCS 13/15), axial hypotonia and signs of respiratory struggle.

Corresponding Author: I. Jarir

Address:-Pediatric Intensive Care Unit, Abderrahim Harouchi Hospital, Ibn Rochd University Hospital, Casablanca, Morocco.

On admission, the clinical examination revealed an altered general condition. Neurological examination revealed generalized hypotonia with no focal signs. Respiratory examination revealed bilateral crepitus rales, respiratory rate 50/min, and oxygen saturation 92% on room air. The child was afebrile at 39.5°C, with stable hemodynamic parameters and a normal dextro.

Biological workup revealed hyperleukocytosis at 16,000/mm³, with a predominance of neutrophils (80%), very high CRP at 215 mg/L and procalcitonin at 10 ng/mL. Cerebrospinal fluid (CSF) analysis, macroscopically cloudy, showed hyperproteinorachia at 0.98 g/L, hypoglycorachia at 0.03 g/L (associated glycemia at 0.84 g/L) and marked pleocytosis with 3,800 elements/mm³ predominantly neutrophils. These findings were consistent with severe bacterial meningitis, although CSF cultures were negative, probably due to prior antibiotic treatment.

Molecular diagnosis using the Xpert MTB/RIF Ultra test on a bronchial swab detected *Mycobacterium tuberculosis* without rifampicin resistance, confirming susceptible tuberculosis.

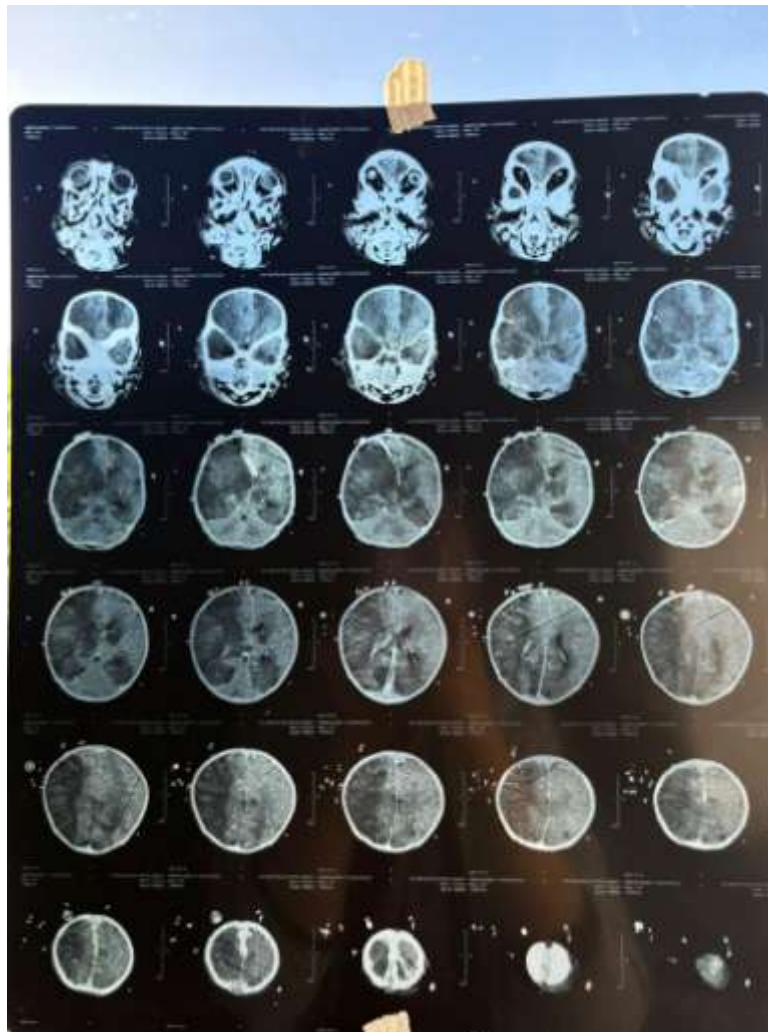


Figure 1: Initial brain scan showing diffuse cortico-subcortical damage, diffuse arterial ischemic lesions secondary to probable vasculitis, bilateral temporal involvement and hemorrhagic infarction complicated by ventricular flooding.

The child was taken into intensive care with intubation and mechanical ventilation. Empirical antibiotic therapy with cefotaxime, amikacin and vancomycin was initiated before molecular test results were available. After confirmation of tuberculosis, specific anti-tuberculosis treatment was rapidly initiated. An external ventricular bypass (EVB) was

inserted, allowing drainage of 100 to 200 cc per day. Management also included anti-oedematous measures, including sedation and mannitol administration to limit cerebral involvement.

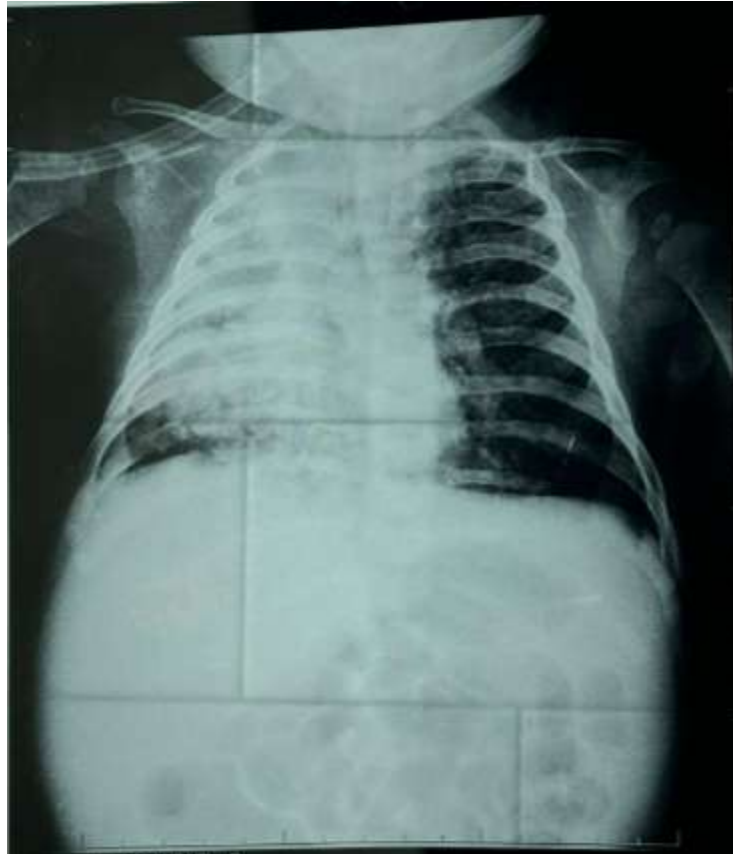

Figure 2:Frontal chest X-ray showing a “white lung” suggestive of massive alveolar syndrome.

On day 5 of hospitalization, the child developed right anisocoria, reflecting neurological worsening through progression of cerebral involvement. Computed tomography (CT) monitoring showed extension of ischemic lesions, collapsed basal cisterns, ventricular flooding and progression of cerebral involvement. Despite therapeutic adjustments and intensive care, the evolution was marked by multivisceral failure leading to death.

Discussion:

Tuberculous meningitis is a severe form of extrapulmonary tuberculosis, particularly in children, with significant mortality and neurological morbidity [1]. Initial clinical signs are often nonspecific, including fever, irritability and eating disorders, as observed in our patient [2,3]. Progression to altered consciousness and the appearance of neurological signs suggest advanced meningeal involvement [1]. Biological examinations revealed marked systemic inflammation, with hyperleukocytosis and significant elevation of CRP and procalcitonin [4]. Cerebrospinal fluid (CSF) analysis showed features typical of tuberculous meningitis - hyperproteinorachia, hypoglycorachia and predominantly neutrophilic pleiocytosis - although culture negativity, possibly related to prior antibiotic therapy, illustrates the difficulties of microbiological diagnosis in this setting [4]. The use of rapid molecular tests, such as Xpert® MTB/RIF Ultra, enabled the detection of *Mycobacterium tuberculosis* and confirmed the diagnosis [2,5]. The initial brain scan revealed diffuse ischemic lesions, bilateral temporal involvement and hemorrhagic infarction with ventricular flooding, complications frequently observed in meningitis. Advanced tuberculous meningitis, linked to vasculitis and occlusion of cerebral vessels [6]. Cerebral involvement, confirmed by anisocoria and worsening lesions on imaging, is a poor prognostic sign [6]. Intensive care management, including intubation, mechanical ventilation and external ventricular bypass, was aimed at controlling intracranial hypertension and stabilizing neurological status [1]. Initial empirical antibiotic therapy, subsequently adapted to specific anti-tuberculosis treatment after molecular confirmation, followed current recommendations [3,7]. However, despite intensive management, the unfavorable evolution towards multivisceral failure testifies to the severity of tuberculous

meningitis in infants [1]. This case illustrates the challenges posed by tuberculous meningitis in young children, notably the often delayed diagnosis due to the non-specific clinical presentation and difficulties in isolating *Mycobacterium tuberculosis* [4]. The use of rapid molecular tests improves early detection and appropriate management of the disease, although rapid progression to severe neurological complications, such as brain involvement, further complicates the prognosis [2,5,6].

Conclusion:

Tuberculous meningitis in infants represents a medical emergency requiring rapid recognition and intervention. This case demonstrates the importance of increased clinical vigilance, the use of advanced diagnostic techniques and multidisciplinary management to improve outcomes in this vulnerable population.

References:

1. du Preez K, Jenkins HE, Donald PR, Solomons RS, Graham SM, Schaaf HS, Starke JR, Hesselning AC, Seddon JA. Tuberculous Meningitis in Children: A Forgotten Public Health Emergency. *Front Neurol*. 2022 Mar 17;13:751133. doi: 10.3389/fneur.2022.751133. PMID: 35370901.
2. Pradhan NN, Paradkar MS, Kagal A, Valvi C, Kinikar A, Khwaja S, Dhage R, Chandane J, Ithape M, Bendre M, Madewar R, Nadgeri V, Nijampurkar A, Jain D, Gupte N, Gupta A, Mave V, Dooley KE, Thakur KT. Performance of Xpert® MTB/RIF and Xpert® Ultra for the diagnosis of tuberculous meningitis in children. *Int J Tuberc Lung Dis*. 2022 Apr 1;26(4):317-325. doi: 10.5588/ijtld.21.0388. PMID: 35351236.
3. Hernandez AV, de Laurentis L, Souza I, Pessanha M, Thota P, Roman YM, Barboza-Meca J, Boulware DR, Vidal JE. Diagnostic accuracy of Xpert MTB/RIF for tuberculous meningitis: systematic review and meta-analysis. *Trop Med Int Health*. 2021 Feb;26(2):122-132. doi: 10.1111/tmi.13525. PMID: 33164243.
4. Garg RK. Microbiological diagnosis of tuberculous meningitis: Phenotype to genotype. *Indian J Med Res*. 2019 Nov;150(5):448-457. doi: 10.4103/ijmr.IJMR_1145_19. PMID: 31939388.
5. Sharma K, Sharma M, Shree R, Modi M, Goyal M, Narang D, Sharma A, Lal V, Sharma N, Ray P. Xpert MTB/RIF Ultra for the diagnosis of tuberculous meningitis: A diagnostic accuracy study from India. *Tuberculosis*. 2020 Dec;125:101990. doi: 10.1016/j.tube.2020.101990. PMID: 32920283.
6. Cresswell FV, Tugume L, Bahr NC, Kwizera R, Bangdiwala AS, Musubire AK, Rutakingirwa M, Kagimu E, Nuwagira E, Mpoza E, Rhein J, Williams DA, Muzoora C, Grint D, Elliott AM, Meya DB, Boulware DR. Xpert MTB/RIF Ultra for the diagnosis of HIV-associated tuberculous meningitis: a prospective validation study. *Lancet Infect Dis*. 2020 Mar;20(3):308-317. doi: 10.1016/S1473-3099(19)30550-X. PMID: 31924549.
7. Kohli M, Schiller I, Dendukuri N, Dheda K, Denkinger CM, Schumacher SG, Steingart KR. Xpert® MTB/RIF assay for extrapulmonary tuberculosis and rifampicin resistance. *Cochrane Database Syst Rev*. 2018 Aug 27;8(8):CD012768. doi: 10.1002/14651858.CD012768.pub2. PMID: 30148542.