



Journal Homepage: - www.journalijar.com

INTERNATIONAL JOURNAL OF ADVANCED RESEARCH (IJAR)

Article DOI: 10.21474/IJAR01/20273

DOI URL: <http://dx.doi.org/10.21474/IJAR01/20273>



RESEARCH ARTICLE

EFFECTIVENESS OF NON-SURGICAL MANAGEMENT OF CONGENITAL NASOLACRIMAL DUCT OBSTRUCTION

Santosh Verma, Ajab Dhabarde, Rashmi Verma and Soorya Kumar

Manuscript Info

Manuscript History

Received: 18 November 2024

Final Accepted: 21 December 2024

Published: January 2025

Key words:-

Congenital Nasolacrimal Duct
Obstruction, Epiphora, Hydrostatic Sac
Massage

Abstract

Background: Congenital nasolacrimal duct obstruction is the common disorder leading to epiphora and is usually due to the failure of canalization of nasolacrimal duct. Canalization of the nasolacrimal duct usually occurs by six months of intrauterine life. Common causes of nasolacrimal duct obstruction include the absence or atresia of the canaliculi and puncta, congenital atresia of the duct, the presence of a membrane at the valve of Hasner, absence of valves, lacrimal sac mucocele, blockages, and craniofacial abnormalities.

Methods: The study included 100 babies (108 eyes) under the age of 2 diagnosed with congenital nasolacrimal duct obstruction. Hydrostatic sac massage was performed weekly by the clinician and proper technique was explained to the parents for massaging at home. All babies were followed weekly for 6 months. Successful hydrostatic sac massage was documented when complete resolution of symptoms occurred.

Results: The most common sign of congenital nasolacrimal duct obstruction was mucopurulent discharge (62.96%) followed by epiphora (31.48%), mucocele (3.70%) and lacrimal abscess (1.85%). The overall effectiveness of hydrostatic sac massage in babies below 2 years of age was 80.55% and it was most effective in 6-12 months age group (88.23%). The success rate decreases as age increases.

Conclusion: Hydrostatic sac massage of the nasolacrimal duct is a safe and effective primary treatment option for congenital nasolacrimal duct obstruction in babies under 2 years of age. Results of the study may encourage us to proceed for early non-surgical intervention of CNLDO by hydrostatic nasolacrimal sac massage rather than waiting for spontaneous resolution.

Copyright, IJAR, 2025., All rights reserved.

Introduction:-

Epiphora is the abnormal overflow of tears caused by either excessive tear production or obstruction in the lacrimal drainage system¹. Congenital nasolacrimal duct obstruction (CNLDO) is the most common cause of epiphora, typically resulting from a failure in the canalization of the distal end of the duct^{2,3}. The canalization of the nasolacrimal duct (NLD) typically occurs by the end of the sixth month of intrauterine life, but it can be delayed for several weeks or even months after birth.^{2, 3}. Various other factors as abnormalities within the nasal passage, complete osseous obstruction etc may also result in obstruction of the nasolacrimal duct⁴. CNLDO is a common disorder that affects about 20% of all newborns. It is observed that about 30% of full term infants have nasolacrimal

duct obstruction at birth, out of which only 2 to 4% present with symptoms⁵. The majority of cases (96%) usually resolves and become asymptomatic by the age of 1 year^{5,6}. Few cases of nasolacrimal duct obstruction (NLDO) may present delayed due to failure of early recognition as tears are normally produced a few weeks after birth⁷. Various causes of CNLDO are atresia or absence of canaliculi and puncta, mucocele of lacrimal sac, atonic lacrimal sac, presence of membrane at the valve of Hasner, malformed valves, congenital atresia of NLD, clogging, craniofacial disorders etc^{6,7}. There are many controversies regarding the natural course and management of CNLDO. In general, spontaneous resolution is often expected⁴. Crigler described a technique involving the application of pressure in a specific manner over the nasolacrimal sac area, followed by the use of topical antibiotics if an active infection is present⁸.

Various studies had reported success rate of CNLDO resolution without surgery from 32% to 95% by 13 months of age^{8,9}. It has been reported that approximately 90% of infants respond to nasolacrimal duct massage during the first year of life, while 60% respond in their second year^{9,10,11}. The purpose of the present study was to evaluate the effectiveness of Hydrostatic Lacrimal Sac Massage in CNLDO in various age groups below 2 years of age.

Material and Methods:-

This prospective interventional study was conducted at a tertiary care rural hospital in Central India from January 2017 to April 2019. A total of 100 babies (108 eyes) under the age of 2, diagnosed with CNLDO, were included after obtaining informed written consent from their parents and approval from the institutional ethics committee. The babies were categorized into four age groups: Group 1: infants under 6 months, Group 2: infants between 6 to 12 months, Group 3: toddlers between 12 to 18 months, and Group 4: older toddlers between 18 to 24 months.

Inclusion Criteria:

1. Babies below 2 years of age diagnosed as CNLDO (unilateral/bilateral).
2. Babies below 2 years of age with previous diagnosis of CNLDO and failed conservative treatment.
3. Babies below 2 years of age with congenital dacryocoele that did not resolve within a few weeks.
4. Babies below 2 years of age with copious mucopurulent discharge.

Exclusion Criteria:

1. Babies with acute dacryocystitis.
2. Any secondary cause of watering eye as blepharitis, congenital glaucoma, conjunctivitis.
3. Ocular abnormalities as punctal stenosis, agenesis, ectopic puncta, congenital ectropion.
4. Any congenital craniofacial anomalies as Goldenhar's syndrome, Crouzon's syndrome or Treacher-Collins syndrome.
5. Any nasal disorder or history of nasal or sinus surgery or exposure of radiation to the nasal area.

The diagnosis of CNLDO is determined by a history of watering or discharge from one or both eyes within the first few weeks of life.. Other symptoms such as crusting, mucopurulent discharge, stickiness of lids and redness may be associated. Parents may give history of stickiness of lashes in morning or after the child takes a nap. The tear meniscus may be high in the eye with CNLDO¹².

The diagnosis of CNLDO was confirmed by gently pressing over the nasolacrimal sac and observing fluid reflux from the punctum¹³. In uncertain cases, a dye disappearance test¹³ was performed. After instilling a topical anesthetic, a drop of 2% fluorescein dye was placed in the inferior fornix, and the tear film was examined using the cobalt blue light of a slit lamp biomicroscope or a direct ophthalmoscope in uncooperative infants^{14,15}. A delay in dye clearance beyond five minutes indicated an outflow obstruction of the lacrimal apparatus. Other causes of watery eyes, such as congenital glaucoma, lid abnormalities (ectropion, entropion, epiblepharon), lash abnormalities (trichiasis, distichiasis), corneal surface disorders, conjunctivitis, and keratitis¹⁶, were carefully ruled out. A history of photophobia alongside watery eyes suggested the possibility of congenital glaucoma or ocular surface disease. The puncta were inspected for stenosis, while corneal transparency was assessed, and corneal diameter was measured to exclude buphthalmos.

All the babies with CNLDO included in the study, received conservative non-surgical management of CNLDO as proper Hydrostatic Nasolacrimal Sac Massage weekly by a clinician. In addition, parents were instructed to perform hydrostatic nasolacrimal sac massage 4 times per day (each time 10 strokes of massage) at home along with instillation of topical antibiotic drops whenever a mucopurulent discharge was present. This conservative medical

management was continued for 6 months in all the babies and discontinued only if there was complete resolution of symptom (epiphora).

Proper technique of Hydrostatic Lacrimal Sac Massage^{8,9}: Crigler was the first to describe lacrimal sac massage. After trimming nails and washing hands, upper and lower puncta were blocked with thumb and index finger of one hand then with index finger of other hand sac massage was given firmly in such a manner that fluid collected into the sac did not escape through puncta and was forced downward along the direction of NLD so that pressure created by the flow of fluid could open the blocked NLD by rupturing any obstruction due to membrane formation or clogging (**Photo 1**). Following this procedure, topical antibiotic drops were instilled. Parents were advised to bring their babies for follow up every week for 6 months. The effectiveness of hydrostatic sac massage was confirmed by the complete cessation of tearing and discharge, along with the absence of reflux from the puncta upon applying pressure to the lacrimal sac.

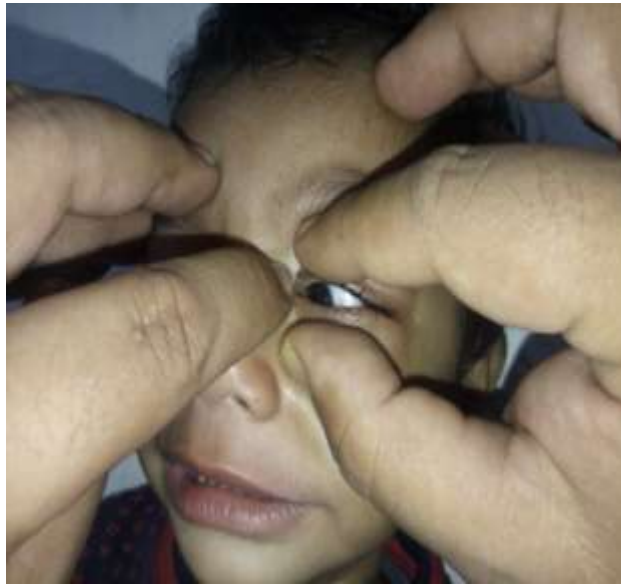

Photo 1:- Technique of effective lacrimal sac massage (Upper and lower punctum blocked and downward massage with index finger).

Results:-

Age-wise distribution: The study included 100 babies (108 eyes), comprising 37 males and 63 females (see **Figure 1**). These included 38 infants below 6 months of age, 32 infants between 6-12 months, 22 toddlers between 12-18 months and 8 older toddlers between 18-24 months of age (**Table 1**).

Table 1:- Age wise distribution of babies and eyes.

Group	Age	No. of babies	No. of eyes
1	Below 6 months	38(38%)	44(40.74%)
2	6-12 months	32(32%)	34(31.48%)
3	12-18 months	22(22%)	22(20.37%)
4	18-24months	8(8%)	8(7.41%)
		100(100%)	108(100%)

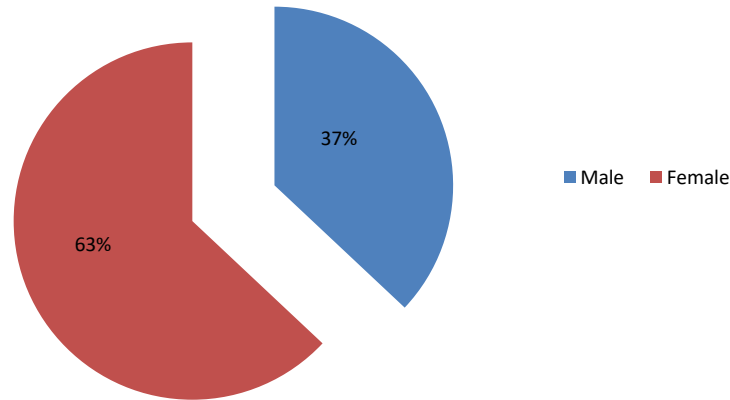


Figure 1: Gender-wise distribution of babies.

Maturity at birth and mode of delivery wise distribution: A pre-term birth is one that occurs before the start of the 37th week of pregnancy¹⁷. Out of total 100 babies, 14 were delivered pre-term and 86 were delivered at full term of pregnancy. Out of total 100 babies, 48 were delivered by LSCS and 52 were delivered by NVD (**Table 2**).

Table 2:- Maturity at birth and mode of delivery wise distribution.

Term	Mode of delivery	No. of babies (%)	Total
Pre-term	LSCS	12	14
	NVD	02	
Full-term	LSCS	36	86
	NVD	50	
Total		100	100

Onset of symptoms wise distribution:

Among 100 babies, symptoms began before four weeks of age in 18 cases, while the remaining 82 developed symptoms after four weeks.

Laterality wise distribution:

Unilateral obstruction was observed in 92 babies, while bilateral obstruction was present in 8, accounting for a total of 108 affected eyes.

Signs of CNLDO:

The most common sign was mucopurulent discharge in 62.96% (68 eyes). The next common signs were epiphora in 31.48% (34 eyes), mucocele in 3.70% (4 eyes) and lacrimal abscess in 1.85% (02 eyes). There was regurgitation of mucopurulent or watery fluid on pressure over the lacrimal sac in 102 babies, 4 babies had mucocele and 02 babies had lacrimal abscess with no regurgitation (**Figure 2**).

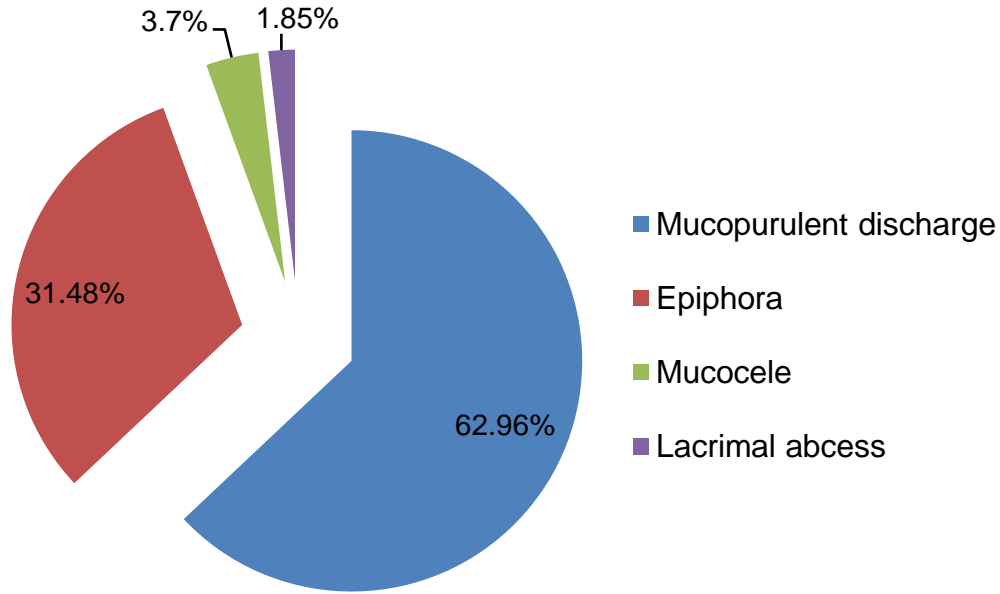


Figure 2: Signs of CNLDO

Effectiveness of non-surgical management in CNLDO:

Effectiveness of non-surgical management (Hydrostatic nasolacrimal sac massage) in CNLDO among babies below 6 months of age was 81.82% (36 eyes), in 6-12 months age group it was 88.23% (30 eyes), in 12-18 months age group it was 72.73% (16 eyes) and in 18-24 months age group it was 62.50% (5 eyes) (Figure 3).

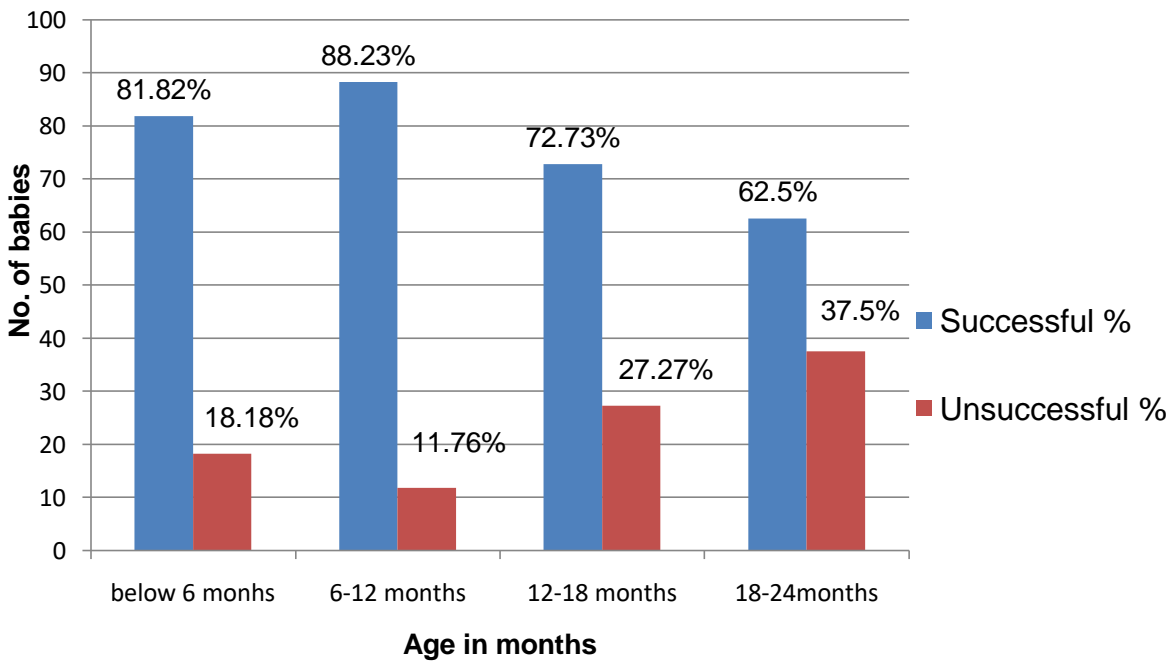


Figure 3:- Effectiveness of non-surgical management in CNLDO:

The overall effectiveness of hydrostatic sac massage in babies below 2 years of age was 80.55% (87 eyes) (Figure 4). ($p < 0.05$, Chi square test). $p = 0.007$ for comparison of success rate among the age groups.

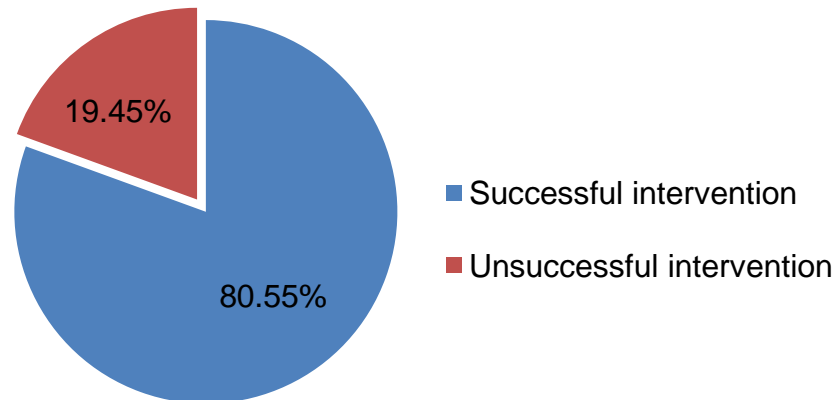


Figure 4: Overall Effectiveness of non-surgical management in CNLDO:

Discussion:-

The present study was to assess the effectiveness of non-surgical management (Hydrostatic Lacrimal Sac Massage) in infants with congenital nasolacrimal duct obstruction below 2 years of age. It was found that hydrostatic lacrimal sac massage and use of topical antibiotics was the most effective in the age group of 6-12 months. At six months of conservative management, parents reported that 30 eyes (88.23%) were asymptomatic. Various studies¹⁹⁻²³ in the literature have shown similar rates of NLDO resolution with non-surgical treatment. In a prospective study of infants up to six months old, Paul¹⁶ reported that 70% of eyes (26 out of 37) resolved with conservative management by 12 months of age. The findings of the present study—88.23% (95% CI)—obtained from a comparatively larger sample size, are consistent with these results.

Baseline characteristics, including age, sex, laterality, age at symptom onset, specific signs of NLDO, and history of prior treatment, were not found to be associated with NLDO resolution without surgery. About 12% eyes in which non-surgical management was not successful were re-assessed after 6 months and planned for surgical intervention after confirming the diagnosis by Dacryocystography (DCG).

The strengths of this study include its prospective design and a standardized follow-up period. It is also possible that our resolution rate may have been relatively high as we emphasized on Crigler hydrostatic lacrimal sac massage method⁸ very intensively and specifically demonstrated to parents which they followed at home and on weekly basis massage was given by the clinician. But without a control group, it is not possible to determine that to what extent resolution was related to the lacrimal massage, antibiotics use or simply the spontaneous resolution on passage of time.

In a study conducted by Ballard including infants reported that tearing and discharge appears at 2 weeks of age in about 20% of the cases² which is consistent with the present study, where 18% of cases had onset of symptoms before 4 weeks of birth and 82% had symptoms after 4 weeks of age. Lacrimal sac inflammation within a week of birth can cause epiphora and results reflex tearing mimicking CNLDO. This may be reason of 188 out of 443 cases (42.43%) developing symptoms during one week after birth in the study conducted by Ffookes²⁴.

Conclusion:-

Knowing that about 88% the CNLDO cases in infants below 2 years of age will resolve within 6 months with non-surgical management is an important component in decision making for clinicians to plan early or deferred surgical management and help parents more effectively to discuss treatment options. Our results may encourage one to proceed for early non-surgical intervention of CNLDO by intensive hydrostatic sac massage rather than waiting for spontaneous resolution. Hydrostatic sac massage may be considered as a standard therapy for the management of CNLDO. However, effectiveness of Hydrostatic sac massage depends on its proper technique, frequency and early intervention after onset of CNLDO.

Scope of Further Study:-

Nasal endoscopy is recommended in all the cases of CNLDO for better visualization of the blockage in the form of stenosis, atresia, inferior turbinate position, direct observation of fluorescein dye outflow and localization of site of obstruction. Based on findings of nasal endoscopy, conservative or surgical management should be planned. Further study including a control group may again refine the results.

Recommendation:-

Therapeutic hydrostatic nasolacrimal sac massage should be utilized for all the infants who suffer from NLDO. Further, a training program regarding therapeutic hydrostatic nasolacrimal sac massage should be designed for the clinicians, pediatric nurses and infant's caregivers.

Conflicts of Interest:

None.

References:-

1. MacEwen CJ, Young JD. Epiphora during the first year of life. *Eye (Lond)* 2001;5:596-600.
2. Ballard EA. Excessive tearing in infancy and early childhood. The role and treatment of congenital nasolacrimal duct obstruction. *Postgrad Med* 2000;107:149-154.
3. Snell RS. *Clinical anatomy by regions*. 8th ed. Philadelphia: Lippincott Williams & Wilkins; 2008.
4. Karti O, Karahan E, Acan D, Kusbeci T. The natural process of congenital nasolacrimal duct obstruction and effect of lacrimal sac massage. *The International Journal of Clinical Ophthalmology and Visual Sciences* (2016).
5. Tan AD, Rubin PAD, Sutula FC, Remulla HD. Congenital nasolacrimal duct obstruction. *Int Ophthalmol Clin*. 2001 Fall;41(4):57-69.
6. Kushner BJ. Congenital nasolacrimal system obstruction. *Arch Ophthalmol* 1982;100:597-600.
7. Noda S, Hayasaka S, Setogawa T. Congenital nasolacrimal duct obstruction in Japanese infants: its incidence and treatment with massage. *J Pediatr Ophthalmol Strabismus*. 1991;28(1):20-22PubMed.
8. Crigler LW. The treatment of congenital dacryocystitis. *JAMA* 1923,81:23-24.
9. Shivpuri.D, Puri A. Congenital nasolacrimal duct obstruction: The proper technique of massage. *Indian Pediatrics*. Volume 31March 1994:337-40.
10. Nelson LR, Calhoun JH, Menduke H. Medical management of congenital nasolacrimal duct obstruction. *Ophthalmology* 1985;92:1187-90.
11. American Association for Pediatric Ophthalmology and strabismus Nasolacrimal Duct Obstruction. Retrieved at 4 October 2015. [PubMed]. American Association for Pediatric Ophthalmology.
12. Peterson RA, Robb RM. The natural course of congenital obstruction of the nasolacrimal duct. *J Pediatr Ophthalmol Strabismus* 2000;15:246-50.
13. Jones LT, Wobig JL. *Surgery of the eyelids and lacrimal system*. 1st ed. Birmingham: Aesculapius Publishing Co;1976.
14. Busse H, Muller KM, Kroll P. Radiological and histological findings of the nasolacrimal passage of newborns. *Arch Ophthalmol* 1980;98:528-532.
15. Kersten RC. Congenital lacrimal abnormalities. In: Bosniak S (ed). *Principles and practice of ophthalmic plastic and reconstructive surgery*, Vol 2. 1st ed. Philadelphia: W.B. Saunders; 1995:731-747.
16. Paul TO. Medical management of congenital nasolacrimal duct obstruction. *J Pediatr Ophthalmol Strabismus* 2009;22:68-70.
17. Eric AB, Yassir A, Geoffrey ER. Pediatric dacryocystorhinostomy for nasolacrimal duct obstruction *Ophthalmology* 2013; 108:1562-1564.
18. Ghuman T, Gonzales C, Mazow ML. Treatment of congenital nasolacrimal duct obstruction. *Am Orthopt J*. 1999; 49:163-168.
19. Omayma M, Okby, Jaklein R, Younis. Therapeutic hydrostatic nasolacrimal massage vs routine hospital massage: Effect on Infants with congenital nasolacrimal duct obstruction. *Journal of Nursing and Health Science* Nov-Dec. 2016;5(6)40-48.
20. Pediatric Eye Disease Investigator Group. A randomized trial comparing the cost-effectiveness of 2 approaches for treating unilateral nasolacrimal duct obstruction. *Arch Ophthalmol* 2012; 130:1525-33.
21. Stolovitch C, Michaeli A. Hydrostatic pressure as an office procedure for congenital nasolacrimal duct obstruction. *JAAPOS* 2006;10: 269-272.

22. Bageja S, Grover AK, Bansal M. Congenital nasolacrimal duct obstruction. DOS Times Apr 2007;12(10).
23. Panwar N, Sharma V, Kumari K. Role of office sac massage for congenital nasolacrimal duct obstruction in various age-groups. International Journal of Ocular Oncology and Oculoplasty April-June, 2016;2(2):106-108.
24. Ffooks OO. Dacryocystitis in infancy. Br J Ophthalmol, 1962; 46:422-434.