



Journal Homepage: - [www.journalijar.com](http://www.journalijar.com)

## INTERNATIONAL JOURNAL OF ADVANCED RESEARCH (IJAR)

Article DOI: 10.21474/IJAR01/19903

DOI URL: <http://dx.doi.org/10.21474/IJAR01/19903>



### RESEARCH ARTICLE

#### NEOADJUVANT CHEMOTHERAPY FOLLOWED BY CONCURRENT CHEMORADIOTHERAPY FOR LOCOREGIONALLY ADVANCED NASOPHARYNGEAL CARCINOMA: THE NATIONAL INSTITUTE OF ONCOLOGY'S EXPERIENCE, RABAT, MOROCCO

Sara Abdou<sup>1,2</sup>, Mouna Taouchikht<sup>1,2</sup>, Houda Fares<sup>1,2</sup>, Imane Hassnaoui<sup>1,2</sup>, Edith Tatiana Ngbwa<sup>1,2</sup>, Karima Nouni<sup>1,2</sup>, Amine Lachgar<sup>1,2</sup>, Hanan Elkacemi<sup>1,2</sup>, Tayeb Kibdani<sup>1,2</sup> and Khalid Hassouni<sup>1,2</sup>

1. National Oncology Institute, Radiotherapy, Rabat, Morocco.
2. Faculty of Medicine and Pharmacy, Medicine, Rabat, Morocco.

#### Manuscript Info

##### Manuscript History

Received: 11 September 2024

Final Accepted: 21 October 2024

Published: November 2024

#### Abstract

**Purpose/Objective:** Neoadjuvant chemotherapy followed by concurrent chemoradiotherapy (NAC-CCRT) is a standard strategy for decreasing tumor size and controlling micrometastases before main treatment for patients with locally advanced nasopharyngeal carcinoma. The aim of our study is to determine the recurrence free survival and overall survival, and to investigate the occurrence of radiotherapy-induced mucositis and radiodermatitis in patients with nasopharyngeal carcinoma, as well as to identify factors influencing mucositis severity and patient outcomes.

**Material/Methods:** A retrospective analysis was conducted on nasopharyngeal cancer patients treated with VMAT (Volumetric Modulated Arc Therapy) at the Institute of Oncology RABAT between January 2018 and December 2021. Treatment included radiotherapy with or without concurrent systemic therapy. Our study focused on non metastatic patients with locoregionally advanced nasopharyngeal carcinoma: T3-T4 with positive nodes. Treated by induction chemotherapy and concurrent chemoradiotherapy. For the induction chemotherapy, patients received cisplatin associated to gemcitabine for three cycles. In concurrent chemoradiotherapy, total dose was 69,96-70 Gray in 33-35 fractions 5 days a week using Volumetric Modulated Arc Therapy (VMAT) plus cisplatin weekly at a dose of 40 mg per square meter of body surface. Treatment, side effects, loco-regional and distant control and overall survival were collected. Toxicities were defined according to the common terminology criteria for adverse events (CTCAE) version 5.0. Patients were under weekly surveillance.

Copyright, IJAR, 2024.. All rights reserved.

#### Introduction:-

##### Purpose/Objective:-

Neoadjuvant chemotherapy followed by concurrent chemoradiotherapy (NAC-CCRT) is a standard strategy for decreasing tumor size and controlling micrometastases before main treatment for patients with locally advanced nasopharyngeal carcinoma. The aim of our study is to determine the recurrence free survival and overall survival,

**Corresponding Author:- Sara Abdou**

Address:- National Oncology Institute, Radiotherapy, Rabat, Morocco.

and to investigate the occurrence of radiotherapy-induced mucositis and radiodermatitis in patients with nasopharyngeal carcinoma, as well as to identify factors influencing mucositis severity and patient outcomes.

**Material/Methods:-**

A retrospective analysis was conducted on nasopharyngeal cancer patients treated with VMAT (Volumetric Modulated Arc Therapy) at the Institute of Oncology RABAT between January 2018 and December 2021. Treatment included radiotherapy with or without concurrent systemic therapy. Our study focused on non metastatic patients with locoregionally advanced nasopharyngeal carcinoma: T3-T4 with positive nodes. Treated by induction chemotherapy and concurrent chemoradiotherapy . For the induction chemotherapy, patients received cisplatin associated to gemcitabine for three cycles. In concurrent chemoradiotherapy, total dose was 69,96-70 Gray in 33-35 fractions 5 days a week using Volumetric Modulated Arc Therapy (VMAT) plus cisplatin weekly at a dose of 40 mg per square meter of body surface. Treatment, side effects, loco-regional and distant control and overall survival were collected. Toxicities were defined according to the common terminology criteria for adverse events ( CTCAE) version 5.0. Patients were under weekly surveillance.

**Results:-**

257 patients were included in the study, comprising 21% elderly and 79% young individuals, with no significant differences in AJCC stage 8th edition distribution.

We had 61,4% of men vs 38,6% of women and comorbidities were present in 15% of cases.

Undifferentiated nasopharyngeal carcinoma (UCNT) accounted for 87% of histological types.

Tumor staging revealed T1 in 11%, T2 in 33%, T3 in 24%, and T4 in 32% of cases.

Lymph node involvement was classified as N0 in 15%, N1 in 38%, N2 in 37%, and N3 in 10% of patients.

Treatment modalities included neoadjuvant chemotherapy followed by concurrent chemoradiotherapy using cisplatin associated to gemcitabine for three cycles in 86% of patients and concurrent chemoradiotherapy alone in 14%.

Radiotherapy was administered using VMAT technique, delivering a total dose 69, 96-70 Gray in 33-35 fractions 5 days a week using Volumetric Modulated Arc Therapy (VMAT), concurrently with weekly cisplatin (40mg/m<sup>2</sup>/week).

Acute toxicities reported in 42% of patients, with higher incidences of radiomucositis Grade 2 and 3 observed in N3 lymph node status (20%) and in patients with larger GTV size (25%).

Late toxicities included grade 1-2 xerostomia in 45% of patients and grade 1 skin fibrosis in 15%.

Oral and esophageal mucositis resulted in pain, dysphagia, and weight loss, with 33% of patients losing more than 8 kg, 56% losing between 3 and 8 kg, and only 11% losing less than 3 kg. 3% of patients failing to complete the prescribed radiotherapy course, regardless of age group.

At a median follow-up of 48 months, the 2-year recurrence-free survival was 73, 2%, and the Overall survival at 2 years was 89.4%, while recurrence and metastatic progression rates were 11% and 4%, respectively. Cancer-related mortality accounted for 6% of cases, and 4% were lost to follow-up.

**Discussion:-**

Nasopharyngeal cancer (NPC) is a specific type of cancer of the upper aerodigestive tract.

In epidemiological terms, nasopharyngeal cancer is distinguished from other cancers of the ENT sphere by its geographical distribution (high-risk zone, intermediate-risk zone and low-risk zone). Morocco belongs to the intermediate-risk zone [1].

Nasopharyngeal carcinoma is a frequent cancer in Morocco, with an incidence of 2.1/100,000 inhabitants according to the Rabat register. It is the 5th most common cancer at INO and accounts for 10% of the activity of the external radiotherapy department.

This cancer generally affects people over the age of 50, although a first peak between the ages of 20 and 30 is found in the Maghreb, with a radio sex ratio of 2 men to 1 woman.

In our study we had 61,4% of men vs 38,6% of women and comorbidities were present in 15% of cases.

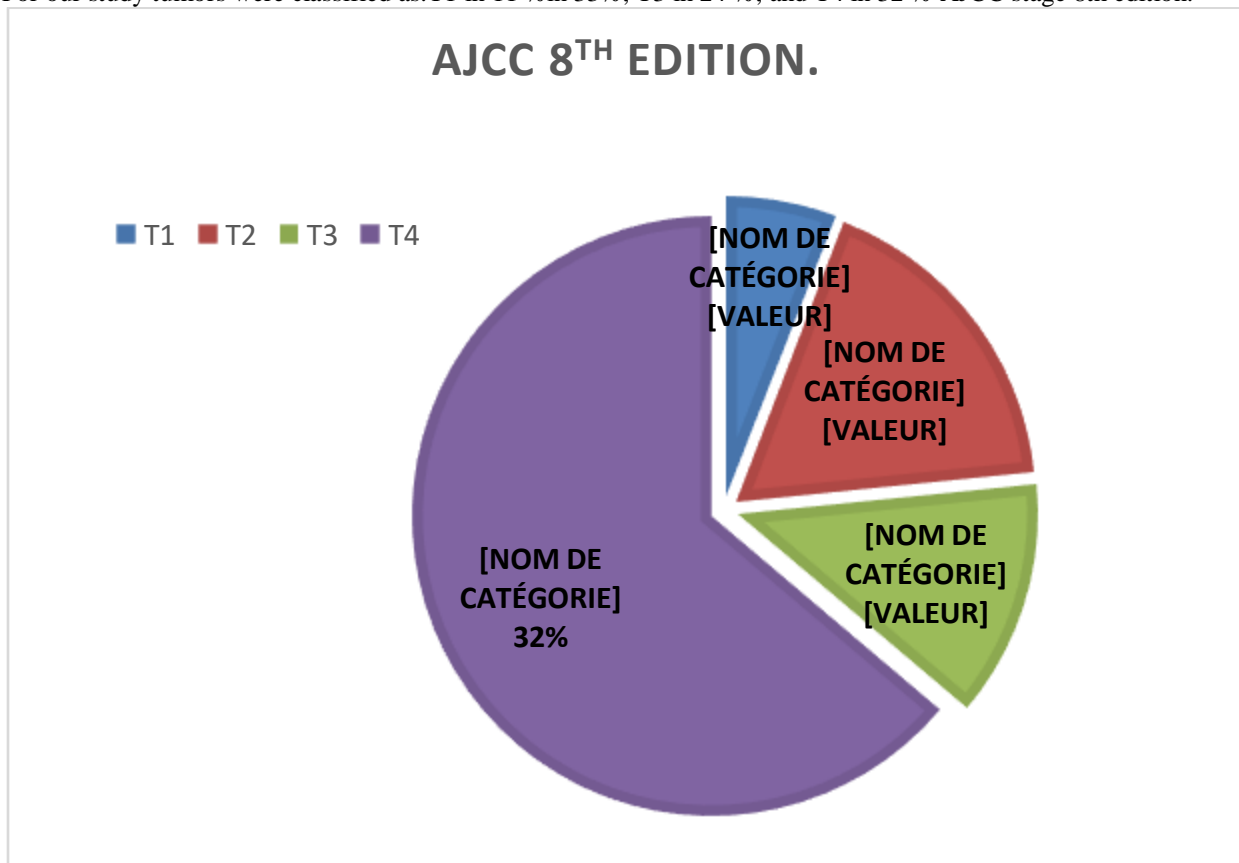
Epithelial tumors of the nasopharynx have been classified by the World Health Organization based on the degree of differentiation of malignant cells (WHO, 2003):

- Type I: differentiated keratinizing squamous cell carcinoma.
- Type II: non-keratinizing differentiated squamous cell carcinoma.
- Type III: Undifferentiated Carcinoma of Nasopharyngeal Type (UCNT).

Other histological types are much rarer. They include papillary-type adenocarcinomas, salivary-type carcinomas, hematological disease localizations and bone and soft tissue tumors.

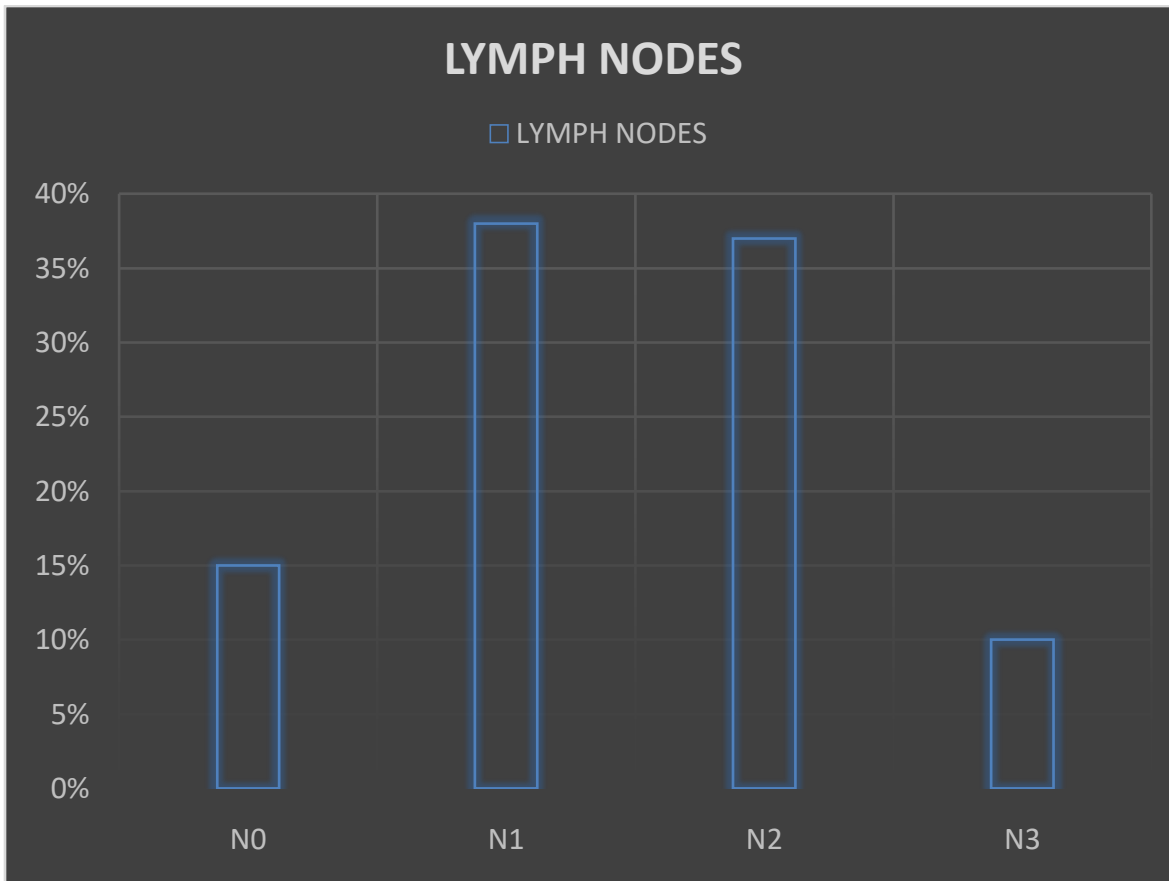
UCNTs predominate, accounting for 70% of cases. These data concur with those found in our series, where 87% of UCNTs were found, and are characterized by their association with Epstein-Barr virus (EBV) infection, often detectable at the time of diagnosis by plasma polymerase chain reaction (PCR), and characterized prognostically by better local control and greater propensity for distant metastases.

For our study tumors were classified as: T1 in 11 % in 33%, T3 in 24 %, and T4 in 32 % AJCC stage 8th edition.



**Figure 1:-** AJCC 8TH edition classification:

This is a 75% to 90% lymphophilic cancer, with bilaterality in 50% of cases. In our series, patients were classified as N0 in 15%, N1 in 38%, N2 in 37%, and N3 in 10% of patients.



**Figure 2:-** Lymph nodes statut for our patients.

Nasopharyngeal cancer is a radiosensitive and chemosensitive cancer, and concomitant radio-chemotherapy is the standard treatment, particularly for stages III to IVA of the 8th edition of the AJCC (American Joint Commission on Cancer) and UICC (Union for International Cancer Control) classification [2], in terms of overall survival confirmed by several randomized trials, including Alsarraf's Intergroup trial in 1999 and the meta-analysis by Baujat et al. These data were updated in 2015 by Blanchard et al [3], who found a 6.3% benefit in terms of 5-year overall survival rate from the addition of concomitant chemotherapy to radiotherapy.

Despite the advent of intensity-modulated conformal radiotherapy (IMRT) and the addition of induction or adjuvant chemotherapy, the prognosis at these stages remains unfavorable, with high rates of locoregional recurrence and metastatic relapse.

Concomitant chemoradiotherapy is the standard treatment for stage III and IVA tumors. The reference drug is cisplatin. The most commonly used regimens are cisplatin 100 mg/m<sup>2</sup> every three weeks or 40 mg/m<sup>2</sup>/week [3], [4]. Despite the benefits of adding concomitant chemotherapy, relapses remained frequent (30-40%), and treatment intensification was proposed.

Induction chemotherapy followed by chemoradiotherapy is the new standard for locally advanced nasopharyngeal carcinoma. For stages III-IVA, the European Society for Medical Cancer (ESMO) and the European Reference Network for Rare Adult Solid Cancers (EURACAN) recommend either induction chemotherapy followed by chemoradiotherapy, chemoradiotherapy alone, or chemoradiotherapy followed by adjuvant chemotherapy [5].

Induction chemotherapy provides early symptom relief, early eradication of micrometastatic disease and a reduction in macroscopic tumor volume, thus facilitating irradiation and sparing nearby critical structures. In the first meta-analysis of individual data from four randomized trials, Chen et al [6] found that the addition of induction chemotherapy to chemoradiotherapy was associated with an absolute benefit of 6.5% at 5 years in the probability of metastasis-free survival ( $p = 0.008$ ), 9.3% in the probability of event-free survival ( $p = 0.0009$ ) and 5.5% in the probability of overall survival ( $p = 0.04$ ). In a second meta-analysis published in 2020 of 10 randomized trials, Wang et al [7] found a significant reduction in locoregional relapses from 18.6% to 15% ( $p = 0.002$ ).

In our study treatment modalities included neoadjuvant chemotherapy followed by concurrent chemoradiotherapy using cisplatin associated to gemcitabine for three cycles in 86% of patients and concurrent chemoradiotherapy alone in 14% cases.

Compared with conventional three-dimensional conformal techniques, IMRC significantly reduced acute and late side effects, including xerostomia, neurological toxicity, trismus, hypoacusis, cervical fibrosis and dysphagia, and thus significantly improved quality of life.

In addition, IMRT provides more consistent and homogeneous coverage of the target volumes to be treated, avoiding the areas of overdosage found with conventional techniques. Two recent meta-analyses by Du et al [8] and Luo et al [9] showed that, compared with conventional radiotherapy, RCMI improved not only locoregional disease control (absolute benefit of 4.7% to 5.8%) and overall survival (absolute benefit of 3.7%), but also event-free survival (absolute benefit of 4.2% to 4.9%), making it the reference irradiation technique for nasopharyngeal cancers.

Volumetric intensity modulated arc therapy (VMAT) offers a major reduction in treatment time. VMAT is not simply a rotational form of IMRT, since dose rate, arm speed and collimator blade position can vary continuously during a treatment session.

This technique significantly improves dosimetric coverage of complex tumor volumes while better preserving surrounding healthy tissue.

For our study concurrent chemoradiotherapy, total dose was 69,96-70 Gray in 33-35 fractions 5 days a week using Volumetric Modulated Arc Therapy (VMAT) plus cisplatin weekly at a dose of 40 mg per square meter of body surface. Acute toxicities reported in 42% of patients, with higher incidence of radiomucositis Grade 2 and 3 observed in N3 lymph node status (20%) and in patients with larger GTV size (25%). Late toxicities included grade 1-2 xerostomia in 45% of patients and grade 1 skin fibrosis in 15%. Oral and esophageal mucositis resulted in pain, dysphagia, and weight loss, with 33% of patients losing more than 8 kg, 56% losing between 3 and 8 kg, and only 11% losing less than 3 kg. 3% of patients failing to complete the prescribed radiotherapy course, regardless of age group.

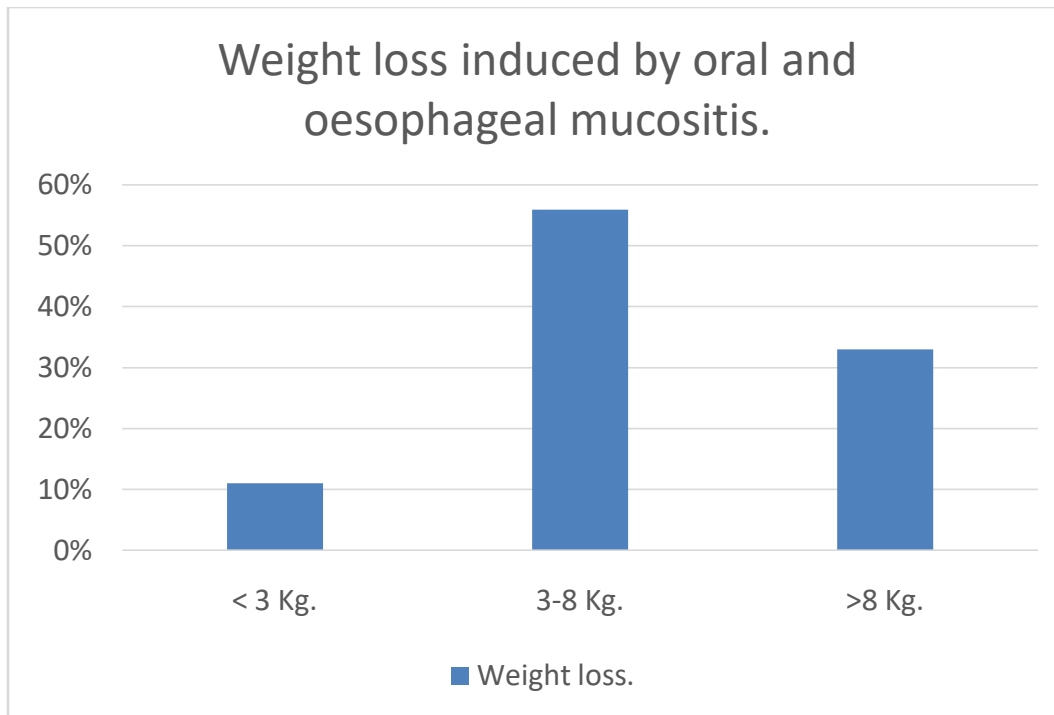


Figure 3:- Weight loss induced by mucositis.

For our study at a median follow-up of 48 months, the 2-year recurrence-free survival was 75%, and the Overall survival at 2 years was 89.4%, while recurrence and metastatic progression rates were 11% and 4%, respectively. Cancer-related mortality accounted for 6% of cases, and 4% were lost to follow-up.

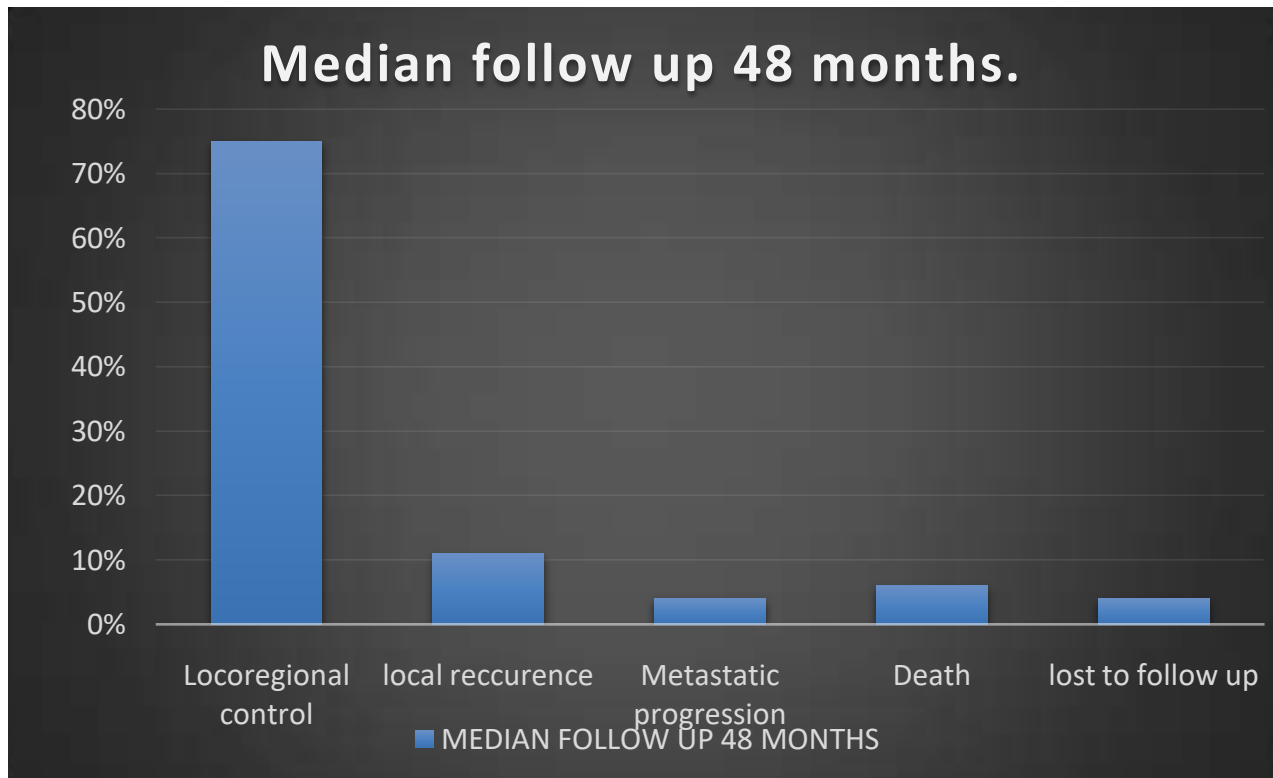


Figure 4:- Patients evolution follow up 48 months.

Locally advanced non-metastatic nasopharyngeal carcinoma is a distinct clinical entity, for which treatment results remain unsatisfactory despite new radiotherapy techniques and chemotherapy combinations.

The addition of induction chemotherapy reduces the risk of distant metastases and improves carcinological results. However, local and especially distant failure rates remain high for stages T3-4 and N2-3. Future therapeutic approaches should be proposed to reduce this risk of failure.

Our analysis reveals a strong correlation between tumor volume and treatment response in nasopharyngeal cancer patients undergoing radiotherapy. Larger tumor volumes often lead to increased treatment resistance, local recurrence, and distant metastasis. Moreover, high tumor volumes are associated with higher rates of treatment-related toxicity.

### **Conclusion:-**

The results of our study are similar to literature's results; the induction chemotherapy followed by concurrent chemoradiotherapy in the locoregionally advanced nasopharyngeal carcinoma promotes distant control and increases overall survival.

Radiotherapy with modulated intensity and concurrent chemotherapy are effective, and well tolerated in the treatment of nasopharyngeal cancer.

However, side effects are unavoidable so they must be recognized and treated early to avoid grade 3 and 4.

To improve on current results, efforts are needed to evaluate and develop new therapeutic strategies

### **Reference:-**

- [1] Fandi A, Eschwege F, Cvitovic E et Coll. Carcinomes indifférenciés du nasopharynx, Aspects épidémiologiques, Cliniques et thérapeutiques. Bull. Cancer, 1994, 81: 571-86.
- [2] Amin MB, Edge S, Greene F, Byrd DR, Brookland RK, Washington MK, et al. AJCC Cancer Staging Manual. 8th ed. Springer International Publishing; 2017.
- [3] Blanchard P, Lee A, Marguet S, Leclercq J, Ng WT, Ma J, et al. Chemotherapy and radiotherapy in nasopharyngeal carcinoma: an update of the MAC-NPC meta-analysis. Lancet Oncol 2015;16:645–55, [http://dx.doi.org/10.1016/S1470-2045\(15\)70126-9](http://dx.doi.org/10.1016/S1470-2045(15)70126-9).
- [4] Baujat B, Audry H, Bourhis J, Chan AT, Onat H, Chua DT, et al. Chemotherapy as an adjunct to radiotherapy in locally advanced nasopharyngeal carcinoma. Cochrane Database Syst Rev 2006, <http://dx.doi.org/10.1002/14651858.CD004329.pub2>.
- [5] Bossi P, Chan AT, Licitra L, Trama A, Orlandi E, Hui EP, et al. Nasopharyngeal carcinoma: ESMO-EURACAN Clinical Practice Guidelines for diagnosis, treatment and follow-up. Ann Oncol 2021;32:452–65, <http://dx.doi.org/10.1016/j.annonc.2020.12.007>.
- [6] Chen Y-P, Tang L-L, Yang Q, Poh S-S, Hui EP, Chan AT, et al. Induction chemotherapy plus concurrent chemoradiotherapy in endemic nasopharyngeal carcinoma: individual patient data pooled analysis of four randomized trials. Clin Cancer Res 2018;24:1824–33, <http://dx.doi.org/10.1158/1078-0432.CCR-17-2656>.
- [7] Wang P, Zhang M, Ke C, Cai C. The efficacy and toxicity of induction chemotherapy plus concurrent chemoradiotherapy in locoregionally advanced nasopharyngeal carcinoma: a meta-analysis of randomized controlled trials. Medicine 2020;99:e19360, <http://dx.doi.org/10.1097/MD.00000000000019360>.
- [8] Du T, Xiao J, Qiu Z, Wu K. The effectiveness of intensity-modulated radiation therapy versus 2D-RT for the treatment of nasopharyngeal carcinoma: a systematic review and meta-analysis. PLoS ONE 2019;14:e0219611, <http://dx.doi.org/10.1371/journal.pone.0219611>.
- [9] Luo M-S, Huang G-J, Liu H-B. Oncologic outcomes of IMRT versus CRT for nasopharyngeal carcinoma: a meta-analysis. Medicine 2019;98:e15951, <http://dx.doi.org/10.1097/MD.00000000000015951>.