



Journal Homepage: - www.journalijar.com
**INTERNATIONAL JOURNAL OF
 ADVANCED RESEARCH (IJAR)**

Article DOI: 10.21474/IJAR01/4201
 DOI URL: <http://dx.doi.org/10.21474/IJAR01/4201>



RESEARCH ARTICLE

VITAMIN C ASSOCIATED GINGIVAL ENLARGEMENT.

**Dr. Shaila Chaudhary¹, Dr. Shoba Fernandes², Dr. Jayasudha Kalgudi³, Dr. Yash Bafna³, Dr. Dhvani Patel⁴
 and Dr. Jaysukh Santoki⁴.**

1. Post Graduate Student, Department of Paediatric and Preventive Dentistry, Narsinhbhai Patel Dental College and Hospital, Visnagar, India.
2. Professor and Head, Department of Paediatric and Preventive Dentistry, Narsinhbhai Patel Dental College and Hospital, Visnagar, India.
3. Reader, Department of Paediatric and Preventive Dentistry, Narsinhbhai Patel Dental College and Hospital, Visnagar, India.
4. Post Graduate Student, Department of Paediatric and Preventive Dentistry, Narsinhbhai Patel Dental College and Hospital, Visnagar, India.

Manuscript Info

Abstract

Manuscript History

Received: 14 March 2017
 Final Accepted: 12 April 2017
 Published: May 2017

Copy Right, IJAR, 2016,. All rights reserved.

Introduction:-

Increase in size of gingiva is a common feature of gingival disease. This is clinically designated as gingival enlargement or gingival overgrowth. The terms overgrowth or enlargement are descriptive terms. Hyperplasia is a histologic term used to describe the increase in a number of cells. It should be distinguished from hypertrophy, which is an overgrowth due to increased size of the cells. Gingival enlargement may be caused by fibrous overgrowth or gingival inflammation or a combination of two. (Newman, 1996) The types of gingival enlargement can be classified according to etiologic factors and pathologic changes as follow:

1. Inflammatory enlargement
2. Drug induced enlargement (e.g., cyclosporin A, phenytoin, nifedipine)
3. Enlargement associated with systemic disease (e.g., leukemia, vitamin C deficiency/Scurvy, Puberty)
4. Neoplastic enlargement

Gingival enlargement is a ordinary finding in clinical practice and the appropriate treatment depends on correctly diagnosing the cause of the enlargement. (Agrawal, 2015) Gingival enlargement is a gingival dimorphism associated with multiple factors. It is characterized by evident growth of the gingiva vertically toward the incisal edge of the clinical crown and horizontally toward the buccal-lingual area and is more prevalent in the buccal surfaces of the anterior teeth. (McDonald, 2000; Stewart, 1982)

Vitamin C deficiency/Scurvy was initially associated with sailors who undertook lengthy sea voyages; their inadequate intake of ascorbic acid during these journeys led to spontaneous bleeding from periodontal tissues and abnormal gingival enlargement. However, vitamin C deficiency/Scurvy is infrequently encountered in modern industrialized nations. (Mandl et al., 2009).

Corresponding Author:- Dr. Shaila Chaudhary.

Address:- Post Graduate Student, Department of Paediatric and Preventive Dentistry, Narsinhbhai Patel Dental College and Hospital, Visnagar, India.

In the present case report, we note that oral supplementation with ascorbic acid (also known as vitamin C) and periodontal treatment are effective at suppressing Vitamin C deficiency associated gingival enlargement. We believe that this case report will remind readers of the effect of vitamin C deficiency on periodontal conditions.

Case Report:-

A 15 yrs old male patient reported to the Department of Pedodontic and Preventive dentistry, Narsinhbhai Patel Dental College and Hospital, Visnagar, North Gujarat with the complaint of swollen gums in the upper and lower, front and back tooth region of the jaw on both sides since 1-2 months. No relevant medical history recorded. The patient had not previously used any medication known to provoke gingival enlargement. No family history indicating a cause for the condition.

Past dental history revealed that patient had taken medication for 7 days which was prescribed by department of Oral Medicine And Radiology. Medications were Metronidazole, Chlohex mouthwash, Zincovit syrup. Patient had undergone blood investigation (CBC) 7 days back which was normal. No abnormality was detected with systemic condition.

An intra-oral examination revealed that gingiva was reddish, spongy, edematous, soft and friable with a smooth, shiny surface and tendency to bleed on probing. Diffuse type of grade II moderate gingival overgrowth involving interdental papilla, marginal and attached gingiva extend till cervical 1/3rd of the teeth. Miller's Class II gingival recession irt 32, 41, 42. (Fig. 1).

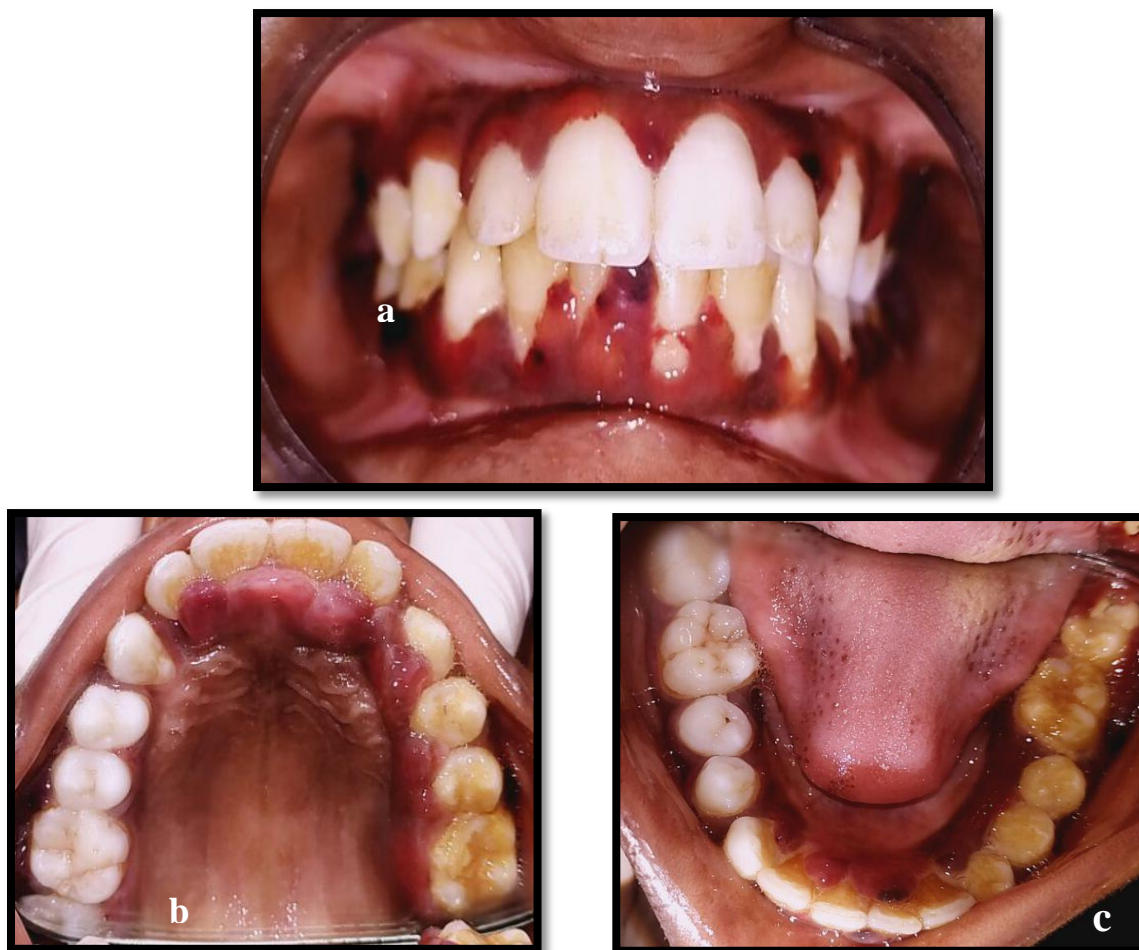

Fig. 1:- Preoperative Intraoral photographs showing gingival enlargement (a) Frontal view (b) Maxillary view (c) Mandibular view]

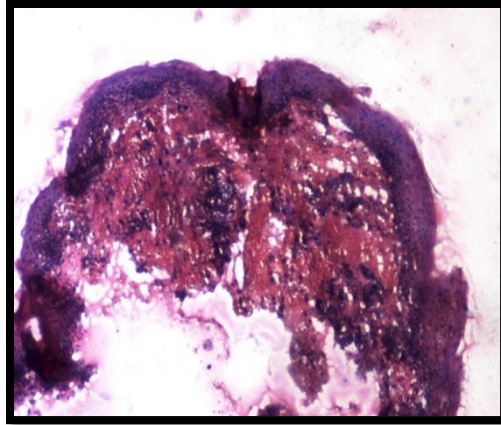


Fig. 2:- Histopathological photograph.

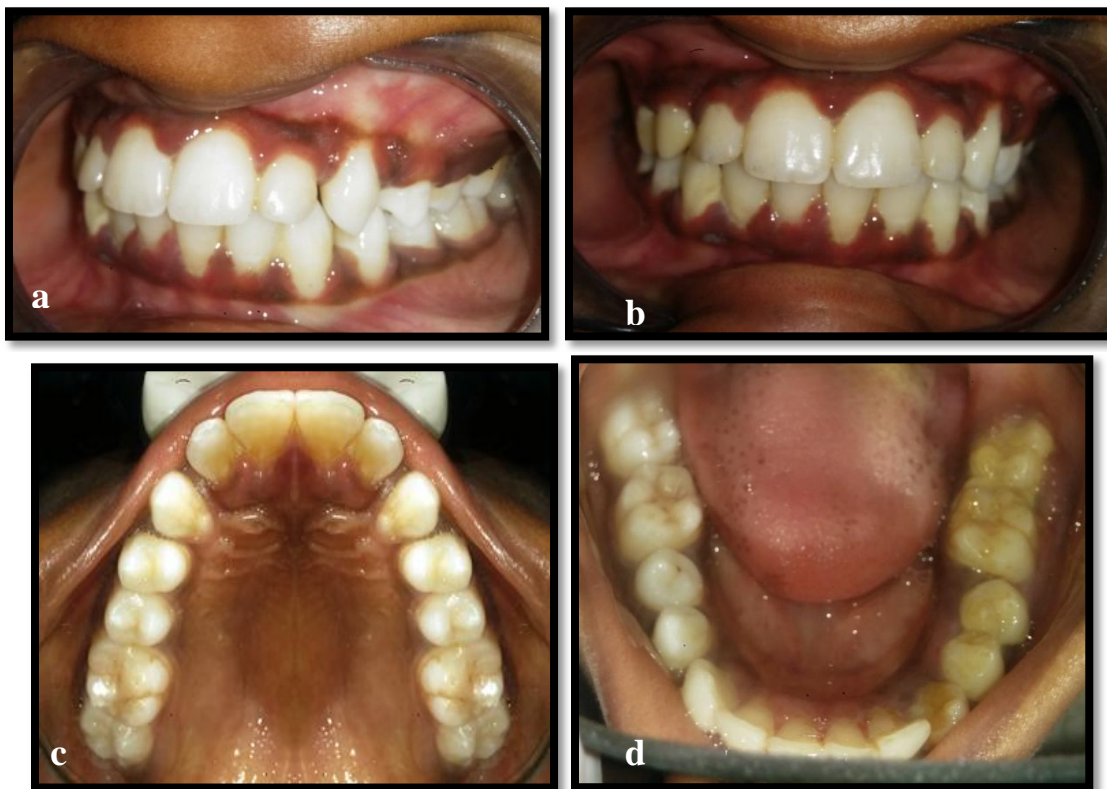

Fig. 3:- Postoperative Intraoral photographs after 15 days showing diminished gingival enlargement (a,b) Frontal view (c) Maxillary view (d) Mandibular view.

Incisional Biopsy taken for Histopathology investigation. Parakeratinized stratified squamous epithelium and hemorrhagic areas were seen. Subepithelially there was connective tissue infiltrated with inflammatory cells. Histopathological pictures were suggestive of chronic gingival hyperplasia.(Fig. 2)

Vitamin C deficiency gingival enlargement was made as a provisional diagnosis on the basis of dietary history and clinical presentation, although pubertal gingival enlargement were considered for differential diagnosis, considering age of the patient.

Oral hygiene was maintained without any surgical periodontal treatment with only sonic scaling of the supra- and subgingival tooth surfaces. Patient was administered chewable vitamin C tablets 500 mg OD and nutritional

counseling (to the parent and patient both) was done to include vitamin C rich fruits and vegetables in his diet. Patient's response to the therapy was dramatic. There was an incredible change in the gingival health with marked reduction in the hemorrhagic appearance and inflammatory component within 15 days (Fig. 3). Patient was recalled every 15 days to monitor his gingival conditions and overall health.

Discussion:-

Gingival overgrowth causes aesthetic and functional difficulties. The etiopathogenesis of gingival overgrowth is usually associated with factors such as the use of certain drugs or systemic disorders such as vitamin C deficiency. (Rajendra,2006) In the present case, we consider the main pathological entity to be related to a deficiency of vitamin C. The local factors i.e. plaque and calculus are known to be responsible for gingival enlargement. However, vitamin C deficiency is infrequently encountered in the modern era and the vitamin C deficiency was missed when the patient first presented for treatment. (Patil et al., 2014)

Vitamin C is an essential vitamin for maintaining a healthy body. Recent reports have suggested various roles for vitamin C is divergent (i.e., various hydroxylation reactions; redox homeostasis of subcellular compartments including the mitochondria and endoplasmic reticulum; nucleic acid and histone dealkylation; and proteoglycan deglycation) (Mandl et al, 2009). In addition, vitamin C plays a major role in collagen biosynthesis and maturation, and it is essential for the maintenance of the basal membrane. (Mandl et al, 2009) In the present case, the mild vitamin C deficiency may have been linked to a decreased ability to cross-link to collagen and therefore to an impaired ability to synthesize stable collagen fibers.

In our case report, the patient presented with some of the signs and symptoms typical of vitamin C deficiency i.e. hemorrhagic and edematous gingiva and nutritional deficiency. Patients are treated based on clinical manifestations. We believe this case report will be a useful reminder of the pathological effects of vitamin C deficiency on gingival inflammatory changes.

Dentists and physicians should be aware of the clinical presentations of vitamin C deficiency, because the presentation of the patient with Scurvy may be subtle.

Conclusion:-

The present case report suggests that mild vitamin C deficiency and the local factors i.e. plaque and calculus may be associated with the pathogenesis of severe gingival overgrowth. Gingival enlargement is multifactorial and complex in nature, which may be in response to various interaction between host and environment. Gingival Overgrowth considerably reduces the quality of life and may result in serious emotional and social problems due to esthetics and functionality.

References:-

1. Agrawal, A. A. (2015). Gingival enlargements: Differential diagnosis and review of literature. *World Journal of Clinical Cases: WJCC*, 3(9), 779.
2. Desai, V. D., Hegde, S., Bailoor, D. N., & Patil, N. (2009). Scurvy extinct? Think again!. *International journal of clinical pediatric dentistry*, 2(3), 39.
3. Mandl, J., A. Szarka, and G. Banhegyi. (2009) Vitamin C: update on physiology and pharmacology. *Br. J. Pharmacol.* 157:1097–1110.
4. McDonald RE, Avery DR. *Dentistry for the Child and Adolescent*. 7th ed. USA: Mosby Company; 2000. Gingival and periodontal diseases
5. Newman MG, Takei H, Klokkevold PR, Carranza FA. *Carranza's Clinical Periodontology*, 9th ed. Philadelphia:Saunders; 1996. p. 280-4.
6. Patil NA, Kale VT, Janrao KA, Nalawade SS, Pawar RL. (2014) Chronic inflammatory gingival enlargement: A case report. *J Dent Orofac Res*;10(1):33-5
7. Rajendran, R. and Sivapathasundram, B. (2006) *Shafer's Textbook of oral pathology*. Elsevier: New Delhi, India. (5th Ed.)
8. Stewart RE. USA: Mosby Company; 1982. *Periodontal diseases in children. Pediatric Dentistry and Clinical Practice*.