



Journal Homepage: - www.journalijar.com

INTERNATIONAL JOURNAL OF ADVANCED RESEARCH (IJAR)

Article DOI: 10.21474/IJAR01/19369

DOI URL: <http://dx.doi.org/10.21474/IJAR01/19369>



RESEARCH ARTICLE

THE BENEFITS OF PLASTIC AND RECONSTRUCTIVE SURGERY IN THE MANAGEMENT OF AN EAR HAMARTOMA

Dr. K. Benlaaguid, Dr. Marzak, Dr. Sylla, Dr. Sahir, Dr. Fifatin, Pr. S. Boukind, Pr. El Atiqi, Pr. El Amrani and Pr. Y. Benchamkha

Department of Plastic and Reconstructive Surgery, Mohamed VI University Hospital, Marrakesh.

Manuscript Info

Manuscript History

Received: 25 June 2024

Final Accepted: 27 July 2024

Published: August 2024

Abstract

Hamartomas of the ear in children present significant aesthetic and functional challenges, requiring a precise surgical approach to achieve optimal results. We report the case of a 6-year-old child treated for a hamartoma of the left ear with resection of the lesion followed by a split-thickness skin graft. This article describes in detail the patient's clinical presentation, the surgical technique used, and the post-operative results and discusses the efficacy of this approach.

Copyright, IJAR, 2024. All rights reserved.

Introduction:-

Hamartomas of the ear in children are a rare but clinically significant anomaly (1), characterized by abnormal growth of malformed tissue in the auricular region. Although often benign, these anomalies can lead to aesthetic and functional defects, particularly when they reach a significant size, presenting a challenge for post-surgical coverage. In some cases, the size of the hamartoma may require a complex surgical approach, presenting the surgeon with a real challenge in achieving optimal aesthetic results while preserving the functionality of the organ. Here we present the case of a 6-year-old child who was treated for a congenital hamartoma of the left ear by excision of the lesion followed by coverage with a split-thickness skin graft. This study documents the process of managing his condition, highlighting the clinical and aesthetic results obtained, as well as the implications of this approach in clinical practice.

Case presentation

Y.E, a 6-year-old male child, was referred to our department for assessment and management of a skin lesion on the left ear auricle that had been identified at birth and had gradually increased in size over time, causing aesthetic and psychosocial discomfort and affecting his performance and interactions at school and his recreational activities with his peers. Y.E. was the youngest of two siblings in Marrakesh and had no notable medical history. The initial examination revealed a papular, hyperpigmented, painless pedicled skin lesion on the posterolateral side of the left auricle. It was 8*3 cm in diameter, covering the entire auricle and mastoid process. A similar lesion was also observed in the anterior cervical region, 6*0.8 cm in diameter, suggesting an association between the two anomalies (Figure 1).

Corresponding Author:- Dr. K. Benlaaguid

Address:- Department of Plastic and Reconstructive Surgery, Mohamed VI University Hospital, Marrakesh.

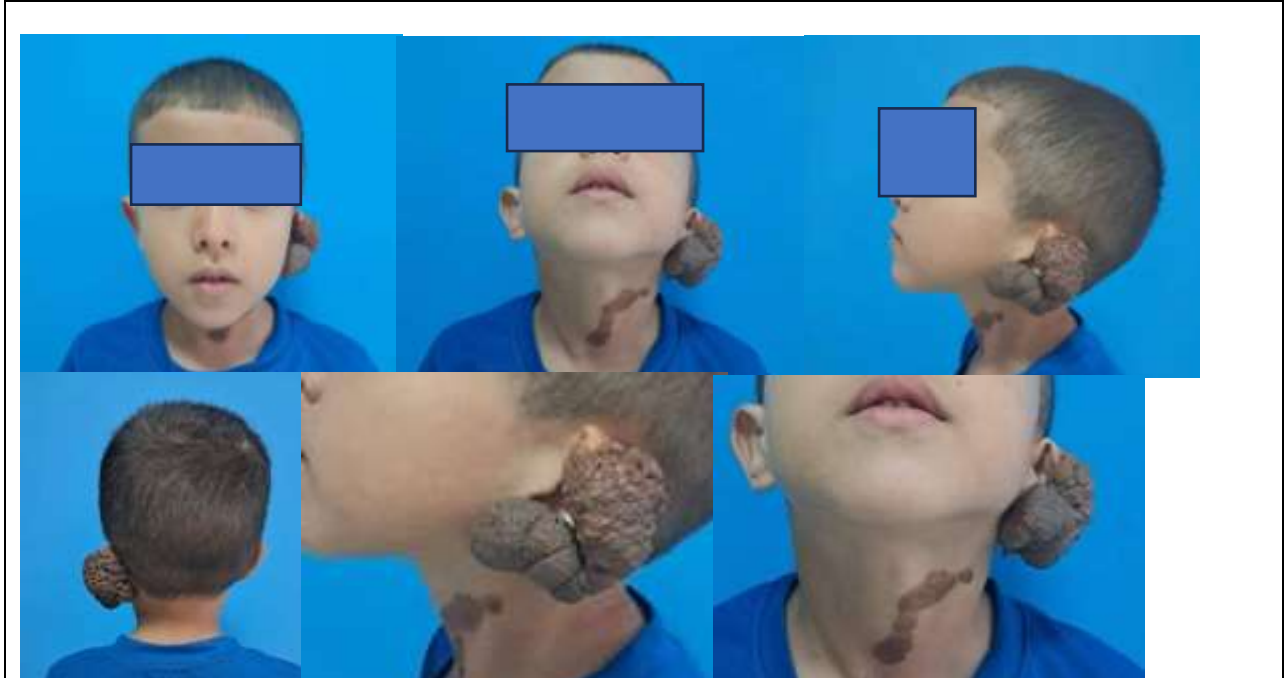

Figure 1:- Photographs of the patient at the pre-operative consultation.

A cervicofacial CT scan (Figure 2) was performed and confirmed a diffuse thickening of the left auricle, responsible for a narrowing of the external auditory canal, with no suspicious bone involvement. Based on these findings, the patient was diagnosed with a hamartoma of the left ear.

Because of the extent of the lesion and its aesthetic, functional and psychosocial implications, a surgical approach was considered.

The parents were fully informed of the implications of the surgical procedure, including the potential risks and benefits, and informed consent was obtained.

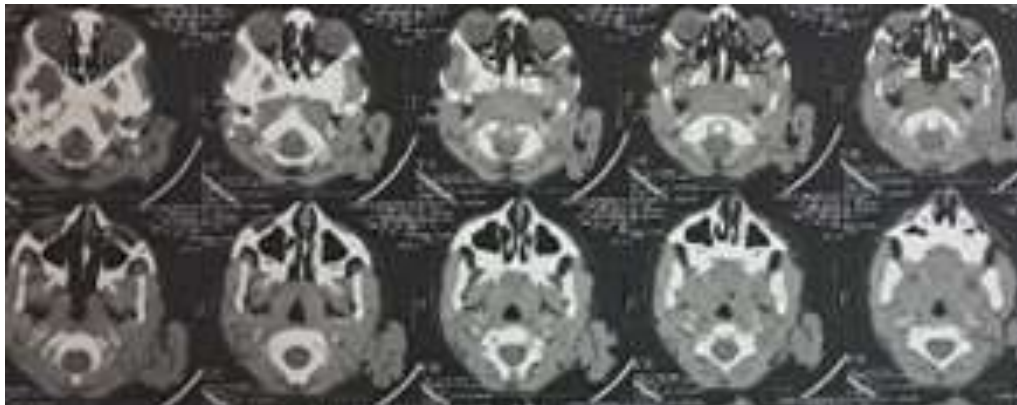


Figure 2:- Cervicofacial CT scan results.

Cc:- Diffuse budded thickening of the left auricle: responsible for narrowing of the external auditory canal.
- No suspicious bone lesions.

After adequate pre-operative preparation, the patient was admitted to the central operating room in the first position, and the surgical procedure consisted of tumor removal in three stages. Firstly, a monobloc removal of the auricular lesion was performed (Figure 3), paying particular attention to hemostasis. Next, a split-thickness skin graft was obtained from the patient's left thigh using an electric dermatome and then grafted to the area of excision (Figure 4).

Finally, half of the cervical lesion was removed while respecting the tension lines, followed by careful tissue closure (Figure 5).

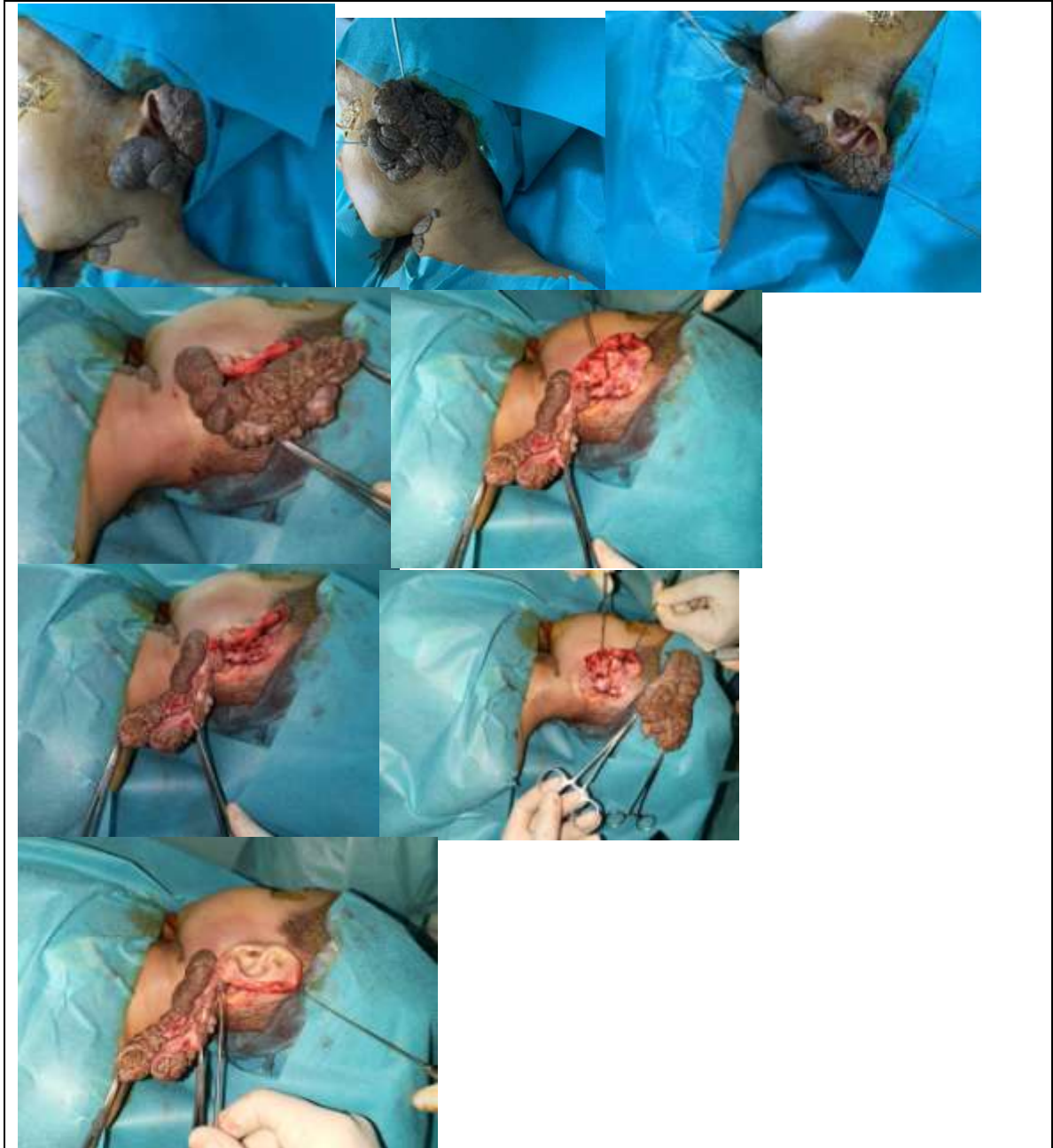

Figure 3:- Stages of tumor removal.

Post-operative treatment, including antibiotic therapy and close monitoring, was implemented to prevent complications and ensure optimal patient recovery.

The postoperative period was normal, with no excessive bleeding, infection or major complications. On day 1 postoperative, the child was declared discharged.

On day 5 post-operative, the patient was seen again for a check-up and a change of dressing. The skin graft was assessed and found to be complete, with no signs of lysis or infection.

Thereafter, the child received regular follow-ups to monitor the healing and progress of the graft. Healing progressed satisfactorily and complete healing was observed (Figure 6 ,7) with a satisfaction rate of 100%. The parents expressed their satisfaction with the progress observed in their child, particularly in terms of his integration into the school environment and his self-confidence.

Post-excisionanatomopathology results revealed a morphological appearance consistent with an epidermal hamartoma, confirming the pre-operative diagnosis (Figure 8).

Concerning the associated cervical involvement, a decision was taken to schedule another surgical excision after 6 months. This approach will allow the patient to be monitored.

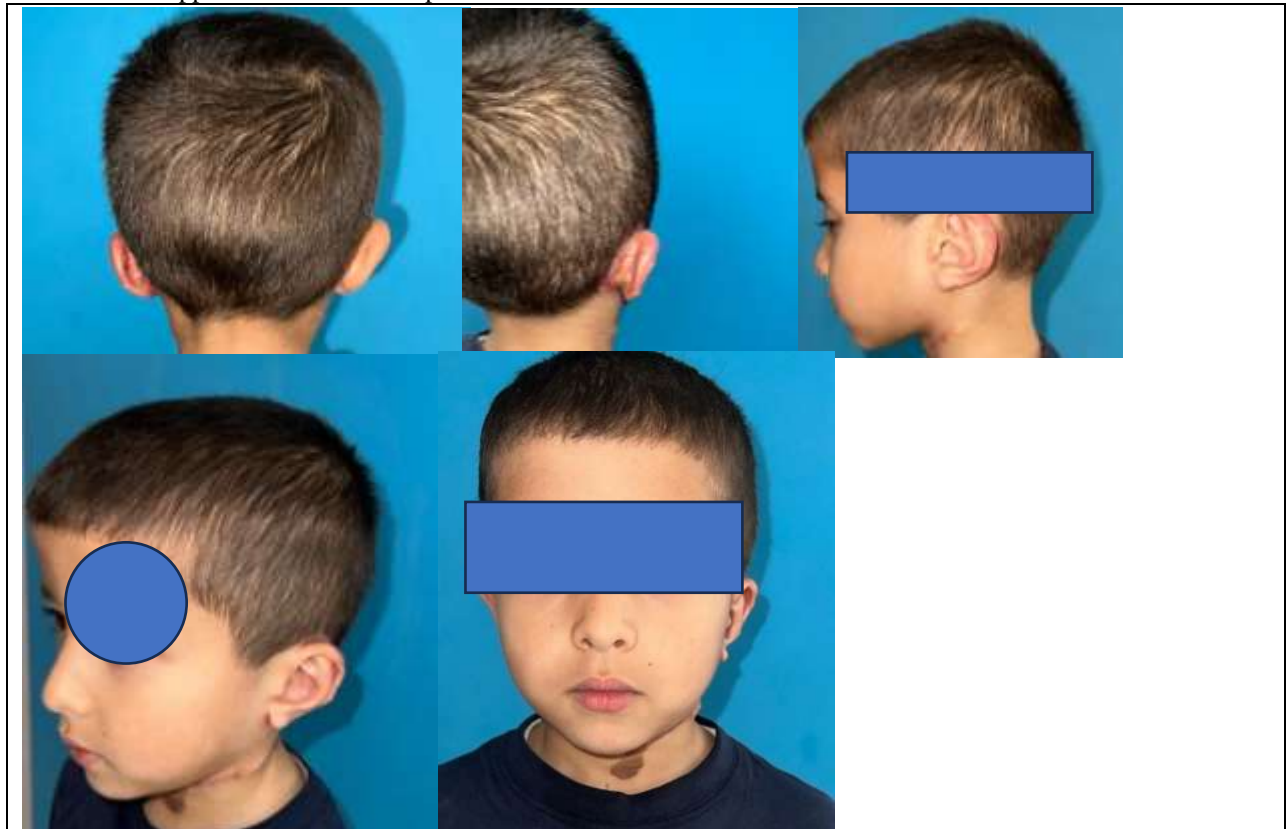

Figure 2:- Résultats a 1 mois postopérateur.

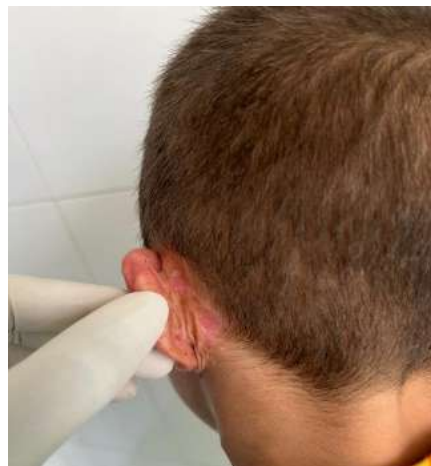

Figure 7:- Results at 6 month postoperative.

Results	Morphological aspect compatible with an epidermal hamartoma.
	Absence of signs of malignancy

Figure 8:- Results of the anatomopathological examination of the surgical specimen.

Discussion:-

A hamartoma forms as a result of a prenatal developmental abnormality, whereas a cutaneous hamartoma is a benign non-melanocytic growth of the skin. It is crucial to identify the affected skin structures and to specify the location, topography, and extent of the lesion. The diagnosis is usually made clinically (1). These lesions can vary in size from small to extensive, sometimes having a papular or verrucous texture, and can be grey, brown, or black. They may adopt a linear or swirling shape, often along Blaschko's lines, which correspond to the migration paths of cutaneous embryonic cells (2). Epidermal hamartoma of the ear is a rare form, and our observation is distinguished by the size and location of the hamartoma, which completely covers the left auricle with a cervical lesion. In our observation, no previous study presenting such an exceptional and extensive localization was found.

In our observation, we noted the presence of an isolated epidermal hamartoma, without associated extra-cutaneous manifestations, such as neurological, visceral, skeletal, or ophthalmological signs (3), thus ruling out any correlation with complex syndromes. It should be noted that the notion of hamartoma degeneration is an old topic. However, recent studies have shown that the occurrence of malignant tumors in an epidermal hamartoma (EH) is rare(4). Concerning the risk of neoplastic evolution evoked for certain EH, and according to the presentation by Pr. Smail Hadj-Rabia (Paris) (2), recent data show that malignant transformation occurs in 0.9% of sebaceous hamartomas of the scalp, most often in adulthood(5). Furthermore, for almost all EH syndromes, there is no risk of transmission to offspring(5).

Therapeutic management is generally based on clinical monitoring, particularly in cases where cutaneous hamartomas remain limited. Mention should also be made of the emergence of the CO₂ laser as a promising therapeutic alternative (6). Studies have shown its efficacy in the treatment of cutaneous hamartomas, with satisfactory aesthetic results (7). However, in more extensive or symptomatic forms, a viable therapeutic option is surgical removal. In our case, given the location, extent, fragility of the affected area, i.e. the ear auricle, and the significant impact on the child's quality of life, particularly in psychosocial and aesthetic terms, this surgical approach was deemed the best option.

In terms of post-excision tissue reconstruction, a split-thickness skin graft was preferred to a flap due to the vascularisation of the subcutaneous tissue, thus ensuring better integration and a favorable aesthetic result. The use of a split-thickness skin graft in this case made it possible to restore the integrity of the skin and improve the aesthetic appearance of the affected area. This technique also helped to minimize damage to the structure and function of the ear, preserving its natural appearance (8).

Based on subjective evaluation, we found a 100% satisfaction rate. Parents expressed satisfaction with the progress observed in their child, particularly in terms of integration into the school environment and self-confidence.

Although this evaluation is subjective, it provides valuable information on the perceived impact of our therapeutic approach on the child's overall well-being. However, it should be noted that the use of objective and standardized measures could have strengthened the robustness of our study by providing additional quantitative data.

However, despite the good results observed in this case, it is important to recognize the limitations of this study, particularly the short-term follow-up of the patient. Lack of similar studies Longer-term studies are needed to assess the efficacy and durability of this surgical approach in the management of ear hamartomas in children.

Conclusion:-

Our patient's case highlights the efficacy of excision followed by skin grafting in managing ear hamartomas in children. This surgical approach offers a viable solution for patients with similar lesions, even though surgical management leaves a large loss of substance in place.

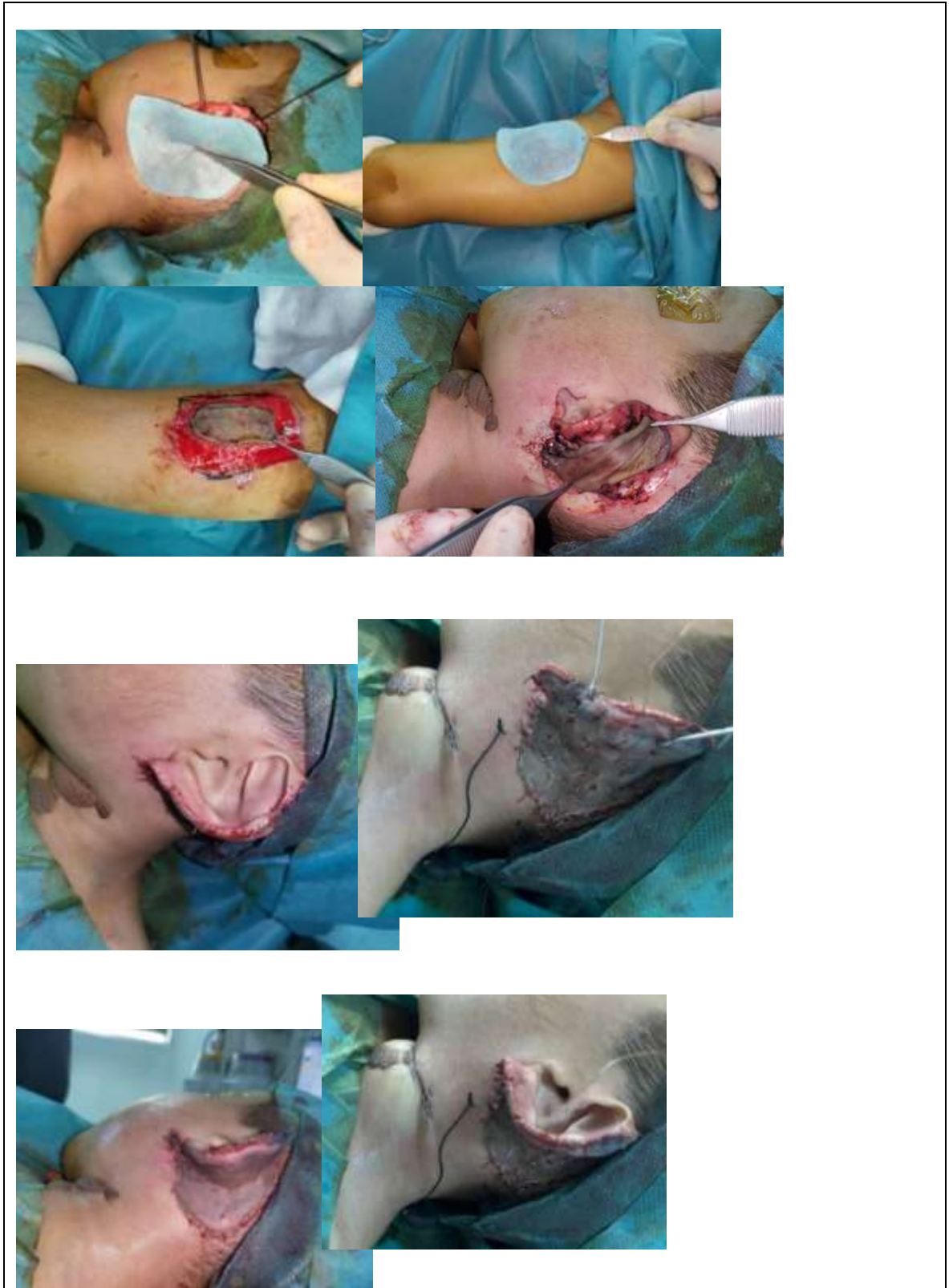

Figure 3:- Stages of skin grafting.

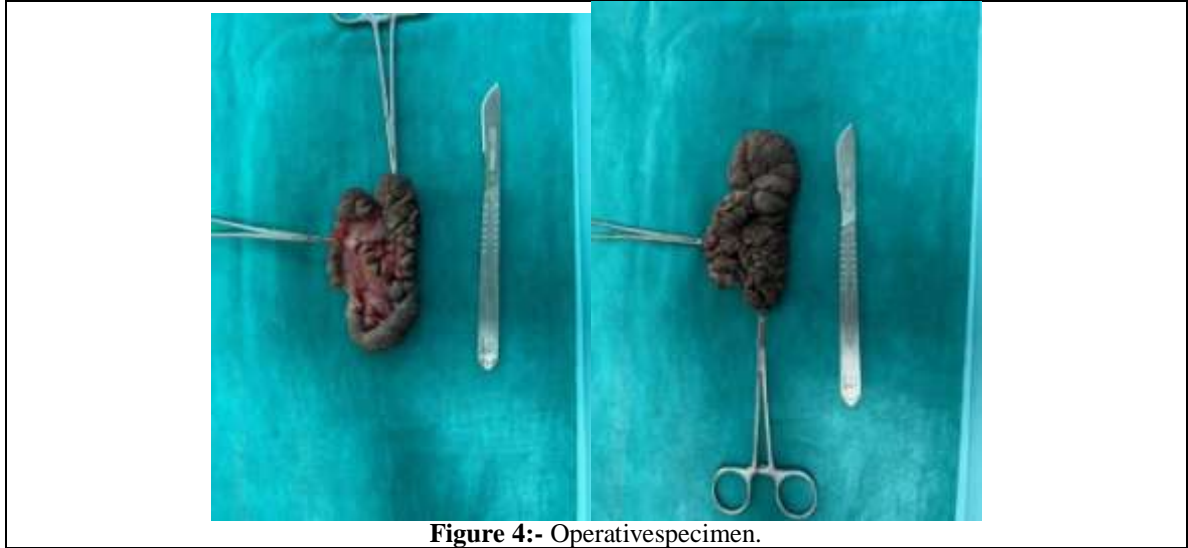


Figure 4:- Operativespecimen.

Références:-

1. Hazemann G, Michel C, Mahé A, Lipsker D, Cribier B. [Histopathological study of basaloid follicular hamartoma]. *Ann Dermatol Venerol.* mars 2019;146(3):181-91.
2. *Dermatologie Pratique* [Internet]. 2024 [cité 28 mars 2024]. Hamartome épidermique : quelle prise en charge ? Disponible sur: <https://www.dermatologie-pratique.com/journal/article/0011064-hamartome-epidermique-quelle-prise-en-charge>
3. Bahloul E, Abid I, Masmoudi A, Makni S, Kamoun F, Boudawara T, et al. Le syndrome de Schimmelpenning-Feuerstein-Mims : à propos d'un cas. *Arch Pédiatrie.* 1 nov 2015;22(11):1157-62.
4. Kelati A, Zeghari Z, Gallouj S, Elloudi S, Meziane M, Mernissi FZ. Les aspects dermoscopique de l'hamartome de Jadassohn : à propos de 7 cas. *Ann Dermatol Vénérologie.* 1 déc 2015;142(12, Supplement):S533-4.
5. Merrot O, Cotten H, Patenotre P, Piette F, Martinot Duquennoy V, Pellerin P. Risques évolutifs de l'hamartome sébacé de Jadassohn. *Ann Chir Plast Esthét.* 1 juin 2002;47(3):210-3.
6. Livideanu CB, Konstantinou MP, Lucas P, Viraben R, Lamant L, Kirsten N, et al. Un traitement inattendu pour un hamartome atypique. *Ann Dermatol Vénérologie.* 1 juin 2015;142(6, Supplement 2):S362-3.
7. Alkhalifah A, Fransen F, Le Duff F, Lacour JP, Wolkerstorfer A, Passeron T. Laser treatment of epidermal nevi: A multicenter retrospective study with long-term follow-up. *J Am Acad Dermatol.* déc 2020;83(6):1606-15.
8. Khan AA, Khan IM, Nguyen PP, Lo E, Chahadeh H, Cerniglia M, et al. Skin Graft Techniques. *Clin Podiatr Med Surg.* oct 2020;37(4):821-35.