



Journal Homepage: - [www.journalijar.com](http://www.journalijar.com)

## INTERNATIONAL JOURNAL OF ADVANCED RESEARCH (IJAR)

Article DOI: 10.21474/IJAR01/19348

DOI URL: <http://dx.doi.org/10.21474/IJAR01/19348>



### RESEARCH ARTICLE

#### CAN YOU IDENTIFY ME AND MY DEATH LATELY? A CHALLENGING TASK FOR EVERY FORENSIC EXPERTINA DECOMPOSED GUNSHOT BODY: AN AUTOPSY BASED CASE REPORT

Dr. Balla Gnana Naga Laxmi Narasimha Swamy<sup>1</sup>, Dr. Garima Singh<sup>2</sup> and Dr. Richa Gupta<sup>3</sup>

1. Post Graduate Resident, Department of Forensic Medicine and Toxicology, Sarojini Naidu Medical College, Agra.
2. Assistant Professor, Department of Forensic Medicine and Toxicology, Sarojini Naidu Medical College, Agra.
3. Associate Professor, Department of Forensic Medicine and Toxicology, Sarojini Naidu Medical College, Agra.

#### Manuscript Info

##### Manuscript History

Received: 21 June 2024

Final Accepted: 24 July 2024

Published: August 2024

##### Key words:-

Gunshot, Decomposition, Skeletal Remains

#### Abstract

Firearm usage for injuring or causing death of the opposite person or self is very dangerous. Dangerous weapons which are still in use by the people illegally in many parts of the world causing devastating crimes and suicides. A case report which challenges the forensic examiner of an unknown deceased individual with gunshot wound to the head. Upon discovery, the body had undergone significant decomposition, posing unique obstacles to post-mortem analysis. Despite the advanced stage of decay, meticulous forensic procedures were employed to ascertain the cause and manner of death. Thorough careful examination of skeletal remains, wounds on the skull was done for estimation of the height, gender and cause of death. This case highlights the complexities involved in conducting forensic investigations under conditions of advanced decomposition and underscores the importance of thorough forensic methodologies in elucidating the truth behind such tragic events.

Copyright, IJAR, 2024.. All rights reserved.

#### Introduction:-

The process of decomposition involves the breakdown of complex compounds into simpler forms. The forensic doctor faces more challenges when this develops in a deceased body, particularly identification of the body as well as determining the cause, manner, and time since death. It is one of the main problems in conducting an autopsy. Kronlein shot is the most devastating damage to the head and brain<sup>(1)</sup> which is very difficult in reconstruction of all the skull bones. Gunshot wounds can cause serious injury to the body, especially when they had been shot at close range. If the bullet pierces the brain, it would be fatal<sup>(2)</sup>. Death is inevitable and instantaneous. The NCBR data indicates that Uttar Pradesh leads the country in the illegal use of guns, which contributes to a higher crime rate in 2021. Here is the case which was in advanced decomposition with a gunshot to head.

#### Case report:

An unknown decomposed and partially skeletonized human body have been brought to the mortuary (Fig.1) of Sarojini Naidu Medical College by the Police for medicolegal autopsy and history given by them was, street dogs pulling and biting the exposed parts of the body found buried at the Chambal River bank, where the skull and all the four limbs were exposed above the burial ground.

**Corresponding Author:- Dr. Balla Gnana Naga Laxmi Narasimha Swamy**

Address:- Post Graduate Resident, Department of Forensic Medicine and Toxicology, Sarojini Naidu Medical College, Agra.

On external examination, height was 164 cm, foul smelling and the clothes were heavily soiled and intact. Skull and face were skeletonized, orbits are empty, post mortem dislocation of incisors of the maxillae are noted. Distal half of all the limbs were missing. Flesh was intact on the neck, shoulder, chest, arms, pelvis and thigh region. Skull, abdominal and distal regions of all the limbs were skeletonized. Ribs and vertebral column are exposed and the abdominal cavity is filled with mud. Larvae and pupae of maggots were crawling and present all over the body (Fig.2). Gender identified to be male with intact external genital organ and skull characteristics. Body was buried in moist soil which hastened the decomposition unlike the dry soil and on addition it was rainy season. The color, complexion, scars, moles of the face cannot be made out due to skeletonization except the pinna cartilage and thick leathery posterior scalp left behind.

On skull examination we noted a round hole of size 1 x 1cm, with a linear fracture line running above and below it, situated on the left frontal region which is 6 cm above the left Supra orbital ridge and 2 cm from the midline (Fig.3). A missing part of right temporal bone with irregular bony margins which was suggestive of carnivorous (dogs) activity. Another round wound of size 1 x 1 cm over the right parietal bone posteriorly with intact decomposed leathery scalp 7cm from the right ear pinna 4 cm from the midline with a depressed fracture of size 10 x 8cm (Fig.4). When the hole on the frontal region was observed from inside the cranial cavity it is found to be beveled with outer diameter less than inner diameter with irregular margins suggestive of an entry wound (Fig.6) due to the bullet<sup>(3)</sup> and exit point noted on right parietal bone posteriorly. No bullet was found in body and in X-Rays.

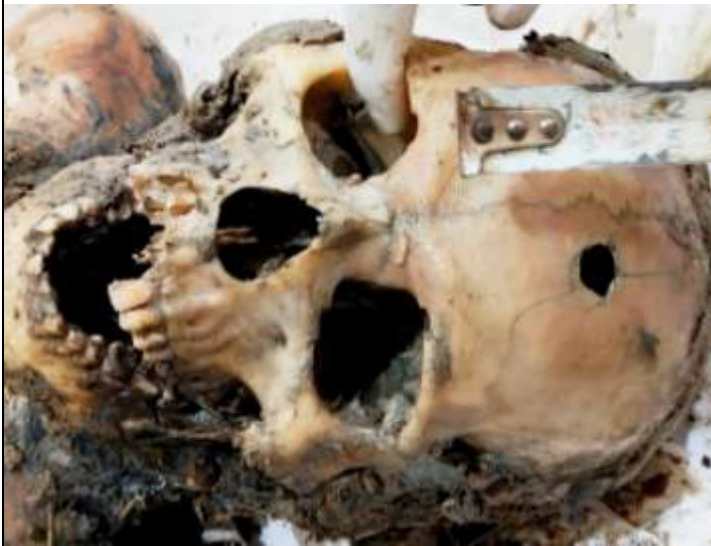On Internal examination, all the abdominal organs were decomposed, disintegrated and replaced with soiled material. In skull the brain matter decomposed and empty with only the greyish black decomposed Dura layer. Based on the entry and exit points, the bullet possibly made an entry on the left frontal bone and exited from the right parietal bone in a straight line, the direction was backwards, downwards and obliquely towards right side and exited. The range of shot cannot be determined as already the advanced decomposition was set in.

Age of the victim was estimated to be in between 21 and 30 years of age on the basis of fusion of sagittal sutures, X-rays of the joints and Dental examination<sup>(4,5)</sup>. Tooth and decomposed matter in the abdominal cavity were sent to FSL for DNA and toxicological analysis respectively. Cause of death was given as hemorrhagic shock as a result of gunshot to head and manner as homicidal. The approximate time since death given in this case is 2 to 6 weeks based on the decomposition changes.

After Police investigation, the body identified as 26 years old male, and a missing complaint was lodged by his brother on 2<sup>nd</sup> day of missing. The victim was a taxi driver and 4 young adult males hired him for a taxi ride and looted the victim, then shot on the head with a gun and buried the body on the river bank side, not so far away from the main road. Later taken away the taxi and thrashed in an abandoned place far away from the crime scene. Suspects were identified by the Police and upon investigation, they confessed that, to fulfil their hobbies and luxury life style, they looted and killed the driver, but it was their first crime starting with robbery and using dangerous weapon on the innocent person and got caught<sup>(7)</sup>.



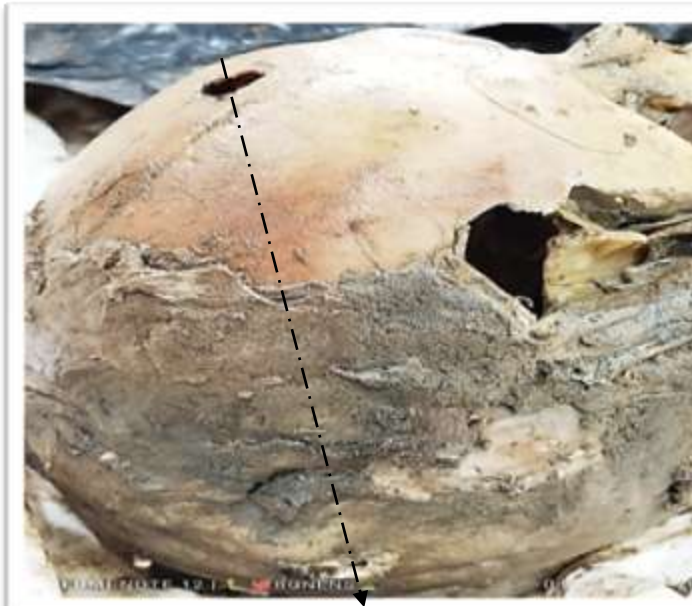**Figure 3:-** Entry wound on left frontal bone.



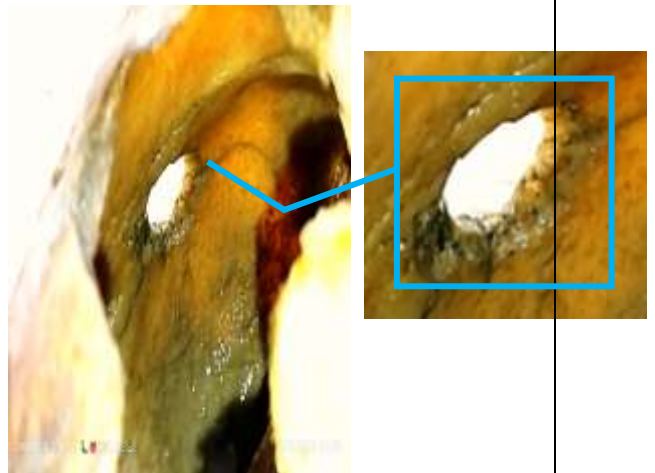
**Figure 4:-** Exit wound on the right parietal bone.



**Figure 5:-** Direction of the bullet (backwards, downwards, right side)



**Figure 6:-** Bevelling of the entry wound (view from inside the skull).



**Discussion:-**

Identification in advanced decomposed body is the main concern during routine forensic medical practice<sup>(7)</sup>. Post mortem changes vary from place to place, climate, insects, habitat, soil, temperature, humidity, season etc., which may either hasten or slow the process of decomposition.

In the above case, the moist soil and rainy season along with the insect activity, water content at the burial place hastened & favoured the decomposition process.

Even though the body changes and insect activity given the approximate time since death but not the exact time due to limitations and changes in decomposed bodies especially in a sub-continent like India due to variety of environment from one area to other area.

Study conducted by Brian L Peterson<sup>(8)</sup> in Philadelphia showed the internal bevelling of the entry wound in case of gunshot to the skull which was similar to this case report.

Macri F et al,<sup>(9)</sup> studied on various cases of head injury which caused by different weapons, of which the bullet shots described as internal and external bevelling commonly seen in entry and exit wound respectively.

Study done at Osmania medical college by Ambica and Khan<sup>(10)</sup> on 2 cases which are in advanced decomposition and partially skeletonized for medico legal autopsy showed time since death vary from different regional areas as well the challenges faced by the autopsy surgeons.

### Conclusion:-

The police and judiciary system will completely rely on the post-mortem report findings given by the forensic doctor which will help them to investigate. There are many challenges for the forensic doctor while conducting autopsy on bodies which are of in advanced stage of decomposition<sup>(11)</sup>.

To understand the rate of decomposition, few research groups set up a study called as 'body farmings' with different environmental conditions for the insects<sup>(10,12)</sup> which affects the process of decomposition but still it is developing stage.

Easy availability of the local hand guns illegally without license will lead to these kinds of homicides.

Everyone should be counselled and make aware of the Law to prevent this type of heinous crimes in the country. Majority of these types of crime happens in low class due to financial stress and lack of literacy. Government should ban and be vigilant on illegal country made firearms, smuggling & transport of weapons. Police should raid the persons with previous history of heinous crime for the search of dangerous weapons in their home to prevent further availability of guns and to decrease the crime rate related to fire arms and other.

### References:-

1. Gupta, Mayank & Tiwari, PraveenKumar. (2022). An Autopsy Case of the Decomposed Body with Kronlein's Shot and the Importance of Skull Reconstruction. International Journal of Applied and Basic Medical Research. 12. 47. 10.4103/ijabmr.ijabmr\_354\_21.
2. Adeolu AA, Akinbo OC, (2012) Gun shot injury as a cause of elevated skull fracture. J Neurosci Rural Pract. 2012 May;3(2):219-20. doi: 10.4103/0976-3147.98260. PMID: 22865989; PMCID: PMC3410009.
3. Menezes et al, (2023) A Nationwide Analysis of Gunshot Wounds of the Head and Neck: Morbidity, Mortality, and Cost. The Journal of Craniofacial Surgery 34(6):p 1655-1660, September 2023. | DOI: 10.1097/SCS.00000000000009268
4. Narayana Reddy K. S. and Murthy O.P., The Essentials of Forensic Medicine and Toxicology, Jaypee brothers medical publishers, 2016 34<sup>th</sup> ed: 57-67.
5. Narayana Reddy K. S. and Murthy O.P., The Essentials of Forensic Medicine and Toxicology, Jaypee brothers medical publishers, 2016 34<sup>th</sup> ed: 69-71.
6. [https://www.ncbi.nlm.nih.gov/books/NBK556119/#\\_\\_NBK556119\\_ai](https://www.ncbi.nlm.nih.gov/books/NBK556119/#__NBK556119_ai)
7. <https://www.amarujala.com/uttar-pradesh/agra/murder-for-hobby-taxi-driver-brutally-killed-skeleton-found-in-the-field-the-dogs-were-scratching-2023-10-12>
8. Peterson L. B. (1991). External Bevelling of Cranial Gunshot Entrance Wounds. Journal of forensic sciences. <http://dx.doi.org/10.1520/JFS13181J>.
9. Macri F, Dieckmeyer M, Hacking C, et al. High-velocity penetrating brain injury. Reference article, Radiopaedia.org (Accessed on 10 May 2024) <https://doi.org/10.53347/rID-41967>
10. Ambica K, Khan T, Challenges presented by decomposition in medico-legal autopsies-A case series. IP Int J Forensic Med Toxicol Sci 2023;8(4):171-176.
11. Shedge R, Krishan K, Warriar V. Postmortem Changes. In: Stat Pearls. StatPearls Publishing; 2023.
12. Byard RW, Tsokos M. The challenges presented by decomposition. Forensic Sci Med Pathol. 2013;9:135-137.

13. Quatrehomme, Gérald&Piercecchi-Marti, Marie-Dominique &Buchet, Luc & Alunni, Veronique. (2016). Bone beveling caused by blunt trauma: a case report. International Journal of Legal Medicine. 130. 10.1007/s00414-015-1293-0.
14. Narayana Reddy K. S. and Murthy O.P., The Essentials of Forensic Medicine and Toxicology, Jaypee brothers medical publishers, 2016 34<sup>th</sup> ed: 213.