



Journal Homepage: - [www.journalijar.com](http://www.journalijar.com)

## INTERNATIONAL JOURNAL OF ADVANCED RESEARCH (IJAR)

Article DOI: 10.21474/IJAR01/18910

DOI URL: <http://dx.doi.org/10.21474/IJAR01/18910>



### RESEARCH ARTICLE

#### A CASE OF URINARY TRACT INFECTION CAUSED BY ACHROMOBACTER XYLOSOXIDANS IN AN IMMUNOCOMPETENT YOUNG MALE PATIENT

Dr. Karthick Raman<sup>1</sup> and Dr. Binu<sup>2</sup>

1. M.B.B.S.
2. M.B.B.S., M.D., (General Medicine).

#### Manuscript Info

##### Manuscript History

Received: 16 April 2024

Final Accepted: 21 May 2024

Published: June 2024

##### Key words:-

Achromobacter Xylosoxidans,  
Immunocompetent

#### Abstract

**Achromobacter xylosoxidans**, previously called as *Alcaligenes xylosoxidans* is an oxidase positive, motile bacilli found predominantly in polluted aquatic sources. Irrespective of the age group, it primarily causes opportunistic infection in certain conditions and hospital acquired infection in certain conditions. Being a rare causative agent, it has been notified to cause prosthetic valve endocarditis, peritonitis, skin and soft tissue infection, hepatobiliary infections, bacteremia<sup>(3)</sup>, otitis media<sup>(6)</sup>, pneumonia, urinary tract infections, meningitis and corneal ulcers particularly in immunosuppressed patients. Infection in an immunologically competent patient is quite rare and only limited studies are available regarding its prevalence. Urinary tract infection secondary to *Achromobacter xylosoxidans* as well as in an immunocompetent adult is quite uncommon. In our study, we dealt with a case of urinary tract infection<sup>(2)</sup> in an immunocompetent young male patient caused by *A. xylosoxidans*, who got admitted, treated with susceptible antibiotics, recovered and discharged back home with no specific complaints.

Copy Right, IJAR, 2024,. All rights reserved.

#### Introduction:-

##### Prologue:

*Achromobacter xylosoxidans* is a gram negative, aerobic, oxidase positive, non fermentive rod with low virulence. It belongs to *Alcaligenaceae* family and the *Burkholderiales* order. Yabuuchi and Ohyama first discovered this bacteria in the year 1971 in a patient with chronic purulent otitis media. Genus **Achromobacter** comprises of 19 species, out of these, till date only 15 species have been isolated from clinical specimen<sup>(14)</sup>.

It is an inhabitant of aquatic environment and is thought to cause infection mostly nosocomially in immunologically compromised patients and to be associated with a high mortality as well as fatality rate. Theory explains that immunocompromised patients are commonly affected than immunocompetent patients. Transmission of *Achromobacter xylosoxidans* occurs commonly through contact with contaminated liquids and they also enter the body from the skin during any medical intervention. **Invasive infection by this bacterium can lead to bacteraemia, with mortality rate ranging from 3% in adults to 80% in neonates.** It is known to cause secondary infection in immunologically suppressed patients, including those with malignancies<sup>(5)</sup>, cystic fibrosis<sup>(10)</sup>, hematological disorders, hypogammaglobulinemia<sup>(11)</sup>, PLHA (People living with HIV and AIDS) or particularly those who undergone organ replacement.

Corresponding Author:- Dr. Karthick Raman

Address:- M.B.B.S.

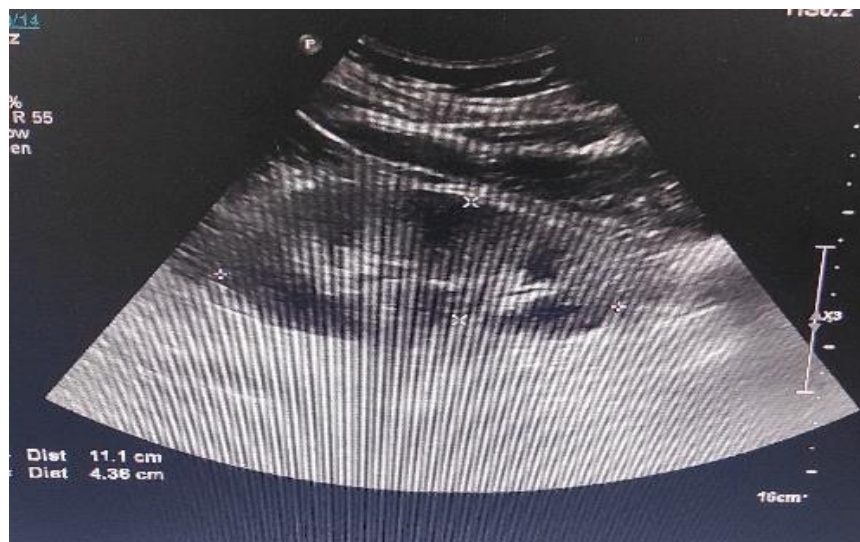
Urinary tract infection is one of the most prevalent diseases worldwide affecting people of all age groups. Urinary tract infections are caused by a wide range of pathogens, including Gram-negative and Gram-positive bacteria as well as fungi. Each year, about 150 million people are being suffered from urinary tract infection worldwide. Globally, Escherichia coli is the most common organism causing UTI accounts for majority of the cases. Urinary tract infection due to achromobacter xylooxidans is unusual but infection secondary to achromobacter xylooxidans may lead to sepsis, septic shock and even may progress to death. Infection occurs predominantly in elderly patients with urological abnormalities, immunosuppression and malignancies. Achromobacter xylooxidans has an intrinsic as well as acquired character of resistance, which makes it quite difficult to treat with particular antibiotics <sup>(12)(13)</sup>. In view of its high resistance, clinicians should be cautious regarding the treatment. In this study, we report a case of urinary tract infection <sup>(2)</sup> caused by achromobacter xylooxidans in an immunocompetent young male patient.

**Case Report:**

A 26-year-old male with no known comorbidities presented to the emergency department with a history of left sided low back ache for one day followed by fever, which was intermittent in nature with chills and rigor developed on next day morning. Patient visited a local clinic for his complaints of low back ache with no relief patient came here for further treatment, details of treatment not known. He had a history of bilateral renal calculi x 6 years back for which he got treated with analgesics and had a history of burning micturition x 3 month back got treated with antibiotics.

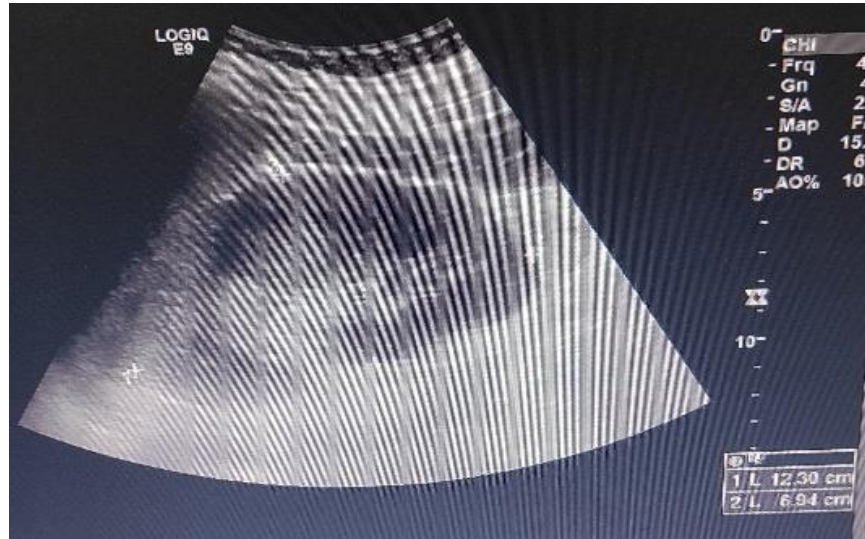
On admission, his Blood Pressure =110/60mm Hg, Pulse Rate =110 bpm, SPO2= 98% in RA, Respiratory rate = 20 cycles/min, Temperature = 103.7 F and Random blood sugar = 121mg/dl. Systemic examination of Cardiovascular system, respiratory and central nervous system were within normal limits, but abdominal examination revealed a left costovertebral angle tenderness. With a provisional diagnosis of Urinary tract infection, he was started on antibiotic **Injection Piperacillin &Tazobactam**. Relevant investigations done which showed a normal renal function test, urine routine, serum electrolytes, urine culture, liver function test. Complete blood count showed a raised White blood cell of 17,620 cells/mm<sup>3</sup> with normal rest of the values. X-ray chest Posteroanterior view and Electrocardiogram were within normal limits. On day 2 of admission, blood culture revealed an isolated organism named **ACHROMOBACTER XYLOSOXIDANS** and the sensitive antibiotic **INJECTION PIPERACILLIN & TAZOBACTUM** continued.

Clinical Diagnosis	Underlying illness	Specimen collected for culture	Species isolated	Antibiotic administered
Acute pyelonephritis	—	Blood	Achromobacter Xylooxidans	Piperacillin &Tazobactum
Acute pyelonephritis	—	Urine	—	—



On Day 2 of admission patient had 1 episode of vomiting with stable vitals except for a raised temperature of 100.8 F for which he was managed with antipyretic. C-reactive protein showed a mild rise of 26.715 mg/dl and his Procalcitonin was within normal range. Complete blood count has been done on the following days of admission which showed a decreasing trend of white blood cell count. Given the history of left sided costovertebral angle tenderness Ultrasound abdomen was done which showed an enlarged left kidney suggestive of pyelonephritis followed by contrast enhanced computed tomography of abdomen was done for further evaluation which showed features of bilateral acute pyelonephritis.

On day 3, 4 & 5 of admission patient did not have any other specific complaints except for a raised temperature. From day 6 of admission patient had no fever episode, appetite improved and till discharge day 10 patient did not have any particular complaint.



On follow up visit, one week later, patient had no definite complaints, Ultrasound abdomen was done which showed normal sized kidneys bilaterally.

### Discussion:-

*Achromobacter xylosoxidans* is a gram negative, oxidase and catalase positive, aerobic, motile bacterium with peritrichous flagella that inhabits mostly in aqueous environment. Review of individual case reports and articles accentuate that *achromobacter xylosoxidans* causes secondary infections commonly in immunosuppressed patients, including those with malignancy, cystic fibrosis, diabetes mellitus, and some immunosuppressive patients who are in lifelong immunosuppressive drugs for certain conditions eg. organ transplant<sup>(1)</sup> etc.

Only < 2% of cases were found to be affected by *A. xylosoxidans* in several large reviews. Skin lesions secondary to this bacterium accounts for a total of 20% of cases. Pneumonia and bacteremia in neonate's secondary to *A. xylosoxidans* has been associated with high case fatality rate. Catheter associated infections secondary to *A. xylosoxidans* were found to have lowest mortality rate.

Acute pyelonephritis is an inflammation of the kidney secondary to an infection. It generally occurs as a complication of ascending infection from the lower urinary tract system. *Escherichia coli* is by far the most common cause followed by *klebsiella pneumoniae* and *proteus, pseudomonas, enterococci, staphylococci* and other enterobacteria.

Unlike other gram negative bacilli, urinary tract is not a common site for *achromobacter xylosoxidans* to cause bacteremia. Prevalence of urinary tract infection in an immunocompromised patient secondary to *achromobacter xylosoxidans* and in an immunocompetent patient is obscure. Even though the pathogenesis of *achromobacter xylosoxidans* causing urinary tract infection is quite unclear, some studies suggest that it may be due to migration of the pathogenic bacteria from intestine to the ureter and bladder<sup>(1)</sup>. While it has been mentioned that

patients with urinary tract abnormalities<sup>(2)</sup> and those who are immunologically compromised are commonly affected by achromobacter xylosoxidans, the patient in this case had no such problems. The patient in this case had a positive blood culture to achromobacter xylosoxidans.

According to the records, treatment of most *Achromobacter xylosoxidans* is challenging due to its mechanism of resistance. In general, it is susceptible to third generation cephalosporin, sulfonamides, imipenem, broad spectrum penicillin, and trimethoprim-sulfamethoxazole<sup>(8)(9)</sup> and also resistant to all aminoglycosides, first and second-generation cephalosporin. In this case, it was sensitive to ofloxacin, imipenem, meropenem, levofloxacin, trimethoprim-sulfamethoxazole, piperacillin-tazobactam, cefepime/sulbactam, and resistant to gentamicin & amikacin showing similar results<sup>(8)(9)</sup>.

In summary, secondary infections caused by *A. xylosoxidans* is quite common in immunocompromised patients but rare in immunocompetent patients. Despite its rarity, however, we have witnessed such a case in an immunocompetent patient who was treated and discharged back successfully.

### Reference:-

1. **Lee JH, Lee SY, Park IY, Park SY, Lee JS, Kang G, Kim JS, Eom JS.** A Case of Septic Shock caused by *Achromobacter xylosoxidans* in an Immunocompetent Female Patient after Extracorporeal Shock Wave Lithotripsy for a Ureteral Stone. *Infect Chemother.* 2016 Mar;48(1):47-50. doi: 10.3947/ic.2016.48.1.47. Epub 2016 Mar 31. PMID: 27104016; PMCID: PMC4835435.
2. **Tena D, González-Praetorius A, Pérez-Balsalobre M, Sancho O, Bisquert J.** Urinary tract infection due to *Achromobacter xylosoxidans*: report of 9 cases. *Scand J Infect Dis.* 2008;40(2):84-7. DOI: 10.1080/00365540701558714 PMID: 17852927.
3. **Mandell WF, Garvey GJ, Neu HC.** *Achromobacter xylosoxidans* bacteremia. *Rev Infect Dis.* 1987;9:1001–1005. [PubMed].
4. **Chandrasekar, P.H., Arathoon, E., Levine, D.P. et al.** Infections due to *achromobacter xylosoxidans*. Case report and review of the literature. *Infection* **14**, 279–282 (1986). <https://doi.org/10.1007/BF01643962>
5. **Aisenberg G, Rolston KV, Safdar A.** Bacteremia caused by *Achromobacter* and *Alcaligenes* species in 46 patients with cancer (1989-2003) *Cancer.* 2004;101:2134–2140. [PubMed]
6. **Yabuuchi E, Oyama A.** *Achromobacter xylosoxidans* n. sp. from human ear discharge. *Jpn J Microbiol.* 1971;15:477481. [PubMed]
7. **Tena D, Carranza R, Barberá JR, Valdezate S, Garrancho JM, Arranz M, Sáez-Nieto JA.** Outbreak of long-term intravascular catheter-related bacteremia due to *Achromobacter xylosoxidans* subspecies *xylosoxidans* in a hemodialysis unit. *Eur J Clin Microbiol Infect Dis.* 2005;24:727–732. [PubMed]
8. **Vay CA, Almuzara MN, Rodríguez CH, Pugliese ML, Lorenzo Barba F, Mattera JC, Famiglietti AM.** 'In vitro' activity of different antimicrobial agents on Gram-negative nonfermentative bacilli, excluding *Pseudomonas aeruginosa* and *Acinetobacter* spp. *Rev Argent Microbiol.* 2005;37:34–45. [PubMed]
9. **Duggan JM, Goldstein SJ, Chenoweth CE, Kauffman CA, Bradley SF.** *Achromobacter xylosoxidans* bacteremia: report of four cases and review of the literature. *Clin Infect Dis.* 1996;23:569–576. [PubMed]
10. **Amoureux L, Bador J, Siebor E, Taillefumier N, Fanton A, Neuwirth C.** Epidemiology and resistance of *Achromobacter xylosoxidans* from cystic fibrosis patients in Dijon, Burgundy: first French data. *J Cystic Fibros.* 2013;12:170–176. [PubMed]
11. **Weitkamp JH, Tang YW, Haas DW, Midha NK, Crowe JE., Jr** Recurrent *Achromobacter xylosoxidans* bacteremia associated with persistent lymph node infection in a patient with hyper-immunoglobulin M syndrome. *Clin Infect Dis.* 2000;31:1183–1187. [PubMed].
12. **Gahrn-Hansen B, Siboni K.** Studies on ampicillin resistance in *Achromobacter xylosoxidans*: brief report. *APMIS.* 1988;96:185-187. PMID: [PubMed] [Google Scholar].
13. **Nicolosi D, Nicolosi VM, Cappellani A, Nicoletti G, Blandino G.** Antibiotic susceptibility profiles of uncommon bacterial species causing severe infections in Italy. *J Chemother.* 2009;21:253-260. PMID: [PubMed] [Google Scholar]
14. **Singh M, Raina D, Rohilla R, Narula H, Pandita A.** Antimicrobial Susceptibility Pattern and Prevalence of the Emerging Nosocomial Pathogen *Achromobacter xylosoxidans* in a North Indian Tertiary Care Hospital. *J Pure Appl Microbiol.* 2023;17(4):2149-2156. doi: 10.22207/JPAM.17.4.11

15. **Joan M. Duggan,\* Steven J. Goldstein,\* Carol E. Chenoweth, Carol A. Kauffman, and Suzanne F. Bradley.** *Achromobacter xylosoxidans* Bacteremia: Report of Four Cases and Review of the Literature.<https://academic.oup.com/cid/article-pdf/23/3/569/1000833/23-3-569.pdf>.