



Journal Homepage: - www.journalijar.com
**INTERNATIONAL JOURNAL OF
 ADVANCED RESEARCH (IJAR)**

Article DOI: 10.21474/IJAR01/4584
 DOI URL: <http://dx.doi.org/10.21474/IJAR01/4584>



RESEARCH ARTICLE

UNDIFFERENTIATED HIGH-GRADE PLEOMORPHIC SARCOMA OF THE PELVIS: CASE REPORT.

Abhishek Raghava KS.

Manuscript Info

Manuscript History

Received: 23 April 2017
 Final Accepted: 25 May 2017
 Published: June 2017

Key words:-

Pleomorphic sarcoma, pelvis, SMA

Abstract

High-grade spindle cell sarcomas are heterogenous group of tumours comprising of rare undifferentiated pleomorphic cancers. Malignant fibrous histiocytoma as a distinct entity is now considered controversial. Most of these tumors comprise of either a variable storiform and/or undifferentiated pleomorphic phenotype or one of four rarer additional types: myxoid, giant cell, inflammatory, and angiomatoid. We present an unusual case of a 55-year-old woman with complaints of lower abdominal pain. Pelvic imaging revealed heterogeneously enhancing right hemipelvic mass of size 12x7x8cm eroding the superior and inferior pubic rami, right acetabulum and right ischium. Ultrasound guided FNAC showed the features of high-grade undifferentiated pleomorphic sarcoma. Imaging of the thorax revealed lung metastasis. Patient was planned for palliative radiotherapy to pelvis in view of severe pain. In this report, we have described the clinical and pathological characteristics of this rare tumor. We have also discussed the various treatment options offered.

Copy Right, IJAR, 2017,. All rights reserved.

Introduction:-

Malignant fibrous histiocytoma (MFH), a pleomorphic sarcoma of uncertain origin, is the most common primary soft tissue sarcoma of late adult life.[1] They commonly arise in the extremities and the trunk although it can occur almost anywhere in the body. Undifferentiated high-grade pleomorphic sarcomas arising from pelvis are uncommon. Retroperitoneal sarcomas account for 15% of soft tissue sarcomas and 10% will present with metastasis. The existence of MFH as a distinct entity is now considered obsolete. Mostly, they were classified to be either a variable storiform and/or undifferentiated pleomorphic phenotype or one of four rarer additional types which include myxoid, angiomatoid, inflammatory, and giant cell.[2] Better prognostication has been achieved with reclassification of these tumors. They are associated with variable natural history, indicating the heterogeneity. Lung is the most common site affected with metastases constituting 90%, bone 8%, and liver 1%, with rare regional lymph node metastases.

Although the incidence of pleomorphic sarcoma of the pelvis is very low, it is highly malignant and is associated with a poor prognosis. We report a rare case of pleomorphic sarcoma of the pelvis and review the relevant literature regarding the clinical presentation, pathological features and outcome for pleomorphic sarcomas in this anatomic location. In addition, we have also reviewed the various therapeutic strategies for treating these unusual lesions.

Case presentation:-

A 55-year-old woman presented with complaints of lower abdominal pain and pain in the right hip joint associated with restriction in the movement of four months duration. No histories of unintentional weight loss, fevers, chills, or

hematuria were noted. She had family history of diabetes and hypertension. The haematological and biochemical tests were normal. Computerized tomography (CT) scan with and without intravenous contrast showed a heterogeneously enhancing mass of size 12 cm × 7 cm × 8 cm mass with necrosis, involving the adductor longus, brevis, magnus, pectineus, gracilis, obturator internus, externus and inferior aspects of iliopsoas muscles, eroding the superior and inferior pubic rami and acetabular margins of the right hip. The lesion was seen extending into the pelvic cavity, infiltrating the right lateral wall of the bladder and anteriorly, involving the right anterior abdominal wall muscles (fig 1,2). Few small deposits were noted in the right gluteal region. Thoracic imaging revealed multiple lung nodules which were randomly distributed and largest lesion of size 2.5cm x 2.2 cm was detected in the posterobasal segment of the left lung. Ultrasound-guided fine needle aspiration of the pelvic mass showed high-grade undifferentiated pleomorphic sarcoma. Magnetic resonance imaging (MRI) revealed irregular lobulated T1T2 heterogeneous hyperintense lesion noted involving right superior pubic ramus, acetabulum closely abutting the right lateral wall of bladder with focal loss of fat plane, involving right pectineus and proximal adductor muscles. Superiorly, fat plane with levator ani muscles was lost, laterally, extending into right gluteal region passing posterior to the neck of right femur, posteriorly, invading through right acetabular foramen (fig 3). Bone scan revealed increased osteoblastic activity involving the right acetabulum and ischium with no evidence of distal skeletal metastasis (fig 4). Biopsy from the ischium showed spindle cells exhibiting marked pleomorphism, round to oval with hyperchromatic nucleus and prominent nucleoli. Mitosis was as high as 6/10 high power fields. Areas of necrosis were there. Immunohistochemical analysis of the tumour cells yielded positive staining results for SMA and vimentin and negative for MyoD1, EMA, PanCK, HMB-45 and CD68 suggestive of a sarcoma. In view of the severe pain and restriction in the mobility of right hip joint, patient was planned for palliative RT (fig 5). She received 32.5Gy in 13 fractions at 250cGy per fraction. She completed palliative radiation without any complications. In view of poor performance status and patient refusal, palliative chemotherapy was deferred.

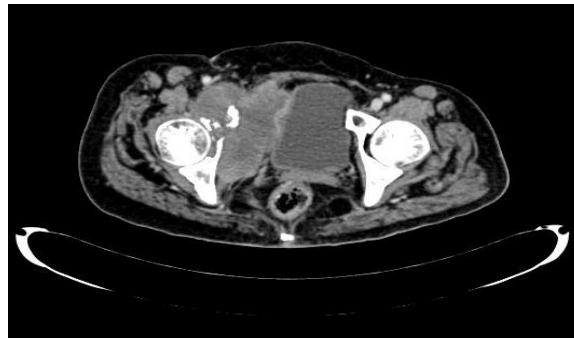


Figure 1:- CT showing the lesion eroding the right acetabulum and right lateral wall of bladder.

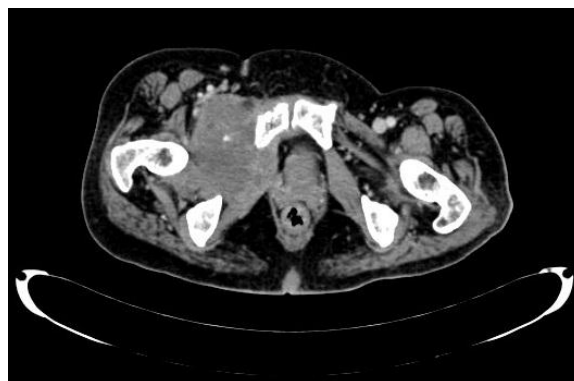

Figure 2:- CT showing the lesion eroding the pubic ramus.

Discussion:-

Soft tissue sarcomas constitute only 1% of all malignant neoplasms which are derived from cells of mesenchymal origin (nerve, fibrous, muscle, lymphatic and adipose origin). [3] Less than 50% of all retroperitoneal tumors comprises of sarcomas. It affects advanced age groups, though it can occur in any age groups and incidence is more in males and high-grade malignancy is seen in two-thirds of patients. [4,9] The gold standard for sarcoma diagnosis is constituted by the morphological diagnosis based on microscopic examination of histological sections.

Undifferentiated high-grade pleomorphic sarcoma also known as storiform-pleomorphic “MFH” is a rare disease of adults. Incidence peaks in the 6th and 7th decades of life. Both men and women are affected equally. Deep soft tissues of the extremities and trunk are the most common tissues involved. 5% of patients present with metastatic disease. Myxofibrosarcoma also known as myxoid “MFH” is the most common sarcoma of older adults, with a slight male predominance. Myxofibrosarcoma most commonly arises in subcutaneous and deep soft tissues of the extremities. It affects lower limbs and limb girdles more often than the upper limbs. In the current WHO classification, these undifferentiated sarcomas are classified into high-grade pleomorphic sarcoma, pleomorphic sarcoma with giant cells, and pleomorphic sarcoma with prominent inflammation [2,7]. Undifferentiated pleomorphic sarcoma with giant cells and undifferentiated pleomorphic sarcoma with prominent inflammation are extremely rare. Both genders are equally affected and they are more commonly seen in older individuals. The former affects distal extremities and trunk, while the latter affects mostly retroperitoneum or abdomen. Immunohistochemical staining for vimentin, smooth muscle actin (SMA), CD34, and CD68 may be positive but the expression of these markers is not specific to a particular lineage. Cellular staining for desmin may be positive, sometimes focally. Desmin positivity can be seen in cells with myofibroblastic differentiation. Myofibroblastic tumours must be distinguished from myogenic tumors, as myogenic tumours are associated with worse prognosis and higher metastatic rate. [5] Sarcomas include a small fraction of side population (SP) cells which are characterized by stem-like tumor-initiating potential. Undifferentiated pleomorphic sarcoma display activation of both the Hedgehog and Notch pathways. If these pathways are blocked, the proportion of SP cells is decreased, leading to suppressed tumor self-renewal. This finding is demonstrated by the inability of xenograft tumors subjected to pathway blockade to be serially transplanted to new hosts.[6] Diagnostic imaging is required to know the extent of the lesion and assesses the integrity and function of adjacent organs. Surgery is the main curative modality. Re-excision is recommended if margins involved or close. Surgery alone is adequate for superficial <5 cm tumours. Radiation therapy as an adjuvant treatment is recommended after complete resection for deep or >5 cm tumours, involved or close margins and as palliative treatment can be given to primary or metastatic foci. Adjuvant doxorubicin therapy is recommended to decrease the risk of recurrence and mortality in patients with high-grade lesions. The only agents that are constantly associated with response rates of more than 20% in metastatic setting when used alone are doxorubicin, epirubicin, and ifosfamide. Lungs are the most common sites affected with metastasis and can arise from any primary site or histology, but most commonly arise from tumours in the extremities.[8]

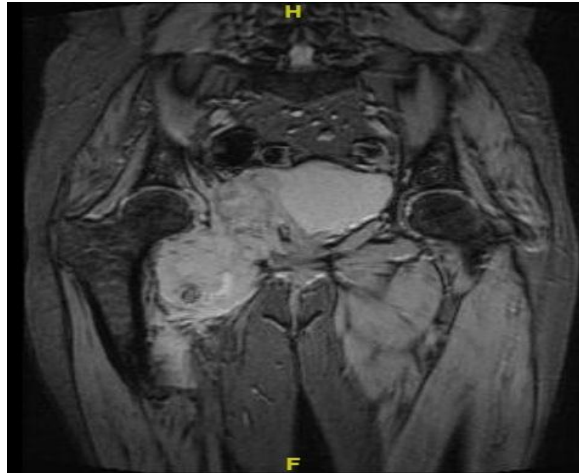


Figure 3:- MRI showing the lesion involving right lateral wall of bladder and adductor compartment of right thigh

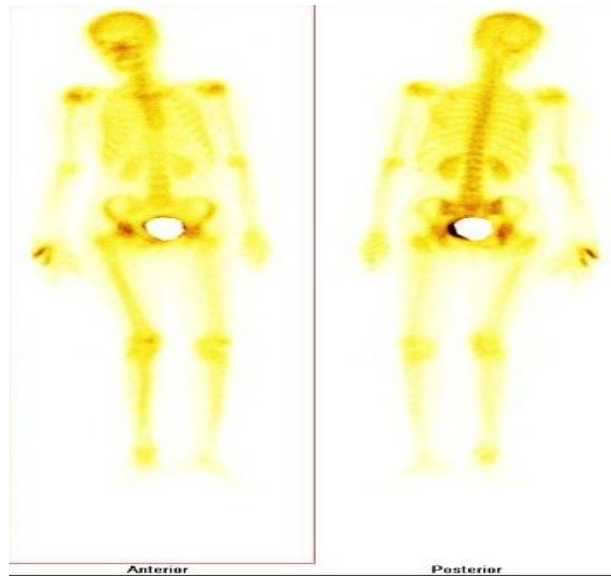


Figure 4:- Bone scan showing increased osteoblastic activity involving the right acetabulum and ischium.

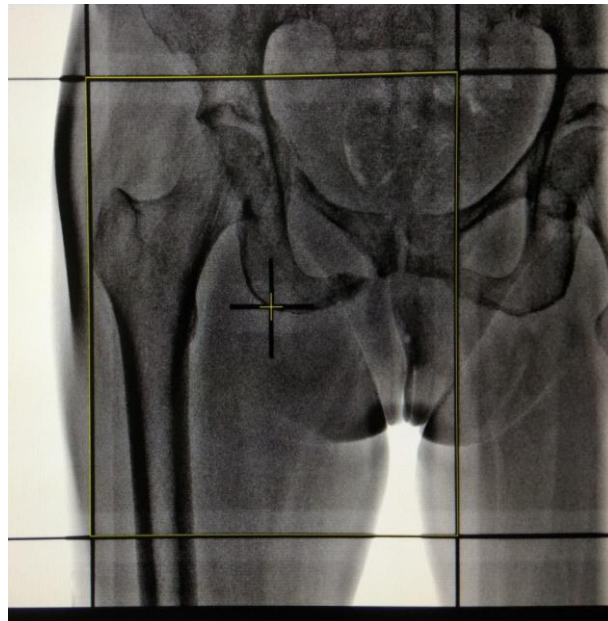


Figure 5:- RT planning fields AP/PA covering the disease with 1 cm margin.

Conclusion:-

Though extremely rare, undifferentiated high-grade pleomorphic sarcoma of the pelvis can present with lower abdominal pain and requires comprehensive radiological and pathological evaluation. Most of the patients who undergo surgery do not receive any adjuvant treatment, and adjuvant use of radiotherapy has been shown to improve local control without affecting survival.

Conflicts of interest:-

There are no conflicts of interest

Declaration:-

The authors received no financial support for their research.

References:-

1. Weiss SW, Enzinger FM. Malignant fibrous histiocytoma: an analysis of 200 cases. *Cancer* 1978;41:2250–66.
2. Nascimento AF, Raut CP: Diagnosis and management of pleomorphic sarcomas (so-called “MFH”) in adults, *J Surg Oncol* 2008;97:330-9.
3. Jemal A, Siegel R, Ward E, Hao Y, Xu J, Thun MJ. Cancer statistics, 2009. *CA Cancer J Clin* 2009;59:225-49.
4. Lewis JJ, Leung D, Woodruff JM, Brennan MF. Retroperitoneal soft-tissue sarcoma: Analysis of 500 patients treated and followed at a single institution. *Ann Surg* 1998;228:355-65.
5. Deyrup AT, Haydon RC, Huo D, et al.: Myoid differentiation and prognosis in adult pleomorphic sarcomas of the extremity: An analysis of 92 cases. *Cancer* 2003;98:805–13.
6. Wang CY, Wei Q, Han I, et al. Hedgehog and Notch signaling regulate self-renewal of undifferentiated pleomorphic sarcomas. *Cancer Res* 2012;72:1013–22.
7. Fletcher CD, Gustafson P, Rydholm A, et al. Clinicopathologic re-evaluation of 100 malignant fibrous histiocytomas: prognostic relevance of subclassification. *J Clin Oncol* 2001;19:3045–50.
8. Agafonoff S, Vaidya SK, DeFade B. High-grade undifferentiated pleomorphic sarcoma of the pelvis: A case report and review of literature. *Urol Ann* 2016;8:372-6.
9. Porter GA, Baxter NN, Pisters PW. Retroperitoneal sarcoma: A population-based analysis of epidemiology, surgery, and radiotherapy. *Cancer* 2006;106:1610-6.