



Journal Homepage: - [www.journalijar.com](http://www.journalijar.com)

## INTERNATIONAL JOURNAL OF ADVANCED RESEARCH (IJAR)

Article DOI: 10.21474/IJAR01/13189

DOI URL: <http://dx.doi.org/10.21474/IJAR01/13189>



### RESEARCH ARTICLE

#### ROLE OF A PEDODONTIST IN CLEFT LIP AND CLEFT PALATE REHABILITATION – AN OVERVIEW

Dr. Payel Basu<sup>1</sup>, Dr. Rani Somani<sup>2</sup>, Dr. Deepti Jawa<sup>3</sup>, Dr. Shipra Jaidka<sup>3</sup>, Dr. Tanushree Basu<sup>4</sup>, Dr. Muhamed Sabin A.P.<sup>1</sup>, Dr. Aiswarya Madhu<sup>1</sup> and Dr. Layeeque Ahmad<sup>1</sup>

1. Post Graduate Student, Department of Pediatric and Preventive Dentistry, Divya Jyoti College of Dental Sciences and Research, Uttar Pradesh, India.
2. Professor and Head of the Department, Department of Pediatric and Preventive Dentistry, Divya Jyoti College of Dental Sciences and Research, Uttar Pradesh, India.
3. Professor, Department of Pediatric and Preventive Dentistry, Divya Jyoti College of Dental Sciences and Research, Uttar Pradesh, India.
4. Bachelor of Dental Surgery, Sardar Patel Post Graduate Institute of Dental and Medical Sciences, Uttar Pradesh, India.

#### Manuscript Info

##### Manuscript History

Received: 20 May 2021

Final Accepted: 24 June 2021

Published: July 2021

##### Key words:-

Cleft lip, Cleft Palate, Comprehensive Management Of Cleft Lip And Cleft Palate, Interdisciplinary Team Care, Dental Treatment, Pediatric Dentist, Role Of A Pedodontist, Feeding Obturator, Naso Alveolar Molding

#### Abstract

Cleft lip and palate is one of the most common congenital anomalies requiring multidisciplinary care. Such anomaly is associated with many problems such as impaired feeding, defective speech, hearing difficulties, malocclusion, dental abnormalities, gross facial deformity as well severe psychological problems. Cleft of the lip and palate is one of the complex conditions that occur at a functionally potential area in the orofacial region and also at such a crucial time that strategic interventions at the right age by the concerned specialists becomes the need of the hour. Pediatric dentist is an integral part of the cleft rehabilitative process right from the neonatal period upto the phase of permanent dentition. Being well versed with a child's growth and development, both physical and mental, a Pedodontist helps in restoring function and esthetics in a cleft child, in a most empathetic way. This article describes the enormous challenges faced by these innocent souls and the vital role played by a Pedodontist, to provide comprehensive cleft care, be it preventive, restorative, or interventional care, in order to achieve the best possible outcome and meaningfully improve their quality of life.

Copy Right, IJAR, 2021.. All rights reserved.

#### Introduction:-

Craniofacial Amomalies (CFAs), specially clefts, are one of the most common head & neck birth defects worldwide, affecting children of all socioeconomic & cultural backgrounds. Oro-Facial clefts (OFC) are among the most common CFAs worldwide, occurring in approximately 1 in every 700 to 1000 live births (WHO, 2002, 2005).<sup>1</sup> Cleft lip (CL), Cleft lip and palate (CLP), & isolated cleft palate (CP), are collectively termed as Oro-Facial clefts (OFCs). In 2008, the **World Health Organisation (WHO)** have included Cleft lip and palate in the **Global Burden of Diseases (GBD 2016)** initiative to be perceived as a life threatening congenital deformity.<sup>2</sup> In India, estimated live births per year have been 24.5 million out of which birth prevalence of clefts is somewhere between 27,000 to 33,000 per year.<sup>3</sup> On average, every two minutes, a child with cleft is born in the world, around 660 children daily

**Corresponding Author:- Dr. Payel Basu**

Address:- Post Graduate Student, Department of Pediatric and Preventive Dentistry, Divya Jyoti College of dental Science and Research, Uttar Pradesh, India.

and 2.35 thousand new cases of fissures seen annually, and with the growth in world population, around 3,200 new cases of CLP is expected per year. Patient with OFC deformity needs to be treated at right time & right age to achieve functional & esthetic wellbeing.<sup>4</sup> The treatment process is complex & challenging for the treating specialists. It is initiated even before birth & continues up to adulthood. Early identification & early intervention programmes are the most effective tools to counter the long-term detrimental effects of the existing dento-skeletal imbalance & facial asymmetry in these patients.

### Etiology

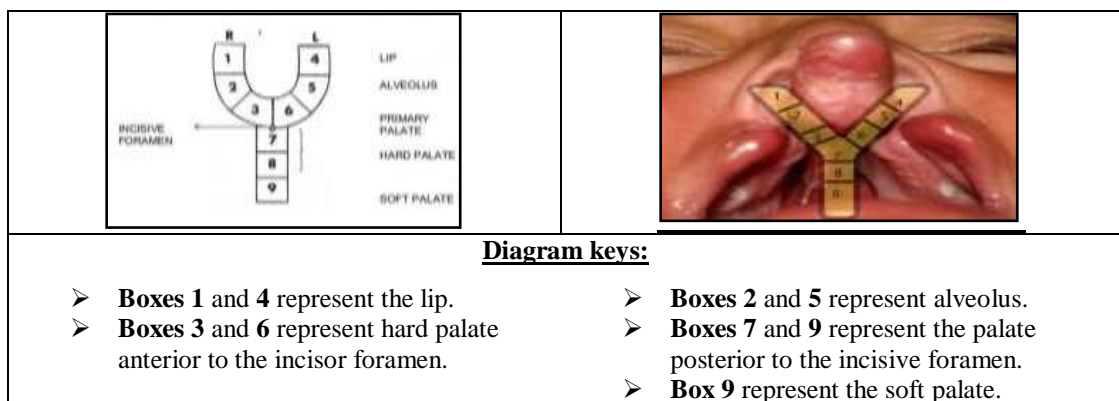
Orofacial cleft may be manifested as one part of a larger syndrome such as Pierre Robin Syndrome/Sequence or a non- syndromic variant.<sup>6</sup> Both environmental & genetic factors have been implicated as causes. In addition, infections during pregnancy and parental age might play a vital role in etiology of CLCP. It has been suggested that a lack of certain vitamins, folic acid deficiency, or maternal exposure to tobacco smoke, alcohol consumption and certain medications during pregnancy may raise the risk of the child being born with a cleft (CDC, 2014).

### Embryology

A Cleft is a space or opening made by a cleavage or a split or a division. Cleft lip & cleft palate are congenital anomalies that occur due to incomplete fusion of the bones in the facial skeleton during first 3 months of pregnancy. Primary palate fusion is usually completed during the 4th to 8th week into pregnancy, if not then cleft of lip occurs while the secondary palate is formed during 8th to 12th week, failing to which leads to cleft of palate.<sup>7</sup> Additionally, the female palate is known to close 1 week later than the male palate, increasing the risk of cleft palate formation, and is a current hypothesis for the higher frequency of cleft palate in females.

### Classification

Cleft lip and palate are classified for grading the severity of condition which will help in communication, diagnosis and treatment planning.<sup>8,9</sup> **Davis and Ritchie (1922)** divided congenital clefts morphologically into three groups- Prealveolar (process) cleft, Postalveolar (process) cleft and Alveolar (process) cleft. Whereas **Kernahan & Stark (1958)** classified it on embryological basis into- Clefts of primary palate, Cleft of secondary palate and combination clefts. **Karnahan (1971)** subsequently proposed a modified version known as striped Y classification (*Fig 1.a,b*). It is a schematic representation considering incisive foramen as the reference point. **Victor Veau (1931)**, also known as the father of modern surgery of cleft lip and palate, also contributed significantly. He classified cleft palate into- Cleft of the soft palate only, Cleft of the hard and soft palate, Complete unilateral cleft (UCLP) and Complete bilateral cleft (BCLP).



**Fig. 1:-** The Symbolic representation of Kernahan's Stripped Y Classification;

### Prenatal cleft diagnosis

Prenatal diagnosis of cleft gives parents the advantage of having time to prepare psychologically for the birth. It helps the family to become knowledgeable about the birth defect and get sufficiently educated regarding specialized cleft management. Cleft lip can be easily diagnosed by performing ultrasonography in the second trimester.<sup>10</sup> It is very difficult to make diagnosis of cleft palate antenatally unless associated with a large cleft lip. Recently, fetal MRI has been used to detect fetal abnormalities, but it's use is still limited. Prenatal diagnosis also provides scope for Genetic counseling which offers valuable information regarding any family history or if there is a future possibility of another cleft child.

### Problems associated with cleft

A patient with a cleft, unfortunately, is faced with a multitude of both anatomic & physiologic problems including feeding, speech, hearing, appearance, dentition & quality of life.<sup>11</sup> They are also reported to have significant behavioural and emotional problems resulting in reduced social competence, impulsive behavior, learning or cognitive disabilities. The chief complaints of these patients are mainly deformed face, inability to feed, and nasal regurgitation of fluids.<sup>12</sup> Because of deformity of the face, these patients are often seen as an object of ignorance and are often separated from their normal counterparts in society. It may result in lifelong psychological trauma. Hearing defects are very frequently observed due to disorder of the middle ear. Speech problems are observed along with velopharyngeal insufficiency, hypernasal voice and difficulty in articulation. Moreover, early palate repair results in retarded maxillary growth due to surgical trauma to growth centres and periosteum. Early closure cases might lead to decreased antero-posterior maxillary dimension or even severe malocclusion to dentofacial deformity. Patients with complete cleft lip & palate exhibit a more normal dental arch when palate is operated at a later stage ie, after growth phase, than those operated in infancy. Maxillary collapse & failure of midface growth could be eliminated if surgical closure of palate is postponed until 4 years of age. But there are certain drawbacks like delay in repair resulting in speech defect, articulation & hearing problems. Thus the best balanced results are obtained by repairing between one & a half years of age. Sometimes they are also faced with difficulty in breathing while sleeping known as Sleep apnoea.<sup>13</sup> The Dental problems mainly include congenitally missing teeth, anodontia or hypodontia, neonatal teeth, ectopic eruption, supernumerary teeth, anomalies of tooth size and shape, delayed eruption, ankylosis, micro- and macro- dontia, fused teeth, enamel hypoplasia, difficult oral hygiene maintainance, high risk of caries and gingivitis, deep bite, crossbite and crowding or spacing of teeth.<sup>14,15</sup>

### Management of Cleft Lip and Cleft Palate

It is very distressing for the parents, once their child is born with a cleft. The psychological and social implications of this congenital deformity could be severe and their management becomes a major responsibility for the healthcare system.<sup>16</sup> The main goal is to restore esthetics and functional impairments associated with cleft. The overall management is challenging & dictates the need for multiple disciplines, to work in unison with their skill & expertise to provide optimal care for the patient. Comprehensive cleft care has two parts- Non-surgical and Surgical therapy.<sup>16,17,18,19,20,21,22,23,24</sup> (Fig.2)

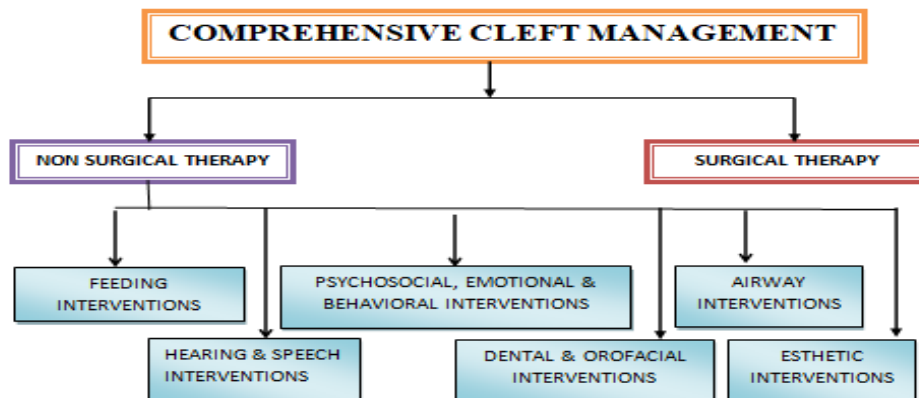


Fig.2:- Comprehensive cleft management.

The American Cleft Palate- Craniofacial Association (ACPA)<sup>25,26</sup> & Cleft Palate Foundation (CPF) recognized by WHO, the American Academy of Pediatrics (AAP)<sup>27</sup> and American Academy of Pediatric Dentistry (AAPD)<sup>28</sup> provide guidelines & standards for cleft related & craniofacial care. The ACPA promotes a interdisciplinary team approach to bring about a complete rehabilitation thus ensuring these children would live a normal life. These teams are composed of qualified health professionals from medical, surgical, dental, and allied health fields working together in a coordinated system. The essential services are mainly provided by the patient care coordinator, pediatrician, plastic surgeon, general surgeon, oral surgeon, pedodontist, orthodontist, prosthodontist, ENT surgeon, neurologist, speech therapist, psychologist, parents, genetic counselor, audiologist, nurse and social worker.<sup>29</sup> (Fig. 3)

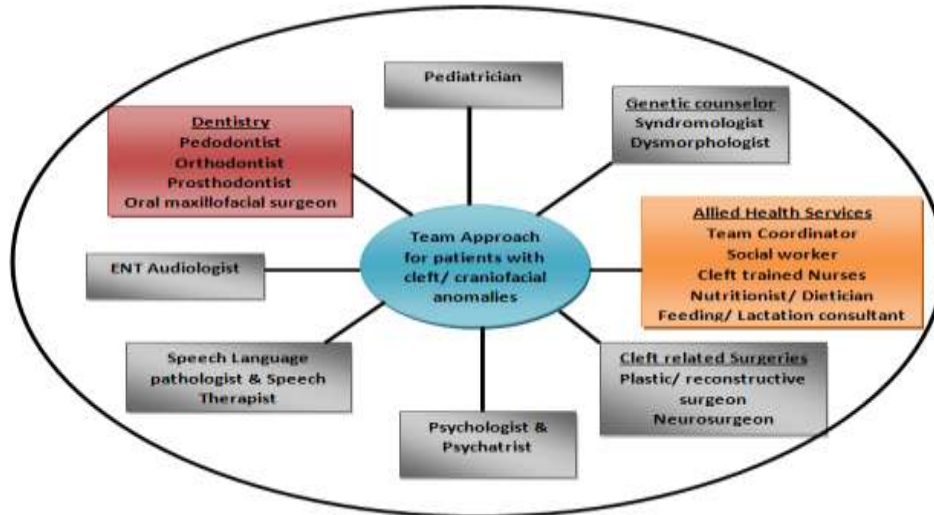


Fig. 3:-Interdisciplinary cleft care team

#### Role of a Pedodontist:-

Patients with craniofacial anomalies require dental care throughout life as integral part of total rehabilitation process. A dedicated pediatric dentist is best suited to provide the often complex dental care necessary for these patients. Among the members of the team, a pedodontist is a specialized dentist with advanced training to help children with general & special dental problems. They are responsible for overall oro-dental care of the child. It has been reported worldwide that 92% of the programs included the pediatric dentist in the multidisciplinary cleft palate team with the role extending from preventive, restorative to infant orthopedics. The role of pedodontist starts from neonatal period right up to permanent dentition phase. The pediatric dentist facilitates the integration of oral hygiene and dental preventive regimens into the treatment protocol for cleft children to establish desirable habits and oral health before the provision of advanced reparative surgery and complex dental treatment.

For any individual with a craniofacial difference, an early consultation with a pediatric dentist has been highly recommended. The AAPD suggests that for infants with a cleft, the first dental visit should occur usually right after birth to provide optimal dental care. A pediatric dentist is usually the first dental specialist with whom the parents will encounter. A pedodontist usually discusses the traditional dental problems associated with clefts with parents and also guides regarding proper timing of specialist referral. In addition, a pedodontist interacts with the patient & family on a regular basis that allows input to the cleft team regarding changes in the patient's behavior, sleep, academic performance & social interactions. A Pedodontist's active participation in the interdisciplinary cleft team is very important as a specialist being trained in every aspect of a child from physiology to psychology.<sup>30,31,32,33,34,35,36,37,38</sup>

#### Sequence of pediatric dental treatment

For convenience, Pediatric dental treatment for a cleft child is divided into four stages, corresponding to the dental developmental stages along with craniofacial growth.<sup>35,39,40,41,42</sup> (Fig. 4)

1. Stage I: Initial management (birth to 2<sup>1</sup>/<sub>2</sub> years of age)
2. Stage II: Primary dentition(2<sup>1</sup>/<sub>2</sub> to 6 years of age)
3. Stage III: Mixed dentition (6 to 12 years of age)
4. Stage IV Permanent dentition (12 years of age to the late teen years)



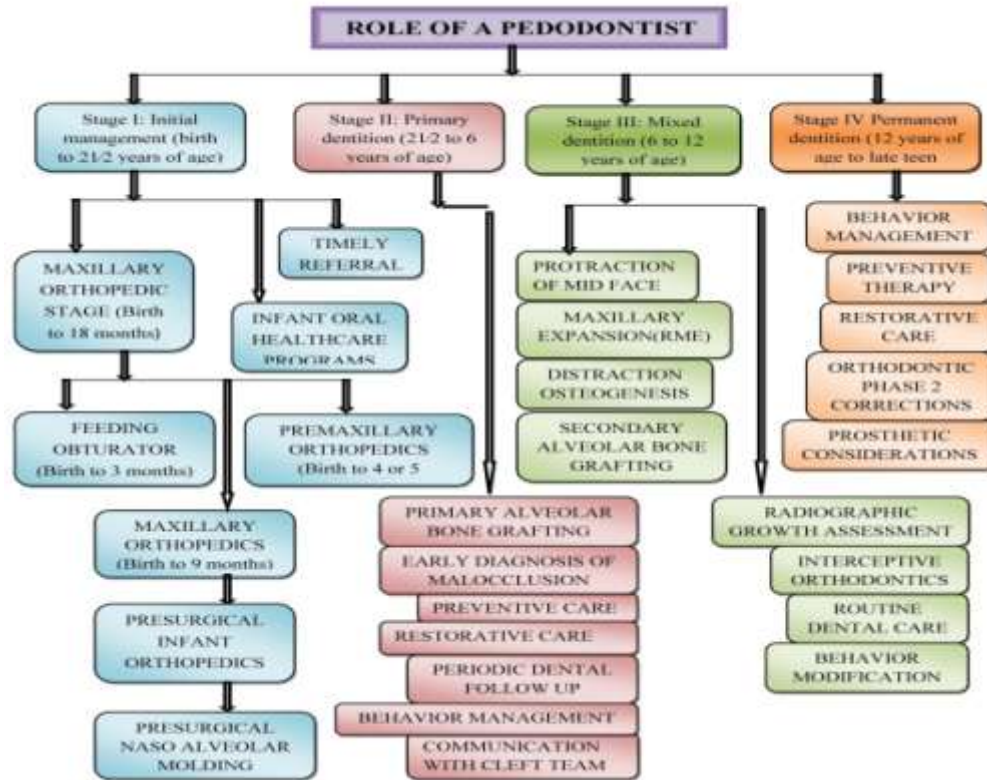


Fig. 4:-Flowchart depicting Role of a Pedodontist

### Stage I: Initial Management:- (Maxillary orthopedic stage: Birth to 18 months)

#### Management of Neonate

Immediately after the child is born with a cleft, the mother becomes highly anxious due to the difficulties faced during the process of feeding the neonate. In addition, neonatal respiratory obstruction is seen which is attributed to a very small and posteriorly displaced mandible. All these make it difficult for the infant to maintain adequate nutrition, which may even lead to failure to thrive. The current management protocol involves reparative surgery within the 12 months of life. But there is a direct relationship between decreased body weight and complications in surgery which therefore necessitates early interventions through conservative means, aimed at decreasing these complications that might arise due to inadequate feeding.<sup>43</sup>

#### Feeding Obturator Therapy

Obturator is a prosthesis used to close a congenital or acquired tissue opening primarily of the hard palate and/or contiguous alveolar & soft tissue structures. **Ambroise** was the first one who used obturator as artificial means to close a palatal defect as early as 1500 AD. A feeding obturator is a prosthetic aid that is designed to obturate the cleft & help a cleft child to eat properly. It creates an artificial palate, against which the infant can press the nipple and suckle milk. It helps to create an intraoral negative pressure thus helping in swallowing. It provides a rigid platform thereby preventing the tongue from entering the defect and interfering with spontaneous growth of the palatal shelves. It separates the oral & nasal cavities, hence reduces nasal regurgitation and incidence of choking. Obturators are believed to improve infant feeding, growth & nutrition and also contributes to the development of the jaws and speech. Furthermore, an obturator also provides maxillary cross-arch stability and prevents arch collapse after definitive lip surgery, thus help in achieving a better functional and esthetic outcome. A study by **Jones et al (2003)** reported that, maxillary obturators constructed to facilitate feeding for infants with UCLP & BCLP, lead to reduced nasal discharge, reduced the time required and difficulty experienced by the parents while feeding their infants.<sup>3,44,45,46</sup>

### Steps in fabricating a Feeding Obturator

1. This is ideally accomplished as soon after birth as possible. Before making any impression, the palate as well as inner walls of cleft is painted with petroleum jelly & the cleft defect blocked with a clean soft gauge piece to prevent lodgement of impression material into defect area.
2. For diagnostic impression, a softened wax sheet is adapted intraorally on infant's maxillary arch using thumb and index finger. A stone model is poured to fabricate a modified stock tray with handle which is used to obtain primary impression. Cast is poured & a custom acrylic tray is fabricated.
3. During impression process, infant is held either upright or with face down towards floor to prevent aspiration of excess material which eventually might cause vomiting & asphyxia. It is noted that infant should be crying during impression making, thus maintaining a patent airway continuously throughout the procedure. Appropriate emergency equipments including forced oxygen, suction, standard airway management equipment should be available nearby. Sucking motions made by the infant during impression making helps to obtain better moldability. Final impression is preferably made with a putty material. The master cast should exhibit good anatomic detail of entire maxillary arch. Excessive undercuts are blocked with modeling dough or wax. (Case report 1, Fig. 5.a-e)<sup>40</sup>
4. A separator or tin foil substitute is applied over the entire surface of the maxillary model and left to dry. A mixture of soft, acrylic resin is poured into the cleft area to the level of the palate. This provides retention for the prosthesis. The model is placed in a warm, moist environment to cure for 20 minutes. Remaining acrylic resin is added to the palate area using "salt and pepper" method, ensuring it extends well into the mucobuccal fold area. The appliance is removed from the model, & the wax & modeling dough rinsed off with hot water, then trimmed & polished.
5. After the obturator has been fitted, parents need to take care of this appliance. After each feed, the plate should be removed and cleaned with running water and soaked once a day for 20 minutes in chlorhexidine solution. Infants are recalled at 2 days interval for appliance adjustments & monthly follow ups scheduled. In most cases, the feeding plate obturator appliance serve until the time of initial lip repair at approximately 3 months age.

### Case Report 1: Multidisciplinary Team Approach to Cleft Lip and Palate Management (by McDonald R, Avery D, Dean J. St. Louis, 2004).<sup>40</sup>

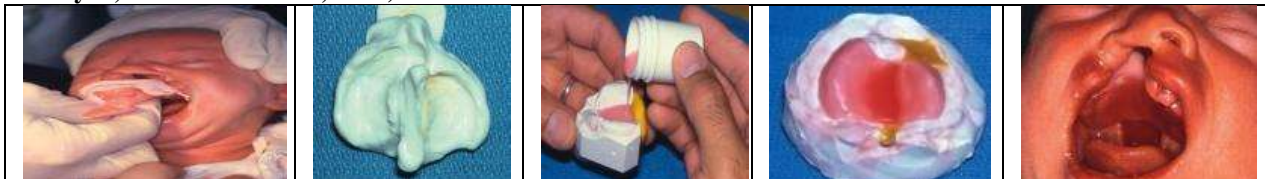

Fig. 5a-e) :-Feeding obturator fabrication with acrylic resin for a UCLP patient

### Case Report 2: Feeding obturator appliance for an infant with cleft lip and palate. (by Chandna P et al; 2011)<sup>47</sup> (Fig. 6. a-h)

Impression of the maxillary arch was made with polyvinyl siloxane putty material, used because of its high viscosity reducing the danger of aspiration as well as relatively satisfactory duplication of finer details. Impression was poured with Type V dental stone. Undercuts blocked with wax. The vacuum tray was fabricated in a vacuum former machine using a low-density polyethylene sheet & tightly adapted to the cast. The tray was then trimmed to remove excess material. Here a vacuum tray was chosen over an acrylic obturator because of its added advantages of being light weight, moldable, good fit to palate and decreased possibility of soft tissue injury due to its soft texture. Following this an 8-inch floss was attached to the feeding obturator to provide a safety mechanism in case of gagging or accidental slippage and swallowing. The appliance was positioned in the patient's mouth and parents were instructed about its placement, removal and cleaning. Thereafter, the mother was asked to feed the infant. It was seen that the child was successfully able to feed with the feeding obturator appliance in place.

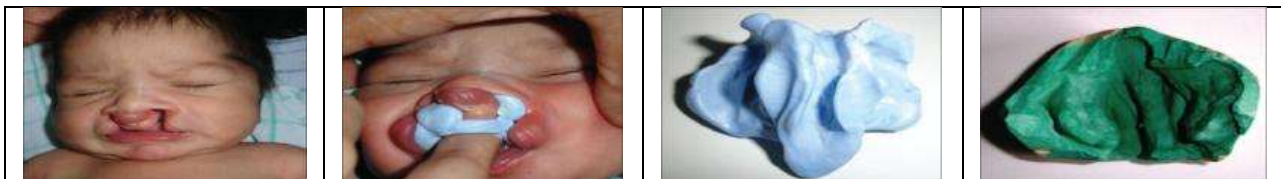

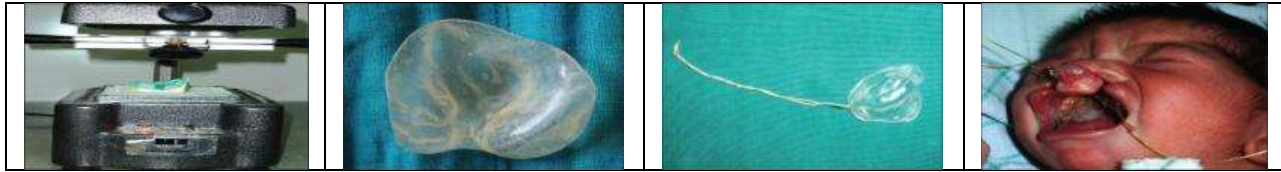


Fig. 6(a-h) :-Feeding obturator appliance for a BCLP patient made with low-density polyethylene sheet fabricated in a vacuum former machine.

**Case Report 3: A feeding appliance for a newborn baby with cleft lip and palate (by Abhay Agarwal et al, 2010.<sup>48</sup> (Fig 7. a-g)**

Due to lack of retention, occasionally a stainless steel wire is incorporated in the acrylic plate & extended bilaterally following the cheek contour for the purpose of extraoral retention. These wings can be stabilized against the cheeks using adhesive tape.

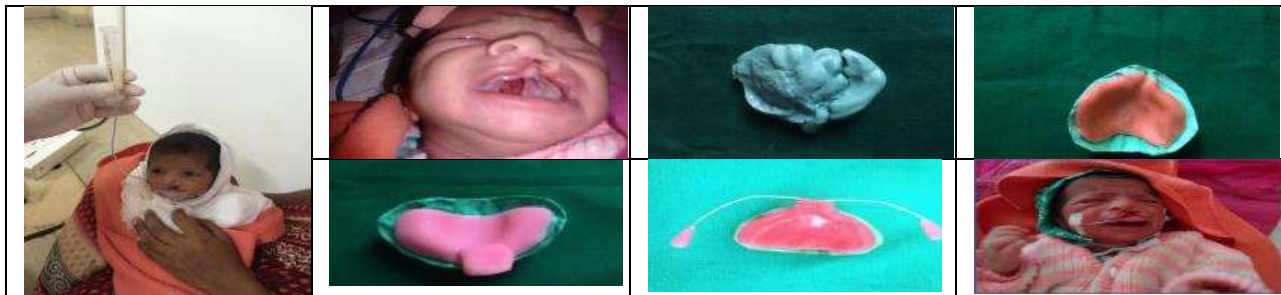

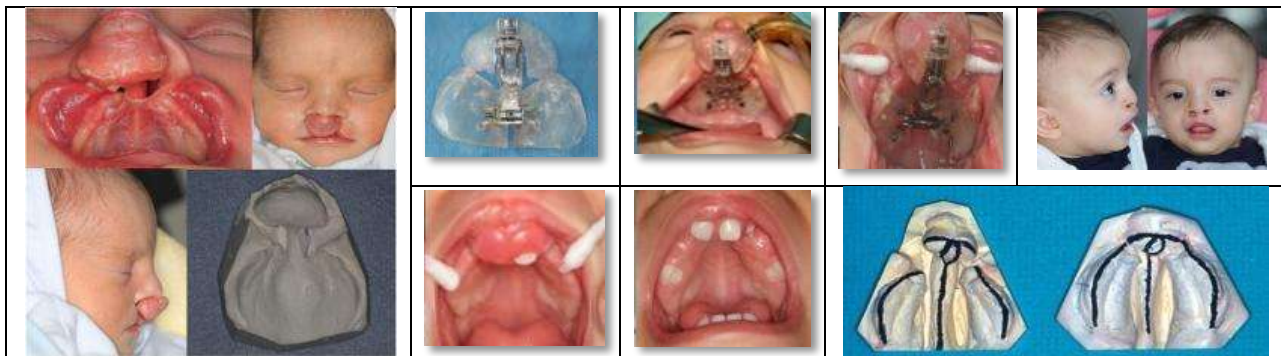Fig. 7(a-g):- Feeding Plate with extension wings retained with extraoral adhesive tapes

**Premaxillary Orthopedic Therapy (Birth to 4 or 5 months)**

In some cases of Bilateral clefts, the infant has a premaxillary segment positioned severely anterior to the lateral maxillary arch segments, or deviated laterally to one side of the cleft defect (Fig. 8,9). This presents a difficult clinical challenge for the surgeon before surgical closure of the lip. If lip surgery is undertaken with the premaxilla in such an abnormally forward position, the chances of lip dehiscence are increased. In this aspect, **Hofman**, as early as **1686**, described use of a head cap & premaxillary strap to reposition premaxilla.<sup>26</sup> This type of apparatus is useful for both anteroposterior as well as vertical repositioning. Presently, premaxilla is retracted by an elastic chain & lateral alveolar segments expanded with activated expansion device. Patient is recalled weekly for 4 to 7 weeks for activation of the elastic chain. The appliance is removed at the time of patient’s primary surgical lip repair, which is approximately 6 months of age.

**Case Report 4: A New Technique for Retracting the Protrusive Premaxilla With Fewer Patient Visits (by Eruz et al. 2018)<sup>49</sup> ( Fig .8. a- h)**

In this, an anteriorly positioned maxilla and laterally displaced premaxilla is shown. Immediately on being reported (within 2 weeks of birth), an impression of infant’s maxillary arch has been made for fabricating intraoral obturator. After delivery of obturator, infant is allowed to get accustomed with it for 1 week. At second appointment, infant is fitted with a premaxillary retraction (active) appliance.

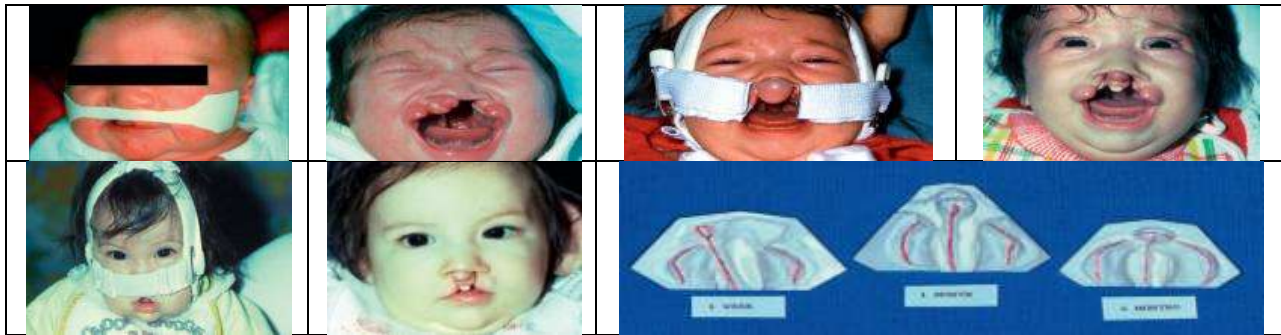



**Fig. 8(a-h):-**Premaxillary orthopedics performed in cleft patient, depicting appreciable changes in the alignment of protruding premaxilla.

**Case Report 5: Three dimensional premaxillary orthopedic technique for improved position and symmetry prior to cheiloplasty in bilateral cleft lip and palate patients, by Jones JE, et al. 1985)<sup>40</sup> (Fig 9. a- g)**

A **bonnet-and-strap appliance** is usually made to provide “headgear” anchorage for premaxillary retraction. The desired movement could usually be accomplished within 6 to 8 weeks. In many cases a soft, elastic tape (**Microfoam Tape**) could be useful for retraction in a simpler manner than with bonnet retraction system. The advantage being ease of fabrication, however, it did not afford same control of force, hence could not be used in all instances. In this case report, a laterally protruded premaxilla in an BCLP infant has been presented, where premaxilla must be positioned in facial midline before retraction because a straight extraoral force would not do that. Moreover, this also decrease the risk of distorting a vomer stalk and waive off the need for a surgical premaxillary setback, a procedure associated with possible growth attenuation and other complications. Optimum premaxillary positioning may even eliminate need for a staged lip closure (lip adhesions before definitive lip surgery) thereby decreasing total hospital time and cost. The appearance of nose and lip is usually improved because lip could be repaired under less tension as alveolar segments are already aligned symmetrically. Here, primarily an external acrylic “bulb” prosthesis has been planned. The appliance was fitted over laterally protruding premaxilla & anchored to infant’s head with a **bonnet appliance**. By application of sequentially increasing differential forces with elastic straps attached to bulb prosthesis, premaxilla was brought into facial midline in 3 to 4 weeks with the appliance in place for 24 hours a day and removed only for feeding. Following this, bulb appliance was replaced by single elastic straptherapy to improve anteroposterior relationship before definitive lip closure. Over next 1 to 2 months, equal pressure was applied on the still protruding premaxilla, to retroposition it into a more normal position between the lateral segments. Premaxillary segment at completion of straptherapy could be seen in *Fig.9*. Sequential models at 1 week (initial presentation), 1 month (completion of bulb therapy), and 4 months (completion of strap therapy) have also been shown.



**Fig. 9(a-g):-**Premaxillary retraction (mild) using Microfoam Tape; Better alignment accomplished with premaxillary orthopedic therapy before definitive lip repair for a BCLP patient

### Maxillary Orthopedic Therapy (Birth to 9 months)

#### Presurgical Infant Orthopedics (PSIO)

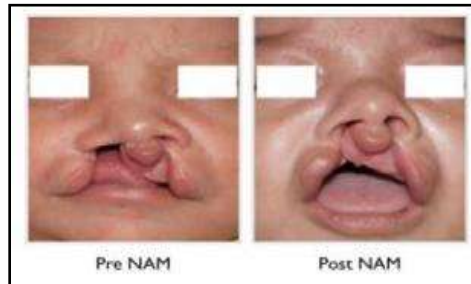
Infant orthopedics is done in patients with a very wide cleft gap, during the first 18 months which is a period of most intensive growth. Various appliances have been developed to help reposition the cleft segments and modify the defect before initial lip repair & assist in obtaining a better surgical outcome. This concept was introduced at University of Glasgow by **Kerr McNeil** in 1954 as an adjunctive neonatal therapy aiming at nonsurgical reduction of alveolar cleft size. The rationale behind “**Maxillary Orthopedics**” as described by **McNeil, Burston & Rosenstein** is ‘early segment alignment allowing the maxillary halves to develop normally even though normal bony union is not present’. The primary purpose of the appliance prior to lip closure is not to proliferate tissue or initiate growth but to guide the maxillary segments into proper spatial position with each other & with the mandibular arch.<sup>50,51</sup> In some cases, a PSIO appliance could be additionally used as a feeding plate for cleft infants.

#### Presurgical Naso Alveolar Molding (PNAM)

Multiple PSIO techniques exist, among which presurgical nasoalveolar molding (PNAM) therapy is provided by the pediatric dentist. The first PNAM appliance was designed by **Grayson et al. (1999)**. Nasoalveolar molding is a nonsurgical method of reshaping the gums, lip, and nostrils before definitive lip & nose repair, thus reducing the



severity of cleft. Before introduction of this concept, repair of a large cleft gap required multiple surgeries between birth & 18 years of age, putting the child at risk for various complications. With advent of PNAM, all these could be reduced. Surgery is performed only after the molding is complete, approximately 3–6 months after birth. Fig. 10 shows picture of a child before and after PNAM therapy.<sup>52,53,54,55,56</sup>



**Fig. 10:-**Reduction of cleft size after Naso alveolar molding

### Objectives of PNAM therapy

1. Reduction of cleft size by guiding growth and functional rehabilitation
2. Restore physiologic continuity of the dental arch to maintain oral and dental health
3. Achieve an optimal alignment of cleft segments within first few months of infancy before lip surgery
4. To allow a surgical repair with minimal tension and reduced scar formation.
5. To reduce the protrusive position of the alveolar process (premaxilla)
6. Prevent tongue from seating into cleft region, thus facilitating transverse growth of palatal shelves
7. To actively mold and reposition the deformed nasal cartilages
8. To lengthen the deficient columella and correct the alar cartilage displacement
9. To reduce the need for secondary alveolar bone grafting.

### Rationale of PNAM Therapy

- There is high degree of plasticity in neonatal cartilage due to high levels of **hyaluronic acid**. Hyaluronic acid level increases with increase in estrogen level. Immediately after birth, neonatal level of maternal estrogen is highest. Therefore first 2-3 months after birth is the ideal period for active cartilage soft tissue moulding. The increase in levels of hyaluronic acid in the fetal circulation continues for about 6 weeks after birth, after which the estrogen levels starts dropping down. This Hyaluronic acid has the ability to alter the elasticity of the cartilage, ligament & connective tissue by breaking down intercellular matrix (**Matsuo, 1988**).

- According to *Chondral Modeling hypothesis* by **Hamrick (1999)**, active moulding of nasal cartilage stimulates immature nasal chondroblasts, producing an interstitial expansion, thereby improving nasal morphology. PNAM takes advantage of flexibility of cartilaginous septum in first few weeks of birth, as it is favourable for active molding & repositioning of nasal cartilages.

- During this time it is relatively easy to apply external traction by means of controlled forces to rotate the lower part of the premaxilla to a more surgically advantageous position & to produce a normal dental arch alignment by approximating the alveolar cleft. Prognosis of PNAM procedure is highly dependant on the age at which it is started & patient compliance. Thus, the favourable time to start PNAM procedure is immediately after birth & if started beyond first six weeks, outcome may not be very appreciable.

### Principle of PNAM Therapy

PNAM works on principle of “**Negative sculpturing**” & “**Passive molding**” of alveolus & adjacent soft tissue. (Fig. 11. a-f) As pressure is exerted on the anterior segments of the maxilla by the repaired lip, orthopedic molding of the segments can be achieved. In unilateral cases, the force applied to the greater segment by the intact lip molds that segment around to approximate the lesser segment. This molding is facilitated by the obturator or NAM plate, which provides a fulcrum around which the anterior portion of the greater segment rotates. At the same time the appliance resists any tendency for the greater and lesser segments to collapse toward the midline.<sup>57,58</sup>

### Passive molding

A custom made molding plate of acrylic used to gently redirect the growth of the alveolus to get the desired results later on.

### Negative sculpturing

Serial modifications made to the internal surfaces of the molding appliance with addition or deletion of material in certain areas to get desired shape of the alveolus, and nose.

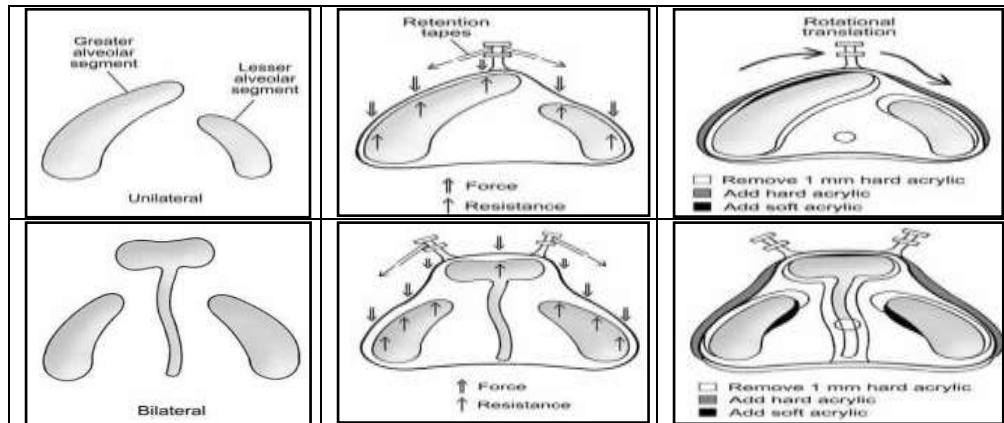
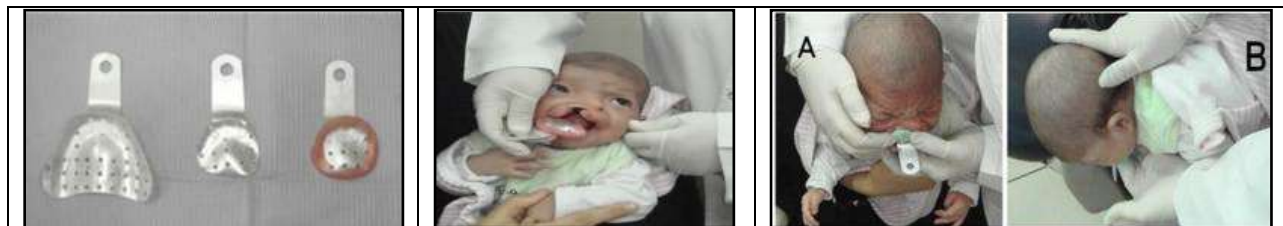

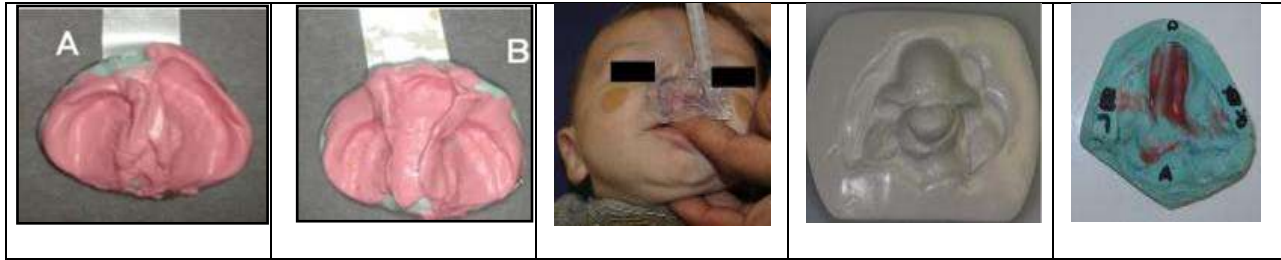
Fig. 11(a-f):-Schematic diagram representing Biomechanics of NAM for UCLP & BCLP patients

### Steps in NAM plate fabrication

#### Impression making

The different materials that could be used for impression making of cleft are impression compound, elastomeric and polysiloxane impression material due to manageable setting time and excellent tear strength. Wash technique using Light body impression material might cause gagging. Irreversible hydrocolloid (alginate) is not used due to poor tear strength and possibility of the set material to break into small pieces and occlude the air passage. A medium bodied silicone impression material is a preferred material of choice. A diagnostic impression is made usually by carrying the impression material using two fingers or even with a small tablespoon. The infant is fully awake without any anesthesia. Head is gently held in slightly upright position. Infant is held upside down ie, head facing a downward position towards the floor, to prevent aspiration, prevent tongue from falling back and to allow fluids to drain out of oral cavity. Head to be supported throughout the procedure. One person cradles the infant securely around chest & torso supporting the head & neck, while another obtains the impression. Excess material in posterior area should not block airway as infants are obligate nasal breathers. Infant should cry while making the impression which means the airway is patent. High volume evacuation should be ready. Nearby hospital set up is preferable with a surgeon available to handle any emergency situation (Fig. 12.a-i). Once the impression is set, the oral impression tray along with nasal impression should be taken out in single swift movement to prevent dislodgement or separation. Following this two casts are carefully poured, one for fabrication of prosthesis (working cast) & other for patient's permanent record (study cast) to assess progress of molding.<sup>59</sup>

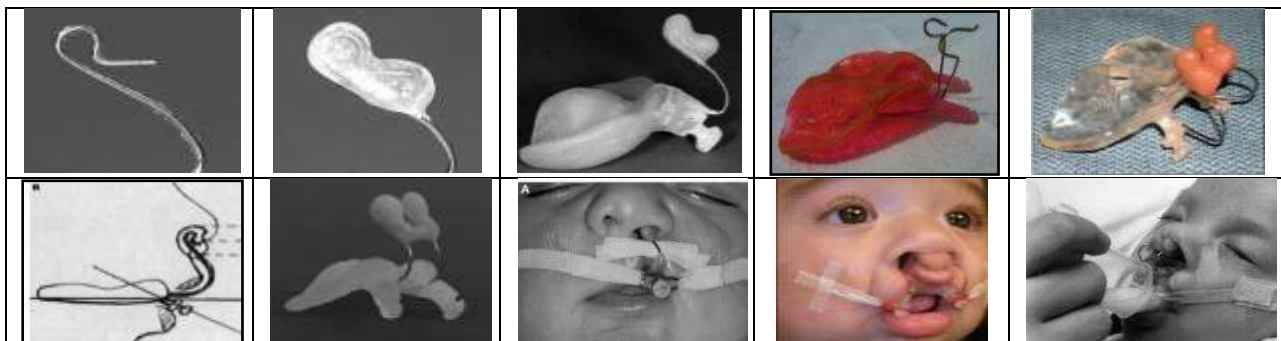




**Fig. 12(a-i)** :- Infant position during insertion of impression tray & clinician standing behind the patient's head at 10 o'clock position. Infant immediately turned onto his/ her belly after insertion of tray; Impression material extending facially to record anterior nares.

#### Appliance fabrication and design:-

Undercuts and cleft space are blocked with wax on stone model & separating medium applied. NAM Plate is fabricated using hard, self cure acrylic material & is lined with a thin layer of soft, resilient liner material to avoid injury to neonatal tissue. Molding plate should be checked for any sharp edges, rough surfaces or over extension at vestibular folds & posterior border, that can cause soft tissue irritation and ulceration. Frenum & muscle attachments should be adequately relieved. Ideal thickness of plate should be 2-3 mm to provide structural integrity & permit adjustments during the molding process. A small opening measuring 6-8 mm in diameter should be mandatorily made about 5mm anterior to posterior most border of moulding plate to provide an airway in the event that the plate drops down posteriorly. The retention arm is positioned approximately 40 degrees down from the horizontal to achieve proper activation and to prevent unseating of the appliance from the palate. NAM appliance for a bilateral & unilateral cleft infant has been demonstrated in *Fig. 13. (a-j)*.<sup>60</sup>



**Fig. 13(a-c)**:- Addition of Nasal stent for UCLP and BCLP patients

#### Retentive taping

It should be secured extraorally to cheeks using adhesive surgical tapes. With orthodontic elastics attached to one end, the tape is pulled in a specific direction from the retentive button to the cheeks to provide optimal retention to the molding plate. Additional skin barrier tapes like Duoderm or Tegaderm can be used to reduce irritation on the skin. Two separate grooves, at about 1mm distance, are made on the handle to receive elastics. Depth of groove should be adequate to prevent slipping of elastics. The elastics should be placed in same groove at any given time to prevent unequal forces on the plate. The elastics should be stretched approximately 2 times their resting diameter for proper activation force. However amount of force could vary depending on clinical objective and mucosal tolerance to ulceration. A horizontal **lip taping** is also done using adhesive Microfoam surgical tape to approximate the lip segments. Lip taping involves taping the cleft lip segments together, creating a tension that reduces gap between the two as well as pushes premaxillary alveolar segment towards a more acceptable & retruded position. Intraoral passive moulding appliances are always accompanied by extraoral strapping. **DynaCleft** is a commercially available taping system. Lip taping is easy to perform with minimal need for follow-up visits. The tapes are changed once a day. The only drawback being, lip taping if done alone, without providing any intraoral NAM appliance, might apply uncontrolled force causing unfavourable molding of segments into a non-desirable position related to each other.

### Extraoral retentive button

Extraoral retention button is attached to molding plate facing downwards & outwards at an angle  $45^\circ$  to occlusal plane. The vertical position of retention button should be at junction of upper & lower lip but should not interfere with molding of cleft lip or cause discomfort to mother while feeding. For unilateral & bilateral molding plates 1 & 2 buttons are used respectively. Its function is to provide adequate retention to the molding plate in oral cavity with help of orthodontic elastics & adhesive tapes. It also helps in easy insertion & removal of the plate.<sup>60</sup>

### Addition of Nasal stent

Clinically it has been suggest to start the nasal molding from day 1 along with alveolar molding to avoid wasting of the golden window period when the infant's nasal cartilage has high levels of hyaluronic acid. The Grayson technique starts nasal molding when alveolar gap is reduced to 5-6mm, whereas the Figueroa technique performs nasal & alveolar molding at the same time.<sup>61</sup> The stent is made of 0.036-inch round stainless steel wire & takes the shape of a swan neck. The hard acrylic component is shaped into a bi-lobed form resembling a kidney. A large nasal stent is used in Figueroa's technique to reduce chances of ulceration. In BCLP cases, two nasal stents are required. Focus is also there on non-surgical lengthening of the columella. The columellar length at birth is 0-2mm, following NAM, it increases to 4-7 mm. The usual length of columella at this age group is 3.2mm, but overcorrection is helpful to compensate for post surgical relapse.<sup>53</sup>

### Appliance Activation & adjustments

Weekly visits are required to modify the molding plate to guide the alveolar cleft segments into the desired position. Not more than 1mm of modification should be made at one visit. As alveolar segments start getting approximated, adjustments for the major segment include selective removal of about 1mm of hard acrylic along medial surface & addition of hard acrylic to external surface of molding plate. Exactly opposite to be done with respect to minor segment. A layer of soft denture liner is added to the hard acrylic for comfort. Mesio-lateral position of nasal stents is also adjusted as it lifts the nasal tip. In bilateral cases NAM is done in stages. Firstly, repositioning of everted premaxilla is done into space between lateral alveolar segments. Secondly, after approximation of alveolar segments, nasal stents entering nasal apertures are built from anterior rim of oral plate. This provides support to nasal dome, shapes alar cartilages & elongates deficient columella.<sup>40</sup> (Fig 14. a-d)

### Recall and follow up

Instructions regarding daily appliance care, feeding the infant while appliance is in situ, possible complications & their management are explained to parents. They are advised to keep the plate in infant's mouth full time & take it out for cleaning at least once a day. Patient should be recalled on weekly interval for progress assessment, necessary adjustments & motivation. Appliance retention, posterior extent of plate to prevent gagging & improvement in suckling ability should be checked. Duration of molding therapy is dependent on severity of initial cleft deformity, age at which PNAM has been commenced, type of case (unilateral/ bilateral) & parent cooperation.



Fig. 14(a-d):- Optimal maxillary arch symmetry obtained by NAM Therap for an UCLP patient

### Advantages of NAM Therapy

Reduces the size of cleft gap, thus improving surgical outcome. Primary nasal surgery becomes simpler after NAM & also provides stable long-term results. Gingivoperioplasty (GPP) could be performed without need for extensive tissue dissection. PNAM used in conjunction with GPP helps to avoid additional bone grafting surgery or early nose revision surgery. Also allows controlled, predictable repositioning without Lip adhesion surgery. In Bilateral cleft patients, PNAM combined with columellar lengthening eliminates the need of separate columellar elongation surgery, improves esthetics by reduced scar formation as well as enhances the infant's ability to properly feed & gain weight.<sup>62,63</sup>



### Complications of NAM Therapy

Occasionally there is a risk of obstructing the airway caused by dislodgement of molding plate. Excessive pressure from appliance can cause ulcers, irritations or bleeding of oral/nasal mucosa. Fungal infection can result due to poor oral hygiene maintenance. Extra-oral taping can cause rashes on the cheeks, this can be best managed by wetting the tape before removal, or applying aloe vera gel or anti-rash cream. During nasal moulding, excessive pressure applied or improper positioning of the stent can lead to mega-nostril (gap > 6 mm) or inflammation of nasal epithelium. Excessive rotation of the lesser alveolar segment in its approach to meet the greater segment in a perpendicular manner, might result in asymmetric T-shaped configuration. Compliance of the patient, parents or caregivers is a key factor for successful outcomes.

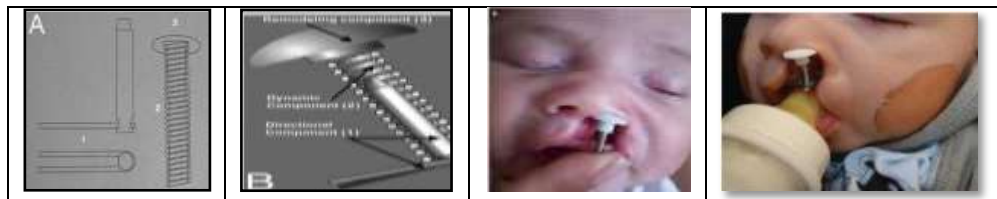### Advancements in NAM Therapy

#### Modified muscle- activated maxillary orthopedic appliance for Presurgical NAM in infants with UCLP

Sanjay Suri and Bryan D Tompson (2004)<sup>64</sup> conducted a study to describe a treatment approach for PNAM in unilateral cleft patients. This approach uses a plate held in with outriggers, which prevents the cleft-widening effect of the tongue, helps with tongue tip placement, and utilizes the functional movements of the facial musculature to guide and relocate the major segment medially to its normal position. Nasal molding is undertaken after most of the latero-medial correction of the alveolar position. They concluded that this technique helps to improve alveolar position, nasal septum alignment, nasal symmetry, and nasal tip projection prior to lip repair.

#### Dynamic presurgical nasal remodeling (DPNR) in patients with UCLP: Modification to the original technique

Bennun & Figueroa (2006)<sup>65</sup> presented a technical modification to the original presurgical nasal remodeling appliance introduced in 1991. The modified appliance consisted of 2 elements- A perfectly adapted conventional acrylic intraoral plate & a dynamic nasal bumper attached to the vestibular flange. The modified nasal extension consisted of 3 components. 1: Directional component ('U' wire & stent) 2: Dynamic component (open coil spring) 3: Remodeling component (soft silicone 'bumper'). The principle behind this DPNR technique is the use of force generated during suction & swallowing. In unilateral cleft patients, DPNR technique improved the deformation of nasal structures by straightening the columella, elevating the nasal tip & remodeling the depressed cleft side alar cartilages. In bilateral cleft cases, it elongated the columella, obtained nasal tip projection, facilitated surgical reconstruction & improved postsurgical outcomes. (Fig. 15. a-d)



**Fig. 15(a-d) :-** The components of DPNR appliance has been illustrated 1: Directional component ('U' wire and stent). 2: Dynamic component (spring). 3: Remodeling component (soft silicone bumper), **c,d**) Infant feeding comfortably while wearing a dynamic NAM device

#### Nasoalveolar molding (NAM) of BCLP infants with orthopedic ring plate

Ijaz A, Raffat A, Israr J (2010) conducted a study to introduce a custom made, simple, self-retentive & cost effective orthopedic appliance with an anterior acrylic ring. This innovative plate comprised of 2 parts; the palatal plate covering the palatal defect, serving as a passive obturator & anterior part of the plate extended as a ring around the malpositioned premaxilla, acting as an active part to align & retract the protruded & deviated premaxillary segment. The plate was made self-retentive by adding soft acrylic on its palatal surface, filling the cleft area. There was no need of any extra-oral attachment. It produced columellar elongation & increase in prolabium length, facilitating primary cheiloplasty & rhinoplasty without scarring.

#### Active alveolar molding appliance

Retnakumari N, Divya S, et al. (2014)<sup>66</sup> did a study on NAM treatment under PSIO in CLP patients. Certain clinicians used split molding technique for retraction of premaxilla along with alveolar remodeling. It also consisted of an alveolar plate with expansion screw (Jack screw) fully opened. The appliance was activated by closing the screw & by selective grinding & relining with denture base material. The premaxilla retracted & cleft gap reduced within 3 months, reducing tissue tension & scar formation (Fig 16. a-h)

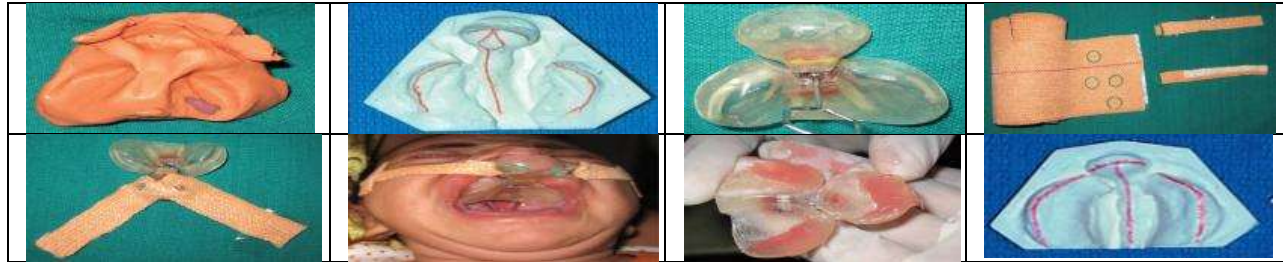


Fig. 16(a-h) :-Active alveolar molding appliance with expansion screw

**Dynacleft and Nasal Elevators**

Vinson LA (2016), did a study on PSIO in CLP care. Dynacleft is a premade nasoalveolar molding device which could be used to successfully mold upper lip, alveolus & nose prior to CL repair. Unlike tape, Dynacleft offers benefit of being able to provide a constant approximation force with an elastic center allowing it to conform to a baby’s mouth better due to its ability to expand & contract. Additionally, controlled force that it provides to prolabium & premaxilla could improve surgical results & decrease necessity of early lip adhesion surgery. (Fig. 17. a-c)



Fig. 17 (a-c):- Dynacleft in use as a nasal elevator for a bilateral and unilateral cleft patient

**NAM therapy with Computer Aided Design (CAD-NAM)**

Xin Gong & Quan Yu et al. (2012) did a study on Correction of maxillary deformity in infants with BCLP using Computer Aided Design (CAD). (Fig. 18. a-j) Treatment planning & appliance design were accomplished with CAD-NAM, which enabled accurate analysis of movements in multiple planes. Guiding principle was application of constant low-grade controlled force in the right direction to reshape & reposition anatomic structures. Maxillary alveolar segments were directed to their final & optimal positions. On analyzing its effectiveness on maxillary alveolar morphology in infants, it was found that CAD-NAM effectively reduced cleft gap, corrected maxilla midline & improved sagittal length of maxilla. Alveolar height decreased significantly after treatment, which indicated that traction force of the appliance may have obstructive effects on vertical growth of alveolar bone.

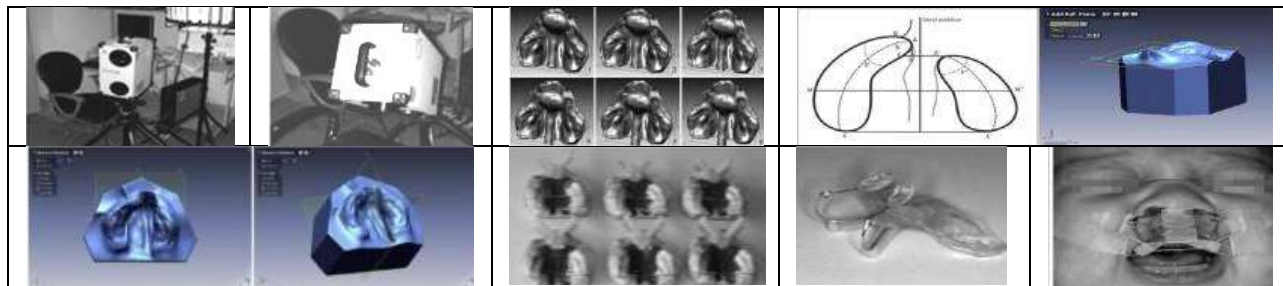


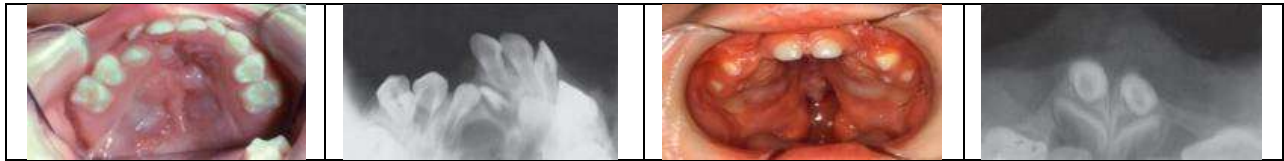Fig. 18(a-j):- NAM therapy using CAD- NAM appliance

Thus Naso Alveolar Molding technique, when considered soon after birth, has been significantly shown to improve surgical outcome of cleft patients compared to other techniques of presurgical orthopedics.<sup>61</sup> PNAM should be performed prior to primary lip repair. This usually gives psychological reassurance to parents and enhance the future functional & esthetic outcome. It reduces the need for soft-tissue revision surgeries later on & also the overall treatment cost.

## Stage II: Primary Dentition Stage

### Primary alveolar bone grafting

After definitive lip closure at about 3 months of age, maxillary arch collapse in UCLP and BCLP patients is common. It is attributed to increased tension placed on segments by repaired lip. 75% of the patients with CLP have an anterior alveolar bone defect and deficient alveolar bone support might also contribute to collapse of alveolar segments. To prevent this, an obturator is used to provide cross-arch stability & support as well as achieve orthopedic molding of maxillary segments. Furthermore, surgical reconstruction of cleft with bone graft also becomes necessary for eruption of teeth adjacent to the defect, for orthodontic and prosthodontic rehabilitation and for closure of symptomatic oronasal fistulas if present. When the maxillary segments are in good alignment and abutted across the cleft sites, the patient is ready for primary alveolar bone grafting. This generally occurs by 6 to 9 months of age. Primary bone grafting refers to bone-grafting procedures involving alveolar cleft defects in children younger than 2 years of age (Fig. 19. a-d). According to **Rosenstein & colleagues**, minimal dissection technique should be implemented and care should be taken not to disturb the **vomeropremaxillary suture**, otherwise it might cause impaired postnatal maxillary and midfacial growth leading to development of crossbite and pseudoprognathism. In non-grafted clefts, maxillary arch collapse is common after palatoplasty. Primary alveolar bone grafting establishes maxillary arch continuity early in life by producing a one-piece maxilla rather than two or three segments, facilitating conventional orthodontic treatment in future. These grafts also provide bony support during eruption of primary lateral incisors through the cleft site. Hence bone grafting is considered an important step in the current protocol of cleft management.<sup>40,67,68</sup>



**Fig. 19(a-d):**-UCLP & BCLP patients where primary alveolar bone grafting procedure is beneficial.

### Routine dental care

Primary teeth are important for chewing, aesthetics, and speech. They assist in guiding the permanent teeth to erupt into their proper place in dental arch. Early removal of primary teeth in cleft children is particularly contraindicated because of possible space loss, making future orthodontic treatment more difficult. It is thus important to make the parents understand the value of good dental health and initiate Infant oral healthcare program. During primary dentition stage, children should begin to have periodic dental check up at 6-month interval with the pediatric dentist. Establishing correct dental habits from an early age helps to ensure health of both primary and permanent dentition.<sup>69</sup>

- A study by **Kamble & Hiremath et al (2017)** showed statistically significant increase in prevalence of dental caries in cleft children, significantly higher mean DMFT & poor oral hygiene in operated children due to reduced access for cleaning upper anterior teeth after surgical repair. It was concluded that, cleaning in the potential areas of plaque accumulation around the cleft regions should be properly demonstrated. A more rigorous approach to be advocated for prevention of dental disease in these high-risk children subjecting to regular checkups, oral hygiene practices & diet counseling, appropriate fluoride supplementation & timely referral for secondary care whenever required.<sup>70,71</sup>

- **Use of Fluoride:** A low-fluoride children's toothpaste containing no more than 600 ppm fluoride is recommended for children under 6 years of age to reduce the likelihood of enamel opacities in the permanent teeth. Children with a high risk of developing caries should use a standard toothpaste (1000 ppm fluoride). A twice-yearly professional application of topical fluoride varnish is recommended.

## Stage III: Mixed Dentition Stage

### Management of deficient midfacial growth

Patients with maxillary hypoplasia secondary to orofacial cleft present multiple challenges. Traditional orthodontic or orthopedic approaches to treat these patients are sometimes successful in obtaining stable occlusal relationships but often falling short of expectations with respect to facial balance & esthetics. The midfacial deformities due to primary cleft surgeries include transverse maxillary deficiency with crossbite, midfacial retrusion, reduced antero-

posterior development, mandibular prognathism and concave soft tissue profile.<sup>72</sup> The various treatment protocols that are usually followed for correcting this secondarily acquired discrepancies are-

### Protraction of mid face

In patients with severe hypoplastic maxilla following cleft palate surgery, major maxillary advancement with conventional LeFort I osteotomy gives rise to extreme discrepancies making stabilization difficult & added effect of palatal scarring results in significant surgical relapse. So alternative technique using patient's growth potential gained much stable and satisfactory results. Maxillary protraction is achieved orthopedically by using a face mask at about 8 years of age. Though the skeletal changes are limited, they produce marked improvements in soft tissue profile.<sup>73</sup> (Fig. 20. a-d)

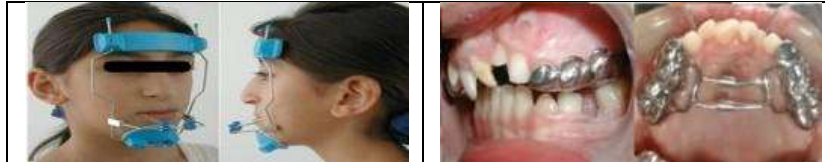

Fig. 20(a-d):- Maxillary sagittal protraction with Face mask therapy

### Palatal expansion (Rapid maxillary expansion/ RME)

Expansion of palate was first achieved by **Emerson C. Angell in 1860**. Expansion of dental arches can be classified as dental expansion, skeletal expansion and passive expansion. Rapid Maxillary Expansion or RME, also known as split palate, is an example of skeletal expansion and produces skeletal changes rather than mere tipping of the teeth. It results in separation of the midpalatal suture moving the maxillary shelves away from each other.<sup>74</sup> (Fig. 21. a-d)

### Indications of RME

Palatal expansion is advised in CLP cases with maxillary transverse deficiency, restricted growth of maxilla leading to posterior crossbite, maxillary arch collapse, constriction and retrusion.<sup>75</sup> Correction achieved through RME is often with the help of reverse pull headgears. RME is unique among therapies, since the bony movements ramify beyond the dento-alveolar complex. It can also have fundamental effects on improving compromised respiration in certain cleft individuals with medical conditions related to orodental structures. These include nasal stenosis, poor nasal airway, septal deformities like Deviated Nasal Septum, recurrent infections of ear, nose & maxillary sinus, allergic rhinitis etc. There is an increase in intra-nasal space or width of nasal cavity following RME. Thus airflow resistance is believed to reduce by 45-60%, thereby improving nasal breathing.

### Contraindications of RME

Ossified mid- palatal suture, single tooth crossbite, true unilateral crossbite, patients with severe antero-posterior skeletal discrepancies, vertical growers with steep mandibular plane angle, associated with mandibular retrognathism, periodontally weak dentition, any soft tissue pathology in pressure bearing area.

### Timing of ossification of mid palatine suture

A patent midpalatal suture is considered highly responsive to transverse forces, whereas an ossified or integrated suture is not only unresponsive to non-surgical expansion, rather it could be potentially harmful to the periodontium. Thus RME should be initiated prior to ossification of mid palatal suture. **Melsen (1975)** reported that transverse growth of mid-palatal suture continues up to 16 years in girls & 18 years in boys. Earliest closure of mid palatine suture was observed in a girl aged 15 years. While oldest person with an un-ossified suture was a woman aged 27 years. Certain primary cartilages remain at junction of various bones & sutures acting as important growth sites. These are replaced by bones later in life. These areas known as 'synchondrosis', present at midpalatine suture site, are probably the reason for late ossification & maturation of this suture.<sup>74</sup>

### Activation schedule

It is usually done by opening the screw in appliance using a key provided by manufacturer. Opening the screw by a quarter turn 90 degree (one turn equal to ¼ turn of central bossing) brings about a linear movement of 0.18mm which is less than width of periodontal ligament ie, about 0.25mm. The pattern of threading on either side is of opposite direction. Thus turning the screw withdraws it from both sides simultaneously causing two halves of screw to move apart producing desired force for expansion. In children, expansion screw can be activated twice a week. Since width of periodontal ligament is narrow in adult patients, activation should be done only once a week, to move



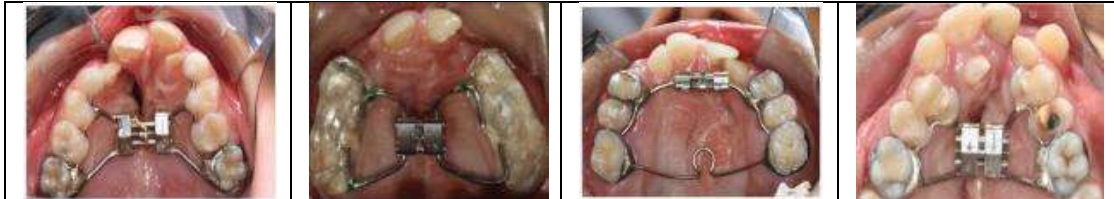the teeth slowly. An increase in maxillary width of up to 10mm can be achieved by RME. The rate of expansion is about 0.2 to 0.5mm per day.

#### **Schedule by Zimring and Isaacson**

In young growing patients, two turns each day for 4-5 days and later one turn per day till the desired expansion is achieved. In non growing adults, two turns each day for first 2 days, one turn each day for next 5-7 days & one turn every alternate day till desired expansion is achieved.

#### **Schedule by Timms**

For patients upto 15 years of age, 90° rotation in the morning and evening. In patients over 15 years, 45° activation 4 times a day has been recommended.



**Fig. 21(a-d):-** Different type of rapid maxillary expanders used for unilateral & bilateral cleft patients.

#### **Distraction Osteogenesis**

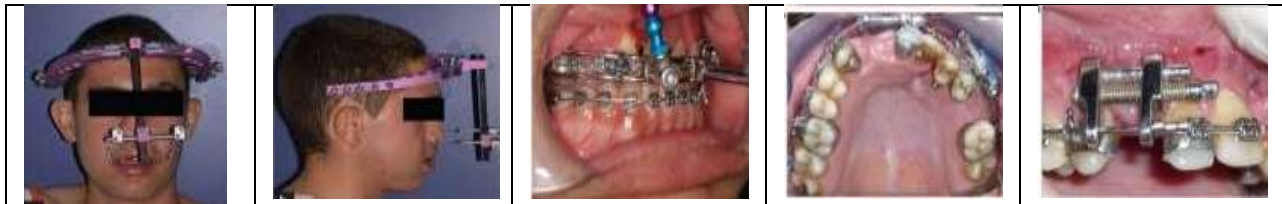Distraction Osteogenesis (DO) is a technique by which lengthening of a bone can be brought about by new bone formation as a part of normal healing process. It is a procedure wherein two segments of bone are slowly moved apart in such a way that new bone fills the gap. The concept is widely applied for correction of dentofacial deformities. Use of Distraction techniques has revolutionized the treatment options available for patients with craniofacial abnormalities. Thus osteotomies followed by Distraction Osteogenesis (DO) have become an integral part of the correction of maxillofacial deformities seen in cleft lip & palate patients (McCarthy *et al.*, 1992). Distraction of maxilla was first proposed by Molina & Ortiz-Monasterio (1998). A unique device, the (KLS-Martin) Rigid External Distraction (RED) appliance is one which allows correction of severe retrusion of >12mm (Polley & Figueroa, 1997).

#### **Procedure of Distraction osteogenesis**

Primarily a bone is surgically osteotomized or fractured & the ends are gradually distracted away from each other with a regular controlled force. A device known as **distractor** is attached to both sides of osteotomed bone, which is gradually adjusted over a period of days or week, through slow application of force, resulting in new bone formation between the two cut ends of the bone as well as enhanced soft tissue adaptation. This bone formed may initially be immature but later transforms into mature strong bone similar to remaining skeleton.<sup>76</sup> (Fig. 22. a- j)

#### **Distraction Osteogenesis Versus Orthognathic surgery**

This procedure comes as an alternative to or almost replaces orthognathic surgery. When compared, the greatest advantage of DO is that during this slow process the soft tissue envelope of bone has the ability to accommodate the gradually enlarging underlying skeletal framework. That means soft tissue remodelling also occurs simultaneously along with new bone formation. That is the uniqueness of this technique because it greatly contributes to long term stability of the whole procedure & also reduces all potential damages or complications that can be caused by a definitive invasive surgery.



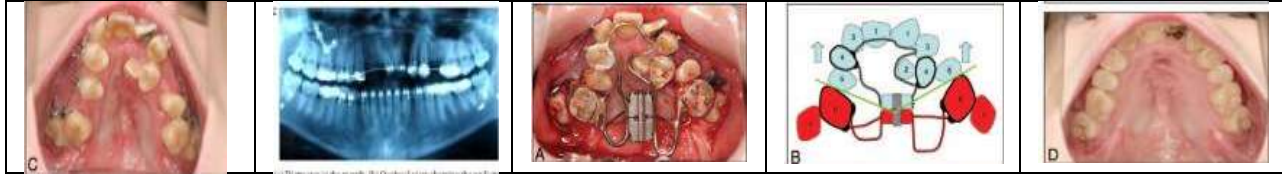

Fig. 22(a-j):- Distraction osteogenesis performed on cleft patients

### Indications for Distraction in cleft patients

Maxillary deficiency due to presence of Cleft lip & palate, severe midfacial deficiency, where Palatal expansion is necessary, in Syndromic conditions like Pierre Robin sequence etc

### Basic principles of Distraction Osteogenesis:-

1. *Performing atraumatic corticotomy/ osteotomy:* It is a low energy osteotomy of the cortex preserving local blood supply to both periosteum & medullary canal.
2. *Healing/ latency period or delay:* It is that time interval after corticotomy is performed until the time when distraction is initiated, for mesenchymal proliferation, fibrovascular bridge & callus formation. Generally a delay of 4-7days is acceptable.
3. *Rate of distraction:* It is number of millimeters per day at which bone surfaces are stretched. A rate of 1mm a day is considered optimal.
4. *Rhythm of distraction:* It is number of distractions per day usually in equally divided increments to total the rate. The rhythm of device activation may vary from one cycle per day of 1mm to 0.5mm twice daily.
5. *Healing index/ Stabilization period/ Consolidation period:* It is the number of days or months from the operation when the distraction device is kept in neutral position or can be removed so as to expose the bone to unprotected load bearing forces. This period generally ranges from 4-6 weeks or can be extended to 6-10 weeks if required.

### Advantages

DO a safer surgical technique & a more conservative procedure, decreases operating time, length of hospitalization & morbidity. There is no need for autogenous bone grafting & could be done in young patients rather than waiting for growth completion as done in case of orthognathic surgery. It has a wide range of application in correcting congenital & acquired craniofacial deformities as well as benefit of associated soft tissue growth like muscle, mucosa, skin along with bony tissue.

### Complications

With DO, occasionally there might be injury to a developing tooth bud or a vital structure like inferior alveolar nerve, or a pin track infection in case of extraoral devices. Early removal of the device might lead to fracture of jaw due to inadequate bone formation and rarely fibrous union might occur instead of mature bony union.

### Secondary Alveolar Bone Grafting

An orofacial cleft repair is not only repair of cleft lip or cleft palate, a repair of cleft in dental alveolus is equally essential. Surgical closure involves approximation of soft tissue flaps over bony defect to unite separated segments. This however, does not result in bone formation between two ends of cleft. As mentioned by **Bergland et al**, establishing a bony continuity produces an improved environment for further growth & eruption of teeth in defect area. In addition, good bone support in palatal area for denture retention, if that is needed. To accomplish this, it is better to place some bony graft material into the defect that can induce bone formation. Secondary alveolar bone grafting is now a common practice in treating CLP patients. Ideal goal is to improve dental arch form & achieve non-prosthetic rehabilitation of dental arch. Successful grafting provides an osseous environment to permit spontaneous eruption of canine into the grafted area. Among other benefits (a) provides firm bony support for alar base of nose improving symmetry & facial esthetics (b) closure of oronasal & nasolabial fistulas- that prevents reflux, nasal regurgitation, reduces frequency of infections and improves speech. (c) Stabilizes premaxilla after infant orthopedics in BCLP cases (d) decreases maxillary collapse & need for orthognathic surgery but facilitates secondary corrective procedures like osteotomy, if required (e) also provide adequate bone volume for future dental implant.

### Ideal Timing

Timing of bone graft surgery is highly variable & does not depend on chronological age. Rather, dental development age is important that affects the outcome (**Dawson et al, 2003**).

- *Early Secondary bone grafting* is done between 2 and 4 years of age
- *Secondary bone grafting* is done between 4 and 15 years of age and
- *Late secondary bone grafting* refers to reconstruction of residual alveolar cleft defects in adults.

It should be undertaken during mixed dentition stage, before eruption of canines or when permanent lateral incisor or canine tooth roots are approximately one-third developed. Since sagittal & transverse growth of anterior maxilla is completed by 8 years & lateral incisors erupt by 8-9 years & canine by 11-12 years of age, currently alveolar bone grafting is performed by 9-11 years of age.

### Source of bone graft material:-

Materials placed into the defect may be either any autogenic or allogenic bone material or occasionally synthetic bone inducing material. Any autologous cancellous bone is considered the best source of bone graft material. Among them the corticocancellous graft from anterior portion of iliac crest is usually the preferred donor site in most cases. The other sources are- rib, tibia, cranium & the mandible.<sup>9,77</sup> (Fig. 23 a-h)

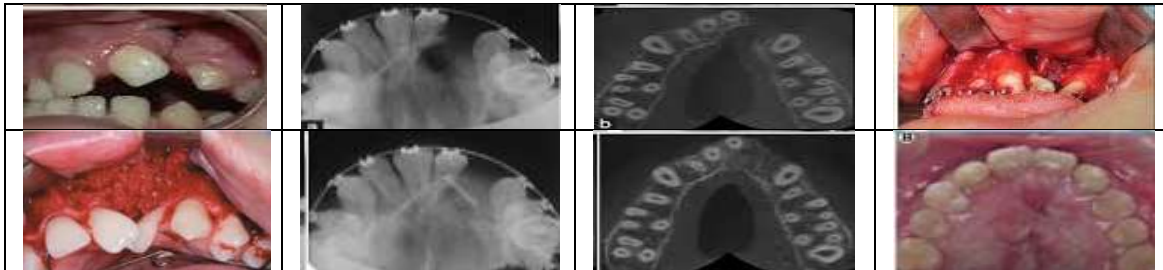


Fig. 23(a-h):-Secondary alveolar bone grafting procedure in cleft patient

### Protocols followed

Patients with alveolar cleft might need orthodontic expansion with fixed appliance to create space for placement of bone graft. Maxillary expansion, if required, depending on extent of maxillary arch collapse, should be completed 6 months prior to grafting procedure. Anterior teeth with large rotations should not be corrected prior to grafting to avoid fenestration & dehiscence. Extraction of primary & supernumerary teeth adjacent to cleft is done at least 6 weeks prior to grafting. After placement of graft material, post operative evaluation is done at interval of 15 days, 1 month & 3 months through radiographs. Graft is always placed prior to orthodontic corrections. Patient needs to wear a retainer until beginning of definitive orthodontic treatment. Orthodontic treatment for alignment of teeth should be initiated at least 6 weeks later.

### Routine dental care

The risk of developing caries increases with placement of orthodontic appliances. Moreover oral hygiene before bone grafting must be of very high standard as gingival inflammation could cause loss of new bone. Access to teeth around cleft region is often difficult especially where upper lip tightly adheres to vestibule after surgical repair. Hence a baby-sized toothbrush & interdental aids are useful. Importance is given to correct toothbrushing technique & effective home care instructions. Use of Fluoride mouthwash could be introduced. Pit & Fissure sealants could be placed on occlusal surfaces of 1st & 2nd permanent molars & premolars, as soon as the teeth have erupted sufficiently. Pulp treatment procedures & stainless steel crowns for primary molars should be carried out where appropriate. For parents of cleft babies, the stages of cleft surgery are major 'landmarks' or 'milestones'. A Pedodontist needs to have an understanding of the surgical procedures and their timing so that dental care could be integrated sensibly within the overall treatment tenure.

### Interceptive Orthodontics (Phase 1 Correction)

This begins when the child is 8 to 8½ years old and completed within approximately 1 year depending on the child's cooperation. Timing usually depends on eruption of permanent first molars and maxillary incisors. A tentative decision on extraction of supernumerary teeth & over retained teeth has to be taken. Correction of crossbite could be done. Frequently, maxillary incisors in area adjacent to cleft, erupt rotated and out of alignment. These anterior teeth

are moved into a more desirable position to allow successful grafting of bone. If lateral incisors are congenitally missing, space would be made for a pontic.<sup>78</sup> Sometimes closure of space is recommended where a permanent tooth is missing. Expansion of collapsed segment to improve surgical access to graft site is carried out in this stage. This way posterior crossbite is corrected. Correction of jaw relationship using facemask therapy in mild maxillary deficiency along with control of oral habits could be initiated. Functional shift or space loss after premature loss of primary teeth could be corrected. An increased tendency towards a Class III incisal relationship may become more apparent. Anterior crossbite could be corrected using removable or fixed appliance in order to avoid functional mandibular displacement or retardation of maxillary growth due to 'locked in' maxilla. Milestones of growth & development in a cleft child to be monitored. Skeletal & dental components to be evaluated during each dentition stage, to determine presence of any developing malocclusion.

#### Stage IV: Permanent Dentition

##### Routine Dental care corresponding to Definitive Orthodontics (Phase II Correction)

This stage marks the beginning of definitive orthodontic treatment which is carried out when permanent dentition is fully erupted. The pediatric dentist & orthodontist communicate closely on a regular basis during this phase. The patient needs to be made aware of potential problem of decalcification around orthodontic brackets. Oral hygiene maintenance & effective toothbrushing is reinforced. This coupled with good dietary habits help to decrease risk of tooth decay. Acidic & sugary foods need to be regulated. Prophylaxis & fluoride treatments should be performed. Cavities developed during active orthodontic therapy should be immediately treated. Comprehensive cleft management based on chronological age has been illustrated in Fig. 24.

| SL NO | TIMING                                 | PROCEDURE   |
|-------|--|---|
| 1.    | After 16 weeks of pregnancy            | Cleft lip diagnosis by ultrasound images(USG)   |
| 2.    | Prenatal                               | Prenatal consultation, Genetic counseling   |
| 3.    | Neonatal / immediately after the birth | Pediatric consultation, counseling, feeding instructions, syndrome identification, diagnostic tests to evaluate life expectancy, Initial assessment including hearing testing with first few weeks. |
| 4.    | 0-3months                              | Lip taping, NAM, Team evaluation  |
| 5.    | 3-4 months                             | Lip adhesion, primary Lip repair (3-6 months in India), tip rhinoplasty   |
| 6.    | Between 6-12 months                    | Cleft Palate repair, Soft palate repair (9-12 months), Hard palate repair (18-24 months), intravelar veloplasty, placement of pressure equalization tubes for hearing impairment                    |
| 7.    | 3 months after palate repair           | Speech and language assesment, oral motor sensory assesment   |
| 8.    | 2.5-5years                             | Speech therapy, treatment for middle ear infection, fistula repair, soft palate lengthening, psychological evaluation, Dental care  |
| 9.    | 5-7years                               | Speech therapy, Pharyngeal surgery, VPI surgery   |
| 10.   | 6-9 years                              | Speech therapy(till 11 years), Early Orthodontics, Alveolar bone grafting   |
| 11.   | 12-14 years                            | Definitive orthodontics   |
| 12.   | 16-18 years                            | Orthognathic surgery (Maxillary advancement, perhaps combined with mandibular set-back; not done until growth completed), Nose & Lip revision surgery (Cheilorhinoplasty)                           |
| 13.   | 18-21 years                            | Fixed prosthodontics, Dental implant, Plastic reconstructive surgery.   |

Fig. 24:-Comprehensive Cleft Management based on Chronological age



**To summarize cleft care and Role of a Pedodontist**

Children with facial differences have unique identities with something special to add to the community. But they are often seen as object of pity, suffering 'emotional burn out' & the pain of 'being different'. As far as nature is concerned, no congenital anomaly has more complexity & diverse morphological influence in the oral & maxillofacial region than the cleft lip and palate. For a cleft child, the stigma of facial deformity not only affects the individual but also his/her family, peer, acquaintances & society itself. Thus it is our duty to provide them with hope and opportunity as well as boost their confidence to live a balanced and fulfilling life, without the fear of being judged or pressurized to act otherwise.

Cleft treatment requires a holistic approach extending from birth until adulthood, the complexity of the problem requiring a number of health care practitioners both medical, dental and allied healthcare workers to co-operate with each other & ensure comprehensive care for the patient. The ACPA promotes involvement of interdisciplinary cleft team that has been described as union of multiple specialities devoted to the single cause of cleft patient well-being. Among the dental professionals, Pediatric dentist play a vital role right from the neonatal period up to late teen years in rendering a complete oral rehabilitation. Thorough treatment planning, their strategic execution, implementation of skillful behavior management, counseling and providing mental support to cleft affected patients are important aspects of this multifaceted pediatric dental care.<sup>35,79</sup>

A Pedodontist performs dual role in both modifying the personal impact as well as improving the surgical outcome. Being a responsible member of the interdisciplinary team, a Pediatric dentist, serve an important function as they not only provide a dental home for the children & counsel the parents, but also co-ordinate the treatment needs among different cleft specialists. They are one of the constant entities who keep maintaining a high quality oral hygiene status in cleft children that could influence the outcome of other line of treatments proceeding simultaneously. They perform specialized treatment procedures in coordination with other cleft team members. In addition, they ensure that the patients with cleft receive the appropriate dental care. Routine dental care is important to maintain optimal oral and general health in all stages of cleft care. Since patients with cleft are a priority group, a pediatric dentist plays a key role in providing continuous, high-quality, preventive-based dental care.<sup>80</sup>

A Pediatric dentist is an integral part of the cleft rehabilitative process and helps restoring both esthetics & function of the dento-facial system for a cleft affected individual. They provide surveillance during the various orofacial developmental stages of the child and performs infant orthopedics, thus reducing the severity of the cleft deformity. The other objectives are to motivate breastfeeding aided with feeding appliance thus taking care of overall nutrition, diagnosing future malocclusions & also informing about specialist referrals in correct timing.<sup>81,82</sup>

Pediatric dentists are well acquainted with a child's overall knowledge, thus in a way by understanding a cleft child's psychology & different aspects of behavior management, they deliver treatment in a most empathetic way. Be it preventive, restorative or interventional care in management of a cleft individual, a committed pedodontist who follows up all the appointments in time will be the need of the hour. Since speech and hearing difficulties are a common occurrence in these children, it may present as a possible barrier to satisfactorily communicate with them, so a dentist show a lot of patience to establish a good communication, especially in the early years, and thus help in grooming them to be a part of the normal society. Moreover, a transparent communication on a regular basis between the pedodontist, parents & relevant members of the cleft team helps to achieve the best oral health outcome for the patient.

**Conclusion:-**

Thus, we could see that, the role played by a Pedodontist in comprehensive cleft care, would remain unparalleled, as he is a trained professional & well versed with various kinds of treatment modalities for managing a child patient, both normal and special. There is a constant urge of these innocent children, of receiving social recognition from the 'significant others' and return to the mainstream of life. Hence it is high time for all the Pediatric dentists to get involved & actively participate in overall rehabilitation of a cleft affected child, as every child has the fundamental right to his complete oral health and every pedodontist has an obligation to fulfill this faith.

**References:-**

1. Ramanan PV, Balan R, Murthy J, Hussain SA. Association of other congenital anomalies in children with cleft lip and palate: a prospective hospital based observational study. Int J Contemp Pediatr 2019;6:1059-62.

2. Balaji SM. Burden of orofacial clefting in India, 2016: A global burden of disease approach. *Ann Maxillofac Surg* 2018;8:91-100.
3. Banerjee M and Dhakar AS. Epidemiology-clinical profile of cleft lip and palate among children in india and its surgical consideration; *CIB Tech Journal of Surgery* 2013;2(1):45-51.
4. Kesave JS, Punn K, Bedi RS. Multidisciplinary Team Management of Cleft Lip and Palate: An Indian Perspective. *Asian J of Oral Health & Allied Sciences* 2012; 2(1) 59-62.
5. Raman S, Jacob M, Jacob MS, Nagarajan R. Providing intervention services for communication deficits associated with cleft lip and/or palate: A Retrospective analysis. *Asia Pacific Disability Rehabilitation J*, 2004;15(2):78-85.
6. Fogh-Andersen P. *Inheritance of Harelip and Cleft Palate*. Copenhagen, Denmark, Munksgaard; 1942.
7. Dixon MJ, Marazita ML, Beaty TH and Murray JC. *Cleft lip and palate: understanding genetic and environmental influences*. Macmillan Publishers Limited, March 2011; 12: 167-178.
8. Allori AC, Mulliken JB, Meara JG, Shusterman S, Marcus JR. Classification of Cleft Lip/Palate: Then and Now. *The Cleft Palate–Craniofacial J*, January 2016; 53(1): 1-14.
9. Zreaqat MH, Hassan R, Hanoun A. *Cleft Lip and Palate Management from Birth to Adulthood: An Overview (Chap 6). Insights into Various Aspects of Oral Health*, 2017; 99-121.
10. Jones MC. Prenatal diagnosis of cleft lip and palate: detection rates, accuracy of ultrasonography, associated anomalies, and strategies for counseling. *Cleft Palate Craniofac J*. 2002; 39(2): 169–73.
11. Perillo L, Apuzzo FD, Eslami S and Jamilian A. *Cleft Lip and Palate Patients: Diagnosis and Treatment. Designing Strategies for Cleft Lip and Palate Care (Chapter 2)*, 2017; 23-42.
12. *Critical Elements of Care: Cleft Lip and Palate; The Center for Children with Special Needs Seattle Children’s Hospital, Seattle, WA; Fifth Edition, Revised 10/2010.*
13. Pesun IJ, Minski J, Narvey M, Pantel C, Swain V. Use of an obturator with nCPAP in a premature infant with a cleft lip and palate: A Clinical report. *J Prosthet Dent* 2015;113:493-497.
14. Bhaskar V, Parikh D, Choudhary P, Ganesh M. *Pediatric dental care for cleft lip and palate child- Part 1. The J of Ahmedabad Dent College and Hospital*, 2010; 1(1): 13-17.
15. Paul T, Brandt RS. Oral and dental health status of children with cleft lip and/or palate cleft palate–craniofacial journal. July 1998; 35(4): 329-32.
16. Nunn JH, Carter NE, Gillgrass TJ, Hobson RS, Jepson NJ, Meechan JG and Nohl FS. The interdisciplinary management of hypodontia: Background and Role of Paediatric dentistry. *Practice* 1. *British Dental Journal* 2003; 194(5): 245–251.
17. *Cleft Lip and Palate Resource Handbook. The Children’s Center for Cleft and Craniofacial Disorders. Children’s Healthcare of Atlanta Inc. (choa.org/craniofacial)*, 2018; p 1-36.
18. Policy on management of patients cleft lip/palate and other craniofacial anomalies. American Academy of Pediatric Dentistry Council on Clinical Affairs. *Pediatr Dent*. 2008-2009; 30(Suppl 7): 238-9.
19. Rypula DI, Pietraszewska D, Kempa M, Ziob MZ, Wiczkowski A. Methods of cleft lip and palate treatment over the centuries – A historical view. *Ann Acad Med Siles* 2017; 71: 399-406.
20. Kati FA. Cleft lip and palate: Review article. *World Journal of Pharmaceutical and Medical Research* 2018; 4(7): 155-163.
21. Goodacre T and Swan MC. Cleft lip and palate: Current management. *Occasional review (Elsevier Ltd). Paediatrics and Child health*, 2011; 22(4): 160-168.
22. Shaye D, Liu CC, Tollefson TT. Cleft Lip and Palate An Evidence-Based Review (Elsevier Inc). *Facial Plast Surg Clin N Am* (2015); p 1-16.
23. Shkoukani MA, Chen M and Vong A. Cleft lip – a comprehensive review. *Frontiers in Pediatrics. Pediatric Otolaryngology* 2013; 1(53): 1-10.
24. Shah CP, Wong D. Management of children with cleft lip and palate: Review article. *CMA Journal*, January 12, 1980; 122: 19-24.
25. *Parameters for Evaluation & Treatment of Patients with Cleft Lip/Palate or Other Craniofacial Anomalies. American Cleft Palate–Craniofacial Association. Revised Edition. November 2009.*
26. *Parameters for the Evaluation & Treatment of Patients with Cleft Lip/Palate or Other Craniofacial Anomalies. Cleft Palate–Craniofacial J*, 1993;30(Suppl 1); Revised edition, Jan 2018.
27. Lewis CW, Jacob LS, Lehmann CU. The Primary Care Pediatrician & Care of Children With Cleft Lip &/or Cleft Palate. *Pediatrics* 2017;139(5):e20170628. AAP Section on oral health.
28. Policy on the Management of Patients with Cleft Lip/ Palate and Other Craniofacial Anomalies. American Academy of Pediatric Dentistry; Council on Clinical Affairs, Latest Revision: 2012, Reference Manual, 40(6) 18/19:441-2.

29. Crockett DJ, Goudy SL. Cleft Lip & Palate. *Facial Plast Surg Clin N Am*, 2014; 1-14.
30. Nirmala SVSG, Saikrishna D. Dental concerns of children with cleft lip and palate- A review. *J Pediatr Neonatal Care*. 2018; 8(4): 172-178.
31. Geneser MK. Dentists' Evolving Role in Treating Cleft Lip and Palate - Decisions in Dentistry. Latest CE Courses Oral Surgery Pediatric Dentistry, November 1, 2017; p 1-8.
32. Precious DS, Goodday RH, Morrison AD, Davis BR. Cleft lip and palate: a review for dentists. *J Can Dent Assoc*, 2001 Dec;67(11):668-73.
33. Lee CCY, Jagtap RR and Deshpande GS. Longitudinal Treatment of Cleft Lip and Palate in Developing Countries: Dentistry as Part of a Multidisciplinary Endeavor. *J Craniofac Surg* 2014; 25(5): 1626-31.
34. Bhaskar V, Parikh D, Choudhary P & Ganesh M. Pediatric dental care for cleft lip & palate child, Part 1. *J of Ahmedabad Dent College & Hosp*, March-Aug 2010; 1(1): 13-17.
35. Kaul R, Jain P, Saha S, Sarkar S. Cleft lip and Cleft palate: role of a pediatric dentist in its management. *Int J Pedod Rehabil* 2017;2:1-6.
36. Sathyaprasad S, Jyothivelu V, Anjana A.G, Sruthy P.G & Rekha R. Assessment of preference of a pedodontist by cleft lip & palate team in multidisciplinary approach. *J of Current Research*, February 2018; 10(2): 66039-42.
37. Crosthwaite GH. Dental consideration for the child with cleft palate. *JADA*, November 1975; 91: 1042-7.
38. Jaju R & Tate AR. The role of pediatric dentistry in multidisciplinary cleft palate teams at advanced pediatric dental residency programs. *Pediatr Dent*. 2009 May-Jun;31(3):188-92.
39. Rivkin CJ, Keith O, Crawford PJM and Hathorn IS. Dental care for the patient with a cleft lip and palate. Part 2: The mixed dentition stage through to adolescence and young adulthood. *British Dental Journal*, February 2000; 188(3):131-4.
40. Jones JE, Sadove AM, Dean JA, Huebener DV. Multidisciplinary Team Approach to Cleft Lip and Palate Management (Chap 28), 2011; p 614-637.
41. Rivkin CJ, Keith O, Crawford PJM, Hathorn IS. Dental care for the patient with a cleft lip and palate. Part 1: From birth to the mixed dentition stage. *British Dent J* 2000; 188:78-83.
42. Alonso N, Amaral CER. *Cleft Lip and Palate Treatment: A Comprehensive Guide*, 2018.
43. Nihalani S. Role of Pediatric Dentists in early management of cleft lip & palate children: A Case report. *Int J Com Health and Med Res* 2016;2(4):73-75.
44. Goyal M, Chopra R, Bansal K, Marwaha M. Role of obturators and other feeding interventions in patients with cleft lip and palate: A review. *Eur Arch Paediatr Dent*, 2014;15:1-9.
45. Goyal M, Chopra R, Bansal K, Marwaha M. Role of obturators & other feeding interventions in patients with cleft lip and palate: A review. *Eur Arch Paediatr Dent*, 2014; 15:1-9
46. Turner L, Jacobsen C, Humenczuk M, Singhal VK, Moore D, Bell H. The effects of lactation education and a prosthetic obturator appliance on feeding efficiency in infants with cleft lip and palate. *Cleft palate-craniofacial journal*, september 2001;38(5): 519-524.
47. Chandna P, Adlakha V K, Singh N. Feeding obturator appliance for an infant with cleft lip and palate. *J Indian Soc Pedod Prev Dent* 2011;29:71-3.
48. Agarwal A, Rana V, Shafi S. A feeding appliance for a newborn baby with cleft lip and palate. *Natl J Maxillofac Surg*, 2010;1(1): 91-93.
49. Eruz M, Yagci A and Ozyazgan. A New Technique for Retracting the Protrusive Premaxilla With Fewer Patient Visits: Case Report. *The Cleft Palate-Craniofacial Journal*, 2018; p 1-5.
50. Losee JE, Kirschner RE, Smith DM, Lawrence CR. *Comprehensive cleft care, Family Edition*. Thieme Medical Publishers, Inc, 2015.
51. Sierra FJ, Turner C. Maxillary orthopedics in the presurgical management of infants with cleft lip and palate: Review Article. *American Academy of Ped Dentistry* 1995; 17(7): 419-423.
52. Grayson B, Santiago P, Brecht L, Cutting C. Presurgical nasoalveolar molding in infants with cleft lip and palate. *Cleft Palate Craniofac J* 1999;36:486-98.
53. Barillas I, Dec W, Warren S.M, Cutting C.B, Grayson B.H. Nasoalveolar Molding Improves Long-Term Nasal Symmetry in Complete Unilateral Cleft Lip-Cleft Palate Patients. *Plast and Reconst Surg* • March 2009; 123(3): 1002-6.
54. Shi B and Losee JE. Impact of cleft lip & palate repair on maxillofacial growth. *Intern J of Oral Science* (2014), 1-4.
55. Laxmikanth SM, Karagi T, Shetty A and Shetty S. Nasoalveolar molding: A review. *J of Advanced Clinical & Research Insights*, Nov-Dec 2014; 1(3): 108-113.

56. Ezzat C.F, Chavarria C, Teichgraeber J.F, Wei Chen J, Stratmann R.G & Gateno J. Presurgical Nasoalveolar Molding Therapy for Treatment of Unilateral Cleft Lip and Palate: A Preliminary Study. *Cleft Palate–Craniofacial J*, January 2007; 44(1): 8-12.
57. Goudy SL, Tollefson TT. Complete Cleft Care. *Cleft and Velopharyngeal Insufficiency Treatment in Children*. Thieme Medical Publishers. p 1-230.
58. Alzain I, Batwa W, Cash A, Murshid ZA. Presurgical cleft lip and palate orthopedics: An Overview. *Clinical, Cosmetic and Investigational Dentistry* 2017;9: 53–59.
59. Abdel-Rahman NI, Abbas IT and El-Kassaby MAW. A Stepwise Guide for Easy, Rapid and Accurate Oral Impression Taking for Newborn Cleft Lip/Palate Infants. *J American Science*, 2012; 8(1): 392-397.
60. Abarca M, Budzynski Y, Kovacs B, Malevez C. Multidisciplinary Approach in the Treatment of a Patient with Cleft Lip and Palate: A Case Report. *J Esthet Restor Dent* 2004; 16(2): 102–106.
61. Bennun RD, Figueroa AA. Dynamic Presurgical Nasal Remodeling in Patients With Unilateral and Bilateral Cleft Lip & Palate: a Modification to Original Technique. *Cleft Palate–Craniofacial J*, November 2006; 43(6): 639-648.
62. Shetty V, Agrawal RK, Sailer HF. Long-term effect of presurgical nasoalveolar molding on growth of maxillary arch in unilateral cleft lip and palate: randomized controlled trial. *Int J Oral Maxillofac Surg* 2017; 46: 977–987.
63. Grayson BH and Garfinkle JS. Early cleft management: The case for nasoalveolar molding. *Am J Orthod Dentofacial Orthop* 2014; 145 : 134-42.
64. Suri S & Tompson BD. A Modified Muscle-Activated Maxillary Orthopedic Appliance for Presurgical Nasoalveolar Molding in Infants with Unilateral Cleft Lip & Palate. *Cleft Palate–Craniofacial J*, May 2004; 41(3): 225-229.
65. Bennun RD, Figueroa AA. Dynamic Presurgical Nasal Remodeling in Patients With Unilateral and Bilateral Cleft Lip & Palate: a Modification to Original Technique. *Cleft Palate–Craniofacial J*, November 2006; 43(6): 639-648.
66. Retnakumari N, Divya S, Meenakumari S, Ajith PS. Nasoalveolar molding treatment in presurgical infant orthopedics in cleft lip & cleft palate patients. *Arch Med Health Sci* 2014; 2: 36-47.
67. Losee JE, Kirschner RE, Smith DM, Lawrence CR. *Comprehensive cleft care, Family Edition*. Thieme Medical Publishers, Inc, 2015.
68. Lilja J, Kalaaji A, Friede H, Elander A. Combined Bone Grafting and Delayed Closure of the Hard Palate in Patients with Unilateral Cleft Lip and Palate: Facilitation of Lateral Incisor Eruption and Evaluation of Indicators for Timing of the Procedure. *Cleft Palate–Craniofacial Journal*, January 2000; 37(1): 98-105
69. Bokhout B, Hofman FXWM, Limbeek JV, Kramer GJC, Andersen BP. Incidence of dental caries in the primary dentition in children with cleft lip and/or palate. *Caries Res* 1997; 31: 8-12.
70. Kamble S, Hiremath SS, Puranik MP, Gaikwad R, Biradar A, Gadbaal AR, Sarode SC, Sarode GS, Patil S. Dental Caries and Dental Anomalies in Children with Cleft Lip and Cleft Palate in Bengaluru City, India. *World J Dent* 2017; 8(4): 304-308.
71. Ahluwalia M, Brailsford S.R, Tarelli E, Gilbert S.C, Clark D.T, Barnard K. Dental Caries, Oral Hygiene & Oral Clearance in Children with Craniofacial Disorders. *J Dent Res* 2004; 83(2):175-179.
72. Farronato G, Kairyte L, Giannini L, Galbiati G & Maspero C. How various surgical protocols of the unilateral cleft lip and palate influence the facial growth and possible orthodontic problems? Which is the best timing of lip, palate and alveolus repair? Literature review *Stomatologija, Baltic Dent and Maxfac J*, 2014; 16(2): 53-60.
73. Manna F, Pensiero S, Clarich G, Guarneri GF & Parodi PC. Cleft Lip and Palate: Current Status From the Literature and Our Experience. *J Craniofac Surg* 2009;20(5): 1383-7.
74. Geran RG, McNamara Jr JA, Baccetti T, Franchi L and Shapiroe LM. A prospective long-term study on the effects of rapid maxillary expansion in the early mixed dentition. *Am J Orthod Dentofacial Orthop* 2006; 129: 631-40.
75. Rocha R, Ritter D.E, Locks A, de Paula L.K & Santanac R.M. Ideal treatment protocol for cleft lip and palate patient from mixed to permanent dentition. *Case Reports. Am J Orthod Dentofacial Orthop* 2012;141:S140-8.
76. Kanzaki H, Imai Y, Nakajo T, Daimaruya T, Sato A, Tachi M, Nunomura Y, Itagaki Y, Nishimura K, Kochi S, and Igarashi K. Midfacial Changes Through Anterior Maxillary Distraction Osteogenesis in Patients With Cleft Lip and Palate. *J Craniofac Surg* 2017;00: 01–06.
77. Freitas JAS, Garib DG, Oliveira TM, Lauris RCMC, Almeida ALPF, Neves LT. Rehabilitative treatment of cleft lip & palate: Experience of the Hospital for Rehabilitation of Craniofacial Anomalies – Part 3: Oral & Maxfac Surgery. *J Appl Oral Sci*. 2012; 20(6):673-9.
78. Rangeeth BN, Ahmed S, Cholan R, Russia M, Mohammed Raffi AJ. Role of the pediatric dentist and prosthodontist in early cleft management: Presentation of two case reports. *SRM J Res Dent Sci* 2013;4:173-6.



79. Kasten EF, Schmidt SP, Zickler CF, Berner E, Damian LAK, Christian GMD, Workman H, Freeman M, Farley MD, Hicks TL. Team Care of the Patient with Cleft Lip and Palate. *Curr Probl Pediatr Adolesc Health Care*, May/June 2008: p 138-158.
80. Katge, Farhin A, Rusawat, Bhavesh D, Shetty, Ashveeta D, Shitoot, Abhinav P. Role of a paediatric dentist in the management of cleft lip and palate – A review and A case report. *Clinical Dentistry*, Sep 2015; 9(9), 8-13.
81. Abu-Hussein M, Watted N, Emodi O, Zere E. Role of Pediatric Dentist - Orthodontic In Cleft Lip and Cleft Palate Patients. *IOSR Journal of Dental and Medical Sciences*, Nov. 2015; 14(11: Ver.X): 61-68.
82. Sabarinath VP, Hazarey PV, Ramakrishna Y, Vasanth R, Girish K. Caring for cleft lip and palate infants: Impression procedures and appliances in use. *The J Indian Prosth Society*, April 2009; 9(2): 76-80.