



ISSN NO. 2320-5407

Journal Homepage: - www.journalijar.com

INTERNATIONAL JOURNAL OF ADVANCED RESEARCH (IJAR)

Article DOI: 10.21474/IJAR01/12040
DOI URL: <http://dx.doi.org/10.21474/IJAR01/12040>



INTERNATIONAL JOURNAL OF
ADVANCED RESEARCH (IJAR)
ISSN 2320-5407
Journal Homepage: <http://www.journalijar.com>
Journal DOI: 10.21474/IJAR01

RESEARCH ARTICLE

GINGIVAL SQUAMOUS CELL CARCINOMA- A CASE REPORT

Dr. Seema Patil¹, Dr. Manmita Das², Dr. Asha R. Iyengar³, Dr. Subash B.V⁴, Dr. Ritika Agarwal⁵ and Dr. Aparna S. Namboothiri⁶

1. Professor and Head of Department, Department of Oral Medicine and Radiology, DA Pandu Memorial RV Dental College, Bangalore, Karnataka, India.
2. Postgraduate, Department of Oral Medicine and Radiology, DA Pandu Memorial RV Dental College, Bangalore, Karnataka, India.
3. Professor, Department of Oral Medicine and Radiology, DA Pandu Memorial RV Dental College, Bangalore, Karnataka, India.
4. Reader, Department of Oral Medicine and Radiology, DA Pandu Memorial RV Dental College, Bangalore, Karnataka, India.
5. MDS, Senior Resident, Department of Dentistry, Patna Medical College and Hospital, Bihar, India.
6. Postgraduate, Department of Oral Medicine and Radiology, DA Pandu Memorial RV Dental College, Bangalore, Karnataka, India.

Manuscript Info

Manuscript History

Received: 10 September 2020
Final Accepted: 15 October 2020
Published: November 2020

Abstract

Gingival squamous cell carcinoma (GSCC) is a relatively rare malignant neoplasm of the oral cavity. It represents less than 4-6.3% of diagnosed intraoral carcinomas. GSCC may cause odontogenic symptoms such as mobility and pain of teeth mimicking inflammatory conditions such as periodontitis. Early diagnosis and prompt management of GSCC is of paramount importance as the prognosis of gingival squamous cell carcinoma is mainly dependent on these factors. Further, as, GSCCs spread rapidly to involve the underlying bone, the role of dentists in early detection of gingival squamous cell carcinoma cannot be undermined. The present report describes a rare case of GSCC in a 31 year old male. The detailed recording of the case history and clinical examination, radiographic, and laboratory investigations, along with review of similar conditions led to the diagnosis, and treatment was initiated.

Copy Right, IJAR, 2020,. All rights reserved.

Introduction:-

Worldwide, oral carcinomas are the sixth most common malignancies¹. In India, oral carcinomas account for more than 50% of all carcinomas¹. Gingival squamous cell carcinomas (GSCC) account for 4-6.3% of all the oral carcinomas^{2,3}. GSCC generally affects males older than 65 years of age^{4,5}. Lesion affecting the gingiva are often confused with inflammatory conditions affecting the periodontium clinically. As the thickness of gingiva overlying the alveolar bone does not exceed 2-3 mm, GSCC has a strong predilection for bone invasion, especially in the posterior alveolar ridge and retromolar region⁶. In this article, a case of GSCC of the left mandible, occurring in a young male which was initially misdiagnosed as localized severe periodontitis is discussed.

Corresponding Author:- Dr. Manmita Das

Address:- Postgraduate, Department of Oral Medicine and Radiology, DA Pandu Memorial RV Dental College, Bangalore, Karnataka, India.

Case report:

A 31 year old male patient reported to the department of Oral Medicine and Radiology with a chief complaint of growth in the lower left back teeth region since 2 weeks. Patient gave history of mild discomfort and mobility in the lower left back teeth region since one month. As the symptoms persisted for more than 15 days, he had consulted a private dental practitioner wherein extraction of 36 and 37 was performed without prior radiographic investigation of the site. He was also prescribed antibiotics (Amoxicillin and Clavulanic acid-625 mg twice daily and Metronidazole 400mg thrice for 5 days) .Following which, he noticed a growth in the same region gradually increasing in size for which he was advised a biopsy and an OPG was also taken .He reported to the institution with the OPG for second opinion. Patients medical history was unremarkable, habit history suggested that he used to smoke 4 cigarettes per day for 5-6 years and had quit 4 years ago.His general examination did not reveal any abnormalities.

Extra-oral examination of the area of chief complaint revealed a single ipsilateral submandibular lymph node measuring <3 cm. It was non tender, firm and fixed. Intraorally, a proliferative growth involving the gingiva, alveolar mucosa and sulcus was noted extending from 35 to 38 region on both the buccal and lingual aspect. The surface appeared erythematous along with sloughing in certain areas. It was firm, non tender and indurated near the base of the tongue. There was absence of bleeding or pus discharge. On hard tissue examination, 35 was grade 1 mobile and 36, 37 were missing.

OPG revealed a diffuse radiolucency with ragged borders measuring about 3X 2 cms in the left body of the mandible. Antero-posteriorly, it extended from distal aspect of 35 to mesial aspect of 38. Superoinferiorly,it extended from the alveolar crest of 35 and 38 to 2cms inferiorly.The internal structure was completely radiolucent. Complete loss of lamina dura was noted with respect to 35 and 38.

The following differential diagnoses were considered

1. Primary intraosseous SCC of the left mandible
2. Gingival carcinoma of the lower left alveolar mucosa
3. Intraosseous Malignant minor salivary gland tumor

All the mentioned differential diagnosis show almost similar kind of clinical appearance like

1. History of localized mobility of teeth,
2. Involvement of posterior mandible mostly,
3. In relatively older male patients,
4. Lymphadenopathy,
5. Mild pain,
6. Absence of lesion prior to extraction,

Following extraction rapid growth etc

However, in the present case the patient was surprisingly younger.

Patient was advised a CT scan which revealed radiolucency with irregular cortical destruction involving the body of the mandible measuring about 2.7 cms in length. Perimandibular tissues presented with inflammatory changes and mild submandibular lymphadenopathy was also observed.

Incisional biopsy was performed. Histopathologic evaluation revealed dysplastic stratified squamous epithelium and underlying connective tissue. The dysplastic epithelial cells were invading into the connective tissue in the form of islands of varying sizes. The cells showed a moderate degree of atypia including cellular and nuclear pleomorphism, nuclear hyper chromatism and mitotic figures. Keratin pearls and individual cell keratinization were observed. The surrounding connective tissue contained many chronic inflammatory cells and blood vessels. The invasion involved the entire thickness of the given specimen.

Patient was then referred to a tertiary cancer institute for further evaluation and management.

Discussion:-

SCC is defined as a malignant epithelial neoplasm exhibiting squamous differentiation characterized by the formation of keratin and/or the presence of intercellular bridges. A review shows that the most common etiologic factors associated with oral SCC are smoking and smokeless tobacco. In contrast to oral SCC, GSCC is weakly associated with tobacco and alcohol and its etiology is not well established. In the present case, the patient was currently a non-smoker. He was however a smoker for 5 years before and had quit the habit 4 years ago. It is well established fact that the effects of smoking may be evident for almost a decade after complete stoppage of the habit. The age of occurrence of GSCC is slightly higher than SCC occurring at other sites in the oral cavity. However, in the present case, it was observed in a young male who was 31 years of age. GSCC generally presents as an intraoral mass with a granular, papillary, or verrucous surface or ulceration. Patients may also complain of ill-fitting dentures and mobility of teeth. The lesion often simulates advanced periodontitis, associated with minimal pain, and may lead to a diagnostic delay^{8,9}. In the present case, GSCC presented with features of mild discomfort and mobility of the teeth⁹. It was initially misdiagnosed as a periodontal disease. The extraction of the teeth probably lead to sudden increase in growth of the tumor. Because of the proximity of the underlying alveolus, early bone invasion is a frequent occurrence¹⁰.

Muller & Slootweg¹¹ have described two basic patterns of bone involvement. In the erosive pattern, the tumor advances on a broad front, While the infiltrative pattern shows irregular, focal infiltration by tumor cells into the cancellous bone. In the present case, infiltrative pattern of involvement was observed. Radiographic features show diffuse radiolucency with ragged border measuring about 3X 2 cms in the left body of the mandible. Extending Antero-posteriorly from distal surface of 35 to mesial surface of 38 and Supero-inferiorly, extending from the alveolar crest of 35 and 38 and extends 2cms inferiorly. The internal structure was completely radiolucent. Loss of lamina dura of 35 and 38 was noted.

There are five subtle radiological differences between Floating tooth appearance seen in periodontal disease and GSCC, in periodontal disease radiolucent area doesn't contain trabecular remnants whereas in GSCC it may be present. Alveolar bone margins are smooth, distinct with punched out appearance in periodontal disease and ragged with wide zone of transition between free margin and normal bone is seen in GSCC. Reactive sclerotic bone may be seen at the margin in periodontal disease whereas in GSCC marginal sclerosis is often absent. In GSCC, the bone loss is limited to the affected area but in periodontal disease Adjacent teeth are often affected. Gingival carcinomas are currently managed by surgical resection. In cases of advanced operable cancers, preoperative chemo-radiotherapy and radical surgery may be effective. Aggressive resection would be advised when,

1. Infiltrative bone defect is identified.
2. Lesion remains undiagnosed for a few months after an inadvertent extraction.
3. Secondary surgical manipulation like curettage of a non-healing tooth socket.

Prognosis is generally moderate to poor depending on stage of diagnosis of disease. The overall 5-year survival rate is 50.7%. Factors affecting survival include, a) Bone invasion of the primary lesion, b) Neck node metastasis and c) Local recurrence. It is suggested that setting a broad surgical field and enforcing preventive neck dissection, can improve outcome. GSCC differs from other forms of SCC involving the oral cavity. It frequently mimics localized periodontal disease resulting in misdiagnoses and is generally discovered after extraction of teeth. GSCCs are potentially life-threatening conditions and the survival rate of this condition is quite disappointing. Hence, it is of paramount importance that the lesion be diagnosed early to initiate treatment, prevent metastasis, and thereby improve the prognosis.

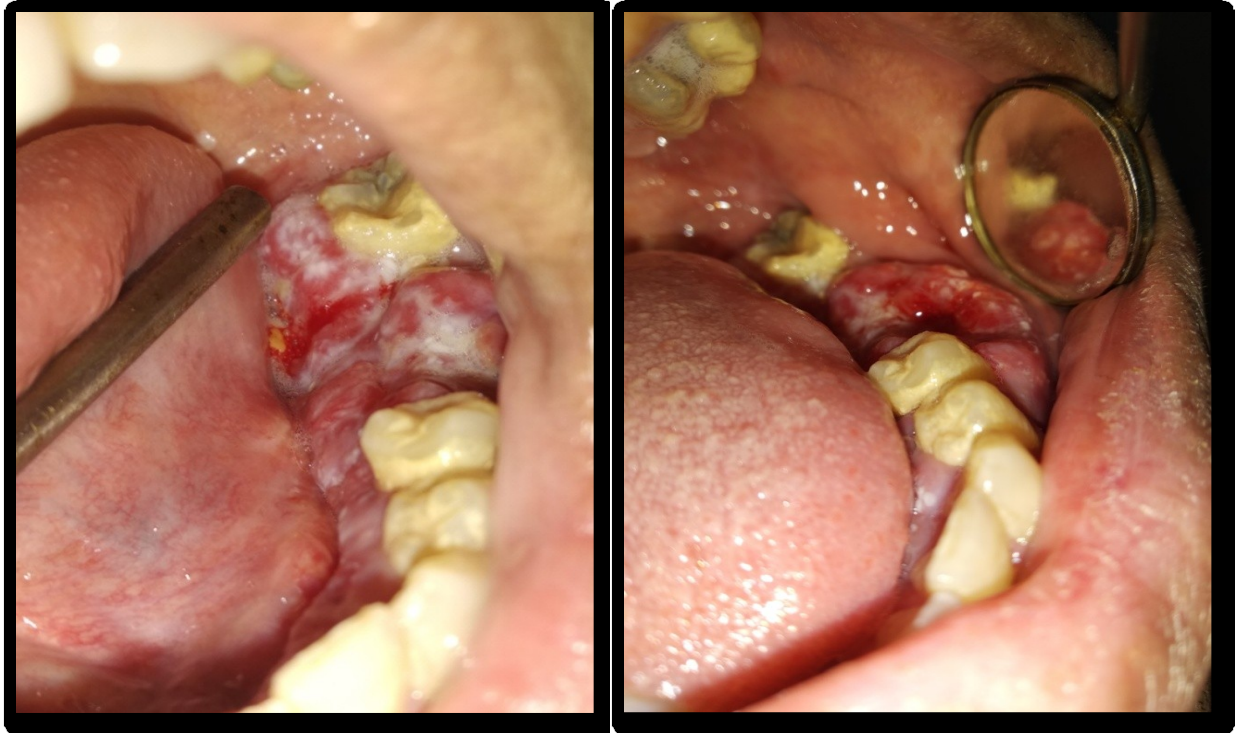

Fig 1:-Intraoral picture depicts proliferative growth involving the gingiva, alveolar mucosa and sulcus extending from 35 to 38 region on both the buccal and lingual aspect.

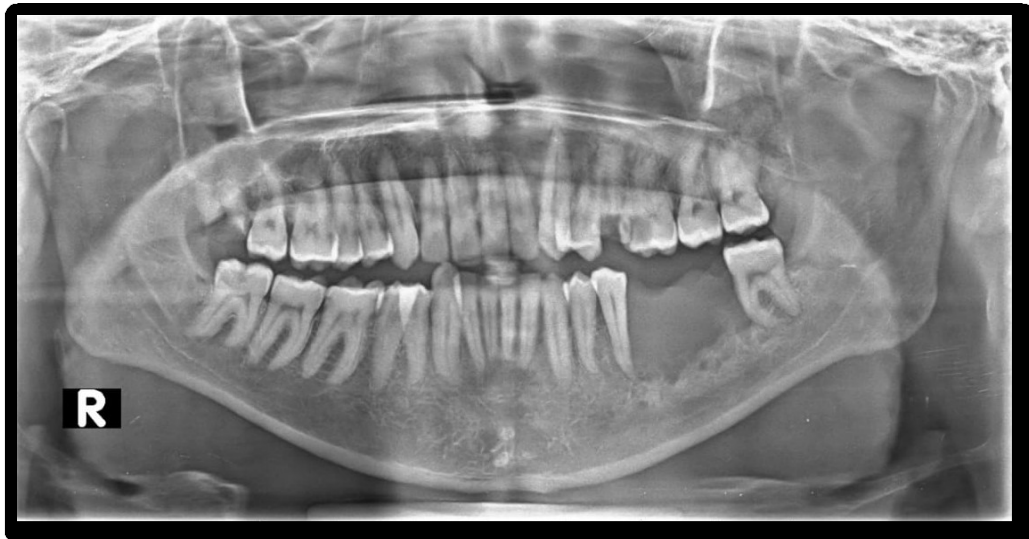

Fig 2:- OPG revealed a diffuse radiolucency with ragged borders in the left body of the mandible extending antero-posteriorly, from distal aspect of 35 to mesial aspect of 38 and superoinferiorly, from the alveolar crest of 35 and 38 to 2cms inferiorly.

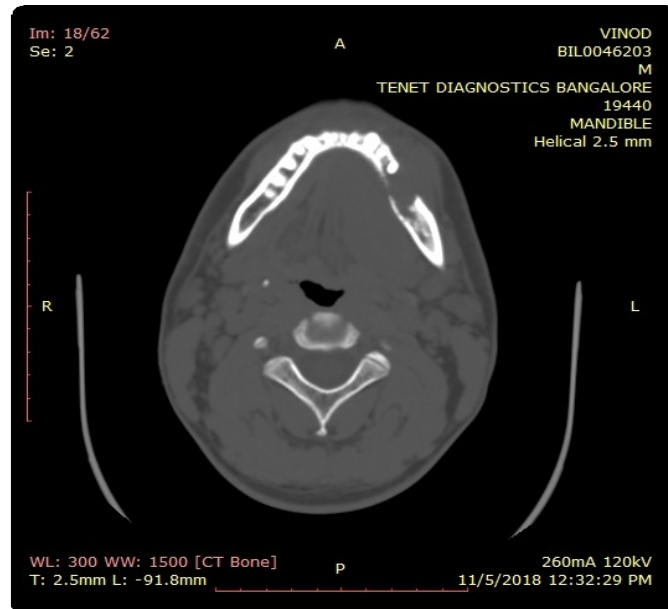


Fig 1:- a CT Scan which revealed a radiolucency with irregular cortical destruction involving the body of the mandible measuring about 2.7 cms in length and loss of buccal and lingual cortical plate in 36,37 region.

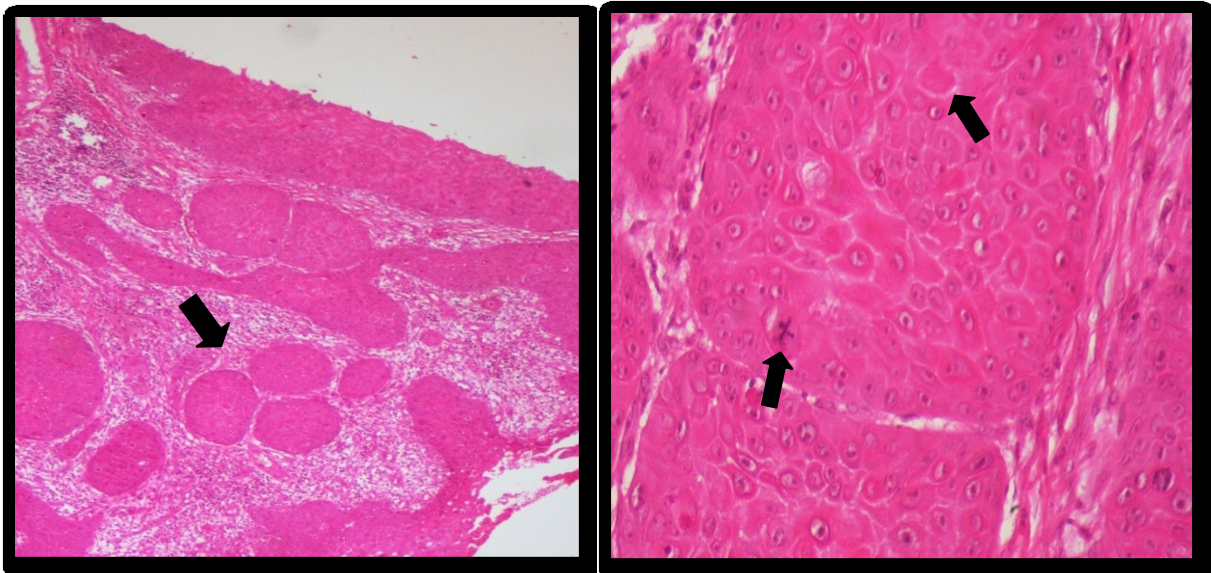


Fig 1:- The dysplastic epithelial cells are invading into the connective tissue in the form of islands of varying sizes (H&E,4X). Malignant cells showing mitotic figures and individual cell keratinization with keratin pearls are observed (H&E,20X).

References:-

1. Parkin DM, La"ara" E, Muir CS. Estimates of the worldwide frequency of sixteen major cancers in 1980. *Int J Cancer* 1988;41:184-197.
2. Casiglia J, Woo SB. A comprehensive review of oral cancer. *Gen Dent* 2001;49:72-82.
3. Seoane J, Varela-Centelles PI, Walsh TF, Lopez-Cedrun JL, Vazquez I. Gingival squamous cell carcinoma: Diagnostic delay or rapid invasion? *J Periodontol* 2006;77:1229-33.
4. Koduganti RR, Sehrawat S, Reddy PV. Gingival squamous cell carcinoma: A diagnostic impediment. *J Indian Soc Periodontol* 2012;16:104-7.
5. Rajendran R, Shivapathasundaram B, editors. *Shafer's Textbook of Oral Pathology*. 6th ed. India: Elsevier; 2009.

6. KALAVREZOS ND, GRATZ KW, SAILER HF, SETHAL WA. Correlation of imaging and clinical features in the assessment of mandibular invasion of oral carcinomas. *Int J Oral Maxillofac Surg* 1996; 25:439–445.
7. Soo KC, Spiro RH, King W, Harvey W, Strong EW. Squamous carcinoma of the gums. *Am J Surg* 1988;156:281-285.
8. Lee JJ, Cheng SJ, Lin SK, Chiang CP, Yu CH, Kok SH. Gingival squamous cell carcinoma mimicking a dentoalveolar abscess: Report of a case. *J Endod* 2007;33:177-180.
9. Gallagher CS Jr, Svirsky JA. Misdiagnosis of squamous cell carcinoma as advanced periodontal disease. Report of a case. *J Oral Med* 1984;39:35-38.
10. SUZUK, SHINGAKI S, NOMURA T, NAKAZIMA T. Oral carcinomas detected after extraction of teeth: a clinical and radiographic analysis of 32 cases with special reference to metastasis and survival. *Int J Oral Maxillofac Surg* 1998;27: 290–294.
11. MULLER H, SLOOTWEG PJ. Mandibular invasion by oral squamous cell carcinoma. *J Cranio Maxillofac Surg* 1989; 17:69–74.
12. Misra S, Chaturvedi A, Misra NC. Management of gingivobuccal complex cancer. *Ann R Coll Surg Engl* 2008;90:546-53.
13. Gomez D, Faucher A, Picot V, Siberchicot F, Renaud-Salis JL, Bussièrès E, et al. Outcome of squamous cell carcinoma of the gingiva: A follow-up study of 83 cases. *J Craniomaxillofac Surg* 2000;28:331-5.
14. Posner MR, Lefebvre JL. Docetaxel induction therapy in locally advanced squamous.
15. Rajendran R, Sivapathasundaram B. In Shafer's text-book of Oral pathology, 5th ed, India: Reed-Elsevier India Private Limited; 2006.p. 143.
16. Neville BW, Damm DD, Allen CM, Bouquot JE. Oral and maxillofacial pathology (2nd ed), Philadelphia: Saunders; 2002.