



Journal Homepage: - www.journalijar.com

INTERNATIONAL JOURNAL OF ADVANCED RESEARCH (IJAR)

Article DOI: 10.21474/IJAR01/11628

DOI URL: <http://dx.doi.org/10.21474/IJAR01/11628>



RESEARCH ARTICLE

EVALUATING THE THREE DIMENSIONAL SPREAD OF ANTERIOR LOOP OF MANDIBULAR NERVE FOR PREDICTABLE IMPLANT INSERTION IN MANDIBLE - A CBCT ANALYSIS ON NORTH-INDIAN POPULATION

Dr. Aamir Bashir¹, Dr. Adil Fayaz¹ and Dr. Sandeep Kaur Bali²

1. Post-Graduate Student, Department of Prosthodontics, Govt. Dental College & Hospital, Srinagar, Jammu & Kashmir, India.
2. Professor and Head, Department of Prosthodontics, Govt. Dental College & Hospital, Srinagar, Jammu & Kashmir, India.

Manuscript Info

Manuscript History

Received: 30 June 2020

Final Accepted: 31 July 2020

Published: August 2020

Abstract

Introduction: Implant placement requires an understanding of regional anatomy and a precise knowledge of the location of important anatomic structures such as the inferior alveolar nerve and maxillary sinus. At its anterior exit the inferior nerve creates a loop before exiting through the mental foramen. The dimensions of the anterior loop of inferior alveolar nerve are variable among individuals. This study was undertaken to assess the variability in the dimensions of this loop, so as to achieve predictable implant placement in the area of mental foramen.

Materials and Methods: Eighty one CBCT scans of patients after exclusion from a sample of hundred CBCTs were used in the study. Individual sections were evaluated for the greatest dimension of the loop in the antero-posterior and supero-inferior direction. The greatest dimension was transferred to the sagittal plane, and measured perpendicular to the inferior border of mandible. T-test was used for statistical analysis of the data.

Results: 68 of the 81 cases studied had an anterior loop in the mandibular nerve. The mean value obtained in males for the antero-posterior dimension was 3.65 mm on the right side, and 3.56 on the left side. For the females the value obtained was 3.02, and 2.91 mm for right and left side. In the supero-inferior dimension the corresponding values for males for the right and left side were 4.28mm and 4.18 mm. For the females group the values obtained were 3.24 mm and 3.17 on the right and left side. The results were statistically significant with p value <0.05.

Conclusion: A minimum distance of 6 mm is recommended to prevent damage to the anterior loop. Using the CBCT data for treatment planning is however the gold standard and should be prioritized over using average values for implant insertion.

Copy Right, IJAR, 2020. All rights reserved.

Corresponding Author:- Dr. Aamir Bashir

Address:- Post-Graduate Student, Department of Prosthodontics, Govt. Dental College & Hospital, Srinagar, Jammu & Kashmir, India.

Introduction:-

The inferior alveolar nerve bifurcates in the area of the mandibular premolars into two branches, the incisive nerve that runs anteriorly through the bone and the mental nerve that exits through a small opening called mental foramen apical to the roots of mandibular premolar teeth¹. The mental nerve exits the foramen after moving buccally, anteriorly or superiorly or a combination of the above. This gives rise to the anterior loop of mental nerve, which is a structure of vital importance during treatment planning for implant placement. A safe distance must certainly be maintained between the mental nerve loop and the apical aspect of the implant osteotomy to avoid any injury to the mental nerve that can result in disruption of sensory stimuli from the region of chin, lip, labial mucosa and mucosa of anterior gingiva.

The mental portion of inferior alveolar nerve is classified as straight, vertical and anterior loop^{2,3}. Among these anatomic variants, the anterior loop has been the focus of much research, owing to its variable positioning in the area. Researchers have studied the anterior loop using different modalities including direct measurement on cadavers, OPGs, CT and CBCT. Values ranging from 0.11 to 11 mm were reported along-with a prevalence of 7-88%⁴. More research is required in identifying the presence and position of the anterior loop that can help guide the practitioners even in the absence of CBCT for safe preparation of implant osteotomies.

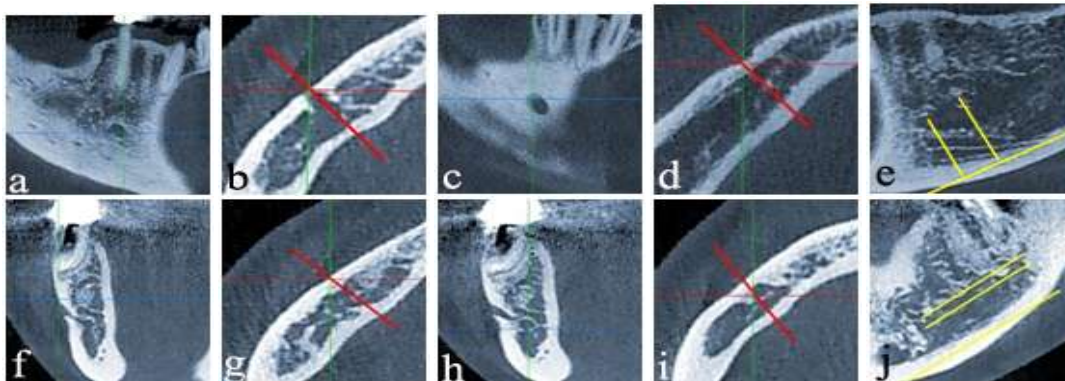
Thus this study was undertaken to identify the prevalence and dimensions of the anterior loop of mental nerve in a north Indian population, and to determine a safe distance for implant placement in the area of mental foramen.

Materials and Methods:-

This cross sectional study was carried out on 100 CBCT scans that had been obtained for other purposes, like diagnosis, orthodontics, oral surgical requirements, implant planning, etc. The scans were taken by the same radiology technician. Images of inadequate quality were discarded, as were scans with unerupted teeth or any pathology in the region of mandibular premolars, as well as long edentulous areas in the area of premolars. Cases with implants placed in the area of premolars were also discarded. Thus we were left with 81 cases that were included in the study. The sagittal, cross-sectional, and multiplanar reformatted images of the patients were carefully evaluated. The ALL was evaluated in the respective sections of each CBCT image and the dimension was transferred to the buccal surface of mandible, perpendicular to the sagittal plane, using the software. This was necessary owing to three dimensional curvature of the foramen that limited the ability to visualize the entire length of the loop in a single section. The distance between the lines projected onto the sagittal plane was measured to identify the antero-posterior and supero-inferior position of the foramen, in relation to the mandibular canal.

Results:-

According to the study 68 of the 81 cases studied had an anterior loop in the mandibular nerve. The mean value obtained in males for the antero-posterior dimension was 3.65 mm with a standard deviation of 1.02 on the right side, and 3.56 with standard deviation of 0.99 on the left side. For the females the value obtained was 3.02 mm with standard deviation of 0.87, and 2.91 mm with standard deviation of 0.84 respectively for the right and left side. In the supero-inferior dimension the corresponding values for males for the right and left side were 4.28mm (SD 1.16) and 4.18 mm (SD 1.15). For the females group the values obtained were 3.24 mm (SD 0.86) and 3.17 (SD 0.87) on the right and left side. Appropriate t-test (paired t-test for intra-group and independent samples t-test for inter-group variables) was used for intra- and inter- group comparison. The differences were found to be statistically significant for both intra- and inter- group comparison, with p value <0.05.



Antermost point identified (a) and transferred (red line) to the buccal surface (b), posteriormost point identified (c) and transferred (red line) to the buccal surface (d) the distance between the two points measured in the sagittal plane, perpendicular to a tangent to the inferior border of mandible(e).

Superiormost point identified (f) and transferred (red line) to the buccal surface (g), inferiormost point identified (h) and transferred (red line) to the buccal surface (i), distance between the two points measured in the sagittal plane parallel to a tangent to the inferior border of mandible (j).

Discussion:-

The aim of this study was to evaluate whether an average safe distance between the mental

Discussion:-

The aim of this study was to evaluate whether an average safe distance between the mental foramen and apical extent of an implant osteotomy can be established based on CBCT study, and whether the results of this study correlate with the previously established values in other studies.

Although panoramic radiography is a commonly used radiographic diagnostic tool, its reliability is subject to question due to its two dimensional nature, and superimposition of anatomic structures^{5,6}. The incidence of anterior loop reported from OPG based studies ranges from 12-40%, which is much lesser than the numbers reported from CBCT studies and study of human cadavers. Values obtained from cadaver studies include 59%⁷, 61.5%⁸, 62.7%⁹, 88%¹⁰. Similarly CBCT analysis has revealed a wide range of 7% by Jacobs et al¹¹, 21.7% by Sahman et al⁴, 82%¹². Uchida et al² evaluated the difference between measurements on CBCT scans of cadavers and direct measurements on the same mandibles and found very small differences. Thus it can be said that the values obtained are nearly as reliable as direct measurements.

The value of 76.5% obtained in the present is in agreement with values obtained in previous studies. The average measurement obtained was 2.5 mm¹³, 4.13 mm¹⁰ and 5 mm¹⁴ in OPG based studies. CBCT studies reported a mean of 2.09 mm¹⁵, 3.54 mm¹⁶, 2.1 mm⁴, while the cadaver studies reported mean values of 1.5 mm⁹, 2.69 mm¹⁷ and 5 mm¹⁸. In the present study the anterior loop was measured separately in the antero-posterior plane and supero-inferior direction by projecting it perpendicularly onto the buccal surface of each reconstructed image. The difference in values obtained in different studies can be attributed to the ethnic difference in populations, sample size, measurement methods used, and operator bias.

In the present study the values reported for the right and left side were different with statistical significance ($p < 0.05$). This finding is not in agreement with reports from studies done previously. The difference in values of male and female population is also statistically significant ($p < 0.05$), which is in agreement with the results from previous studies. The study done by Wong and Patil, however, reported no significant difference due to sex or ethnicity¹⁹.

Conclusion:-

A mean distance of 6 mm is recommended as per this study to prevent damage to the inferior alveolar nerve branches during implant osteotomy preparations in more than 95% of the population. Using a CBCT to treatment plan is the best option, as arbitrary distance of 6 mm can result in significant compromise of vertical bone available for placing an implant in the premolar area.

References:-

1. Neves FS, Torres MG, Oliveira C, Campos PS, Crusoe-Rebello I. Lingual accessory mental foramen: a report of an extremely rare anatomical variation. *J Oral Sci.* 2010;52:501–503.
2. Uchida Y, Noguchi N, Goto M, et al. Measurement of anterior loop length for the mandibular canal and diameter of the mandibular incisive canal to avoid nerve damage when installing endosseous implants in the interforaminal region: a second attempt introducing cone beam computed tomography. *J Oral Maxillofac Surg.* 2009;67:744–750.
3. Kuzmanovic DV, Payne AG, Kieser JA, Dias GJ. Anterior loop of the mental nerve: a morphological and radiographic study. *Clin Oral Implants Res.* 2003;14:464–471.

4. Sahman H, Sisman Y. Anterior Loop of the Inferior Alveolar Canal: A Cone Beam Computerized Tomography Study of 494 Cases. *J Oral Implantol.* 2016; 42(4):332-336
5. Sahman H, Sekerci AE, Sisman Y, Payveren M. Assessment of the visibility and characteristics of the mandibular incisive canal: cone beam computed tomography versus panoramic radiography. *Int J Oral Maxillofac Implants.* 2014;29:71–78.
6. Scarfe WC, Eraso FE, Farman AG. Characteristics of the Orthopantomograph OP 100. *Dentomaxillofac Radiol.* 1998;27:51–57.
7. Solar P UC, Frey G, Matejka M. A classification of the intraosseous paths of the mental nerve. *Int J Oral Maxillofac Implants.* 1994;9:339–344.
8. Hu KS, Yun HS, Hur MS, Kwon HJ, Abe S, Kim HJ. Branching patterns and intraosseous course of the mental nerve. *J Oral Maxillofac Surg.* 2007;65: 2288–2294.
9. Uchida Y, Yamashita Y, Goto M, Hanihara T. Measurement of anterior loop length for the mandibular canal and diameter of the mandibular incisive canal to avoid nerve damage when installing endosseous implants in the interforaminal region. *J Oral Maxillofac Surg.* 2007;65: 1772–1779.
10. Neiva RF, Gapski R, Wang HL. Morphometric analysis of implantrelated anatomy in Caucasian skulls. *J Periodontol* 2004;75:1061–1067.
11. Jacobs R, Mraiwa N, vanSteenberghe D, Gijbels F, Quiryneen M. Appearance, location, course, and morphology of the mandibular incisive canal: an assessment on spiral CT scan. *Dentomaxillofac Radiol.* 2002;31:322– 327.
12. Lu CI, Won J, Al-Ardah A, Santana R, Rice D, Lozada J. Assessment of the anterior loop of the mental nerve using cone beam computerized tomography scan. *J Oral Implantol.* 2015;41:632–639.
13. Bavitz JB, Harn SD, Hansen CA, Lang M. An anatomical study of mental neurovascular bundle-implant relationships. *Int J Oral Maxillofac Implants.* 1993;8:563–567.
14. Misch CE, Crawford EA. Predictable mandibular nerve location—a clinical zone of safety. *Int J Oral Implantol.* 1990;7:37–40.
15. Li X, Jin ZK, Zhao H, Yang K, Duan JM, Wang WJ. The prevalence, length and position of the anterior loop of the inferior alveolar nerve in Chinese, assessed by spiral computed tomography. *Surg Radiol Anat.* 2013; 35:823–830.
16. Parnia F, Moslehifard E, Hafezeqoran A, Mahboub F, Mojaver- Kahnamoui H. Characteristics of anatomical landmarks in the mandibular interforaminal region: a cone-beam computed tomography study. *Med Oral Patol Oral Cir Bucal.* 2012;17:e420–e425.
17. Arzouman MJ, Otis L, Kipnis V, Levine D. Observations of the anterior loop of the inferior alveolar canal. *Int J Oral Maxillofac Implants.* 1993;8:295–300.
18. Hwang K, Lee WJ, Song YB, Chung IH. Vulnerability of the inferior alveolar nerve and mental nerve during genioplasty: an anatomic study. *J Craniofac Surg.* 2005;16:10–14
19. Wong SK, Patil PG. Measuring Anterior Loop Length of the Inferior Alveolar Nerve to Estimate Safe Zone in Implant Planning: A CBCT Study in a Malaysian Population. *J Prosthet Dent.* 2018;120(2):210-213.