



Journal Homepage: -www.journalijar.com

INTERNATIONAL JOURNAL OF ADVANCED RESEARCH (IJAR)

Article DOI:10.21474/IJAR01/11615
DOI URL: <http://dx.doi.org/10.21474/IJAR01/11615>



RESEARCH ARTICLE

A RARE CASE OF PERINEPHRIC ABSCESS SQUEELED INTO ACUTE INTESTINAL OBSTRUCTION

Manoj Kumar Chaudhary¹, Mrinal Shankar¹, Akhilesh Kumar Patel¹, Sunil Gujar¹, Priya Kushwah² and
Suhail Muhammed¹

1. General Surgery, Senior Resident, Aiiims Raipur, Chhattisgarh, India.
2. Surgical Oncology, Senior Resident, Aiiims Bhopal, Madhya Pradesh, India.

Manuscript Info

Manuscript History

Received: 30 June 2020
Final Accepted: 31 July 2020
Published: August 2020

Key words:-

Perinephric Abscess, Intestinal
Obstruction, Gerota's Fascia,
Staphylococcus Aureus

Abstract

Introduction: A perinephric abscess is a collection of suppurative material in the perinephric space. Perinephric abscess results from perirenal fat necrosis. A perinephric abscess is a life-threatening entity that is usually a complication of urologic infection. Most perirenal abscesses were due to prolonged bacteremia with Staphylococcus aureus followed by hematogenous seeding before the era of antibiotics. More than 75% of perinephric abscesses are now due to complications of urinary tract infection (UTI).

Case report: A 50 years old male came in our emergency department with complaint of on and off pain in left flank of abdomen for 1 month, Burning micturation for 15 days, intermittent fever for 7 days. Initially empirical medical treatment with DJS done but symptom not relieved and feature of obstruction developed. Then on exploratory Laprotomy omentum was attached to wall of retroperitoneal perinephric abscess which was about to burst. This omental adhesion was causing acute intestinal obstruction due to small bowel compression. Then adhesiolysis & repositioning of the omentum done and I&D done via retroperitoneal approach. Patient got relieved after surgery and passed motion on 2nd post op day and discharged on 5th day.

Conclusion: Even uncomplicated urinary tract infection can land up into life-threatening complication such as perinephric abscess, acute obstruction so we kept in mind about this complication.

Copy Right, IJAR, 2020.. All rights reserved.

Introduction:-

A perinephric abscess is a collection of suppurative material in the perinephric space^[1]. Perinephric abscess results from perirenal fat necrosis^[2]. A perinephric abscess is a life-threatening entity that is usually a complication of urologic infection. Most perirenal abscesses were due to prolonged bacteremia with Staphylococcus aureus followed by hematogenous seeding before the era of antibiotics^[3]. More than 75% of perinephric abscesses are now due to complications of urinary tract infection (UTI). A perinephric abscess is more diffuse and affects the renal capsule and Gerota's fascia. These abscesses can extend from the Gerota's fascia into the psoas and transversalis muscles as well as the peritoneal cavity and the pelvis. Perinephric abscesses carry a mortality rate of up to 56%. This rate partly is due to long delays in diagnosis and the comorbid conditions. Even with modern surgical therapy, the mortality rate is 8-22% and significant morbidity occurs in 35% of patients.

Corresponding Author:- Akhilesh Kumar Patel

Address:- General Surgery, Senior Resident, Aiiims Raipur, Chhattisgarh, India.

Case Presentation:

A 50 years old male came in our emergency department with complaint of on and off pain in left flank of abdomen for 1 month, Burning micturation for 15 days, intermittent fever for 7 days. On examination patient was conscious, well oriented, average built, P-68/minute regular, BP-138/86mm Hg, normal temperature. Per abdomen examination- it was soft nontender, Bowel sound present, normal genitalia, Passed flatus and motion. Investigation- Total leucocyte count [TLC] was 11800/mm³, Platelets was 3 lac, In Urine microscopy-8-10 pus cells/hpf. USG whole abdomen suggestive of mild Left hydronephrosis. Provisional diagnosis-Urinary tract infection with Left hydronephrosis. Now we start empirical antibiotic and syrup alkacitol. After two days patient had no improvement instead he complaint pain in left side abdomen and continuous fever for 2 days. On examination- General condition was poor, febrile, pulse-114/minute, BP-108/70mmHg, Per abdomen examination-fullness in left hypochondrium & left lumbar region and tenderness in these area. Per rectal with in normal limit. On blood investigation TLC-18,000/mm³, creatinine-3.2mg/dl (previous was 1.2), USG whole abdomen suggestive of left perinephric collection with hydronephrosis. Now we suspect perinephric abscess with pyonephrosis. Plan for PCN and left side DJ stenting. During surgery fluoroscopy showed ruptured kidney hence dye was extravasated on medial aspect of Left kidney later on trickled down along the psoas muscle [FIGURE 1A]. In Nephroscopy – ruptured medial wall (communicated with perinephric space) of left kidney (old) dilated calyces filled with pus rest of kidney tissue normal [FIGURE 1B]. Then suction and saline wash done and DJS was placed and a nephrostomy drain kept in left kidney. On post operative day 1- pus mixed urine (800 ml) in nephrostomy. On day 2 - 650ml urine (clear) in nephrostomy drain. But patient not relieved and complaint of distention of abdomen and not passed flatus. X-Ray Erect abdomen showed multiple air fluid level [FIGURE 2]. Now we plan exploratory laparotomy and I&D [incision and drainage]. In exploratory Laparotomy omentum was attached to wall of retroperitoneal perinephric abscess which was about to burst. This omental adhesion was causing acute intestinal obstruction due to small bowel compression [FIGURE 3]. Then adhesiolysis & repositioning of the omentum done and I&D done via retroperitoneal approach. Patient got relieved after surgery and passed motion on 2nd post op day and discharged on 5th day.

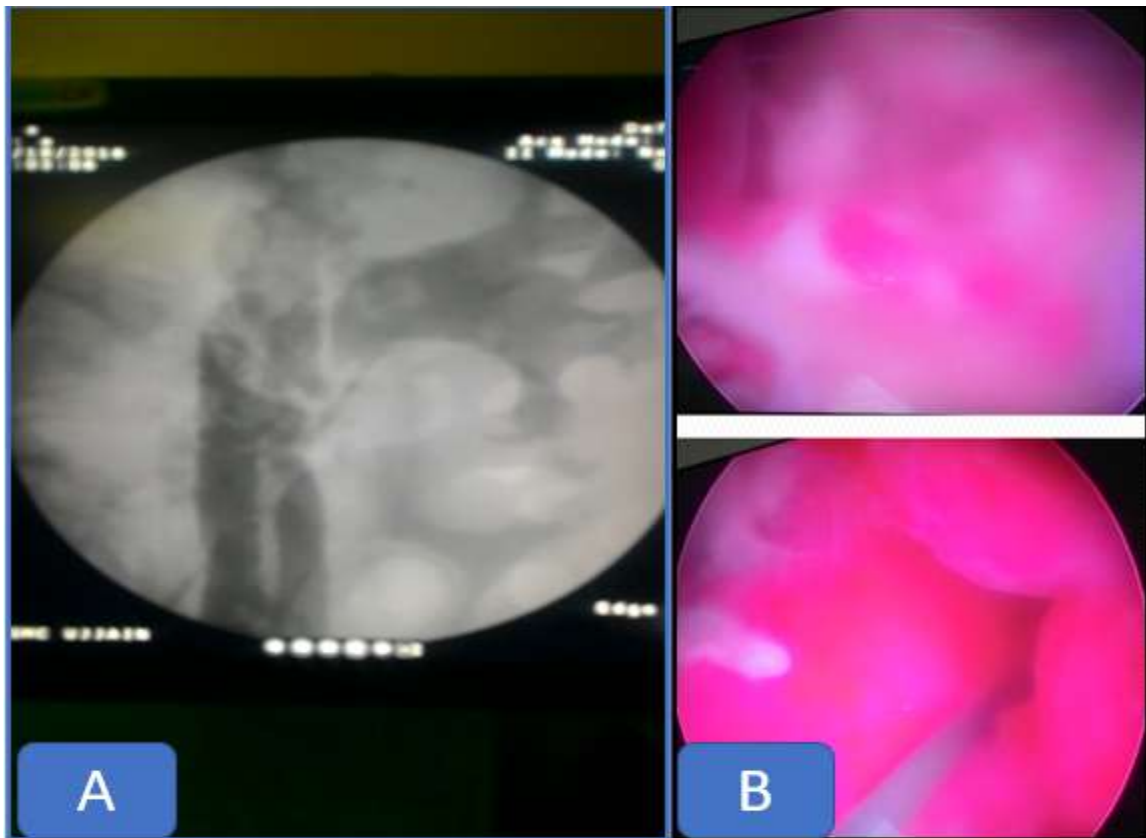


Figure 1:- A- fluoroscopy showed ruptured kidney hence dye was extravasated on medial aspect of Left kidney. B- In Nephroscopy – ruptured medial wall (communicated with perinephric space) of left kidney (old) dilated calyces filled with pus rest of kidney tissue normal.

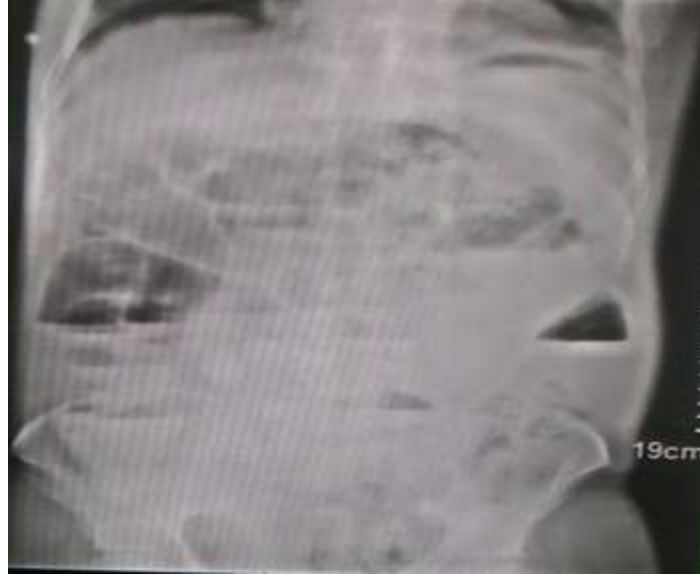

Figure 2:- X-Ray Erect abdomen showed multiple air fluid level suggestive of obstruction.

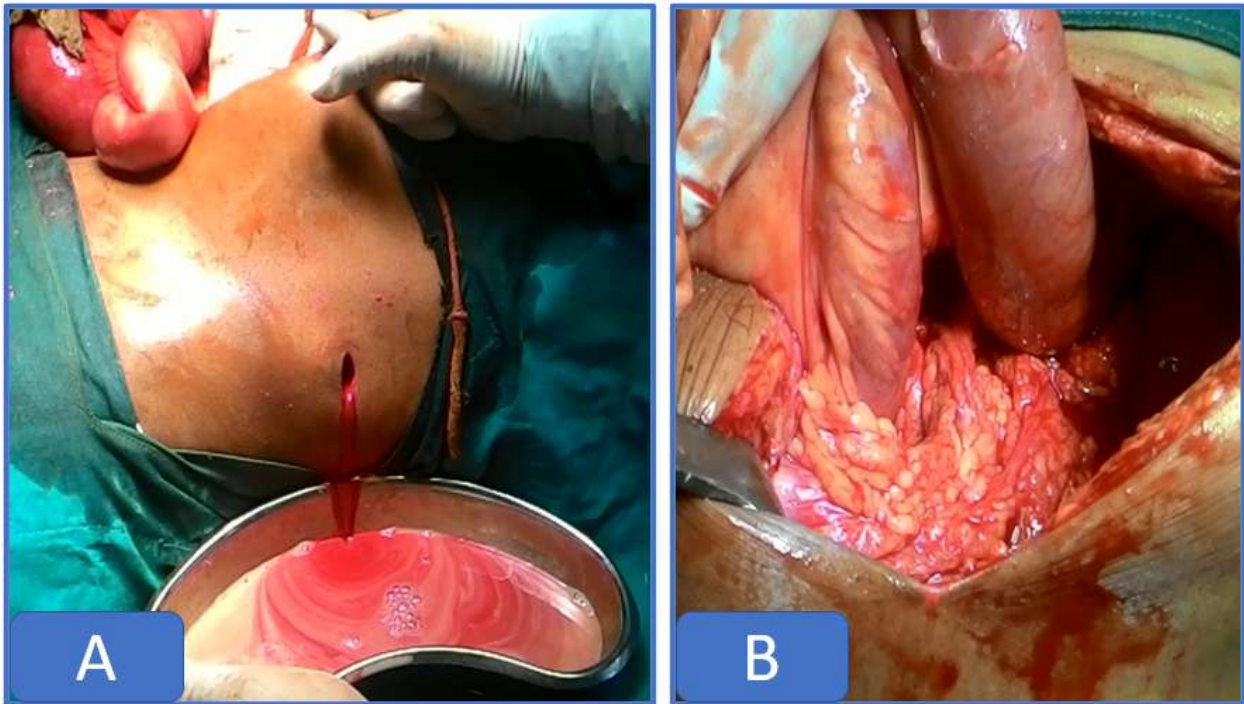


Figure 3:- A- Frank pus, B-Omentum was attached to wall of retroperitoneal perinephric abscess which was about to burst.

Discussion:-

Perinephric abscess is an uncommon complication of urinary tract infections. The incidence ranges from 1-10 cases for every 10,000 hospital admissions. Men and women are affected with equal frequency. Patients with diabetes account for one third of all perinephric abscess cases.[4] *Escherichia coli*, *Proteus* species, and *Staphylococcus aureus* are the usual etiologic organisms. Predisposing factors for perinephric abscess include neurogenic bladder, vesicoureteral reflux, bladder outlet obstruction, renal papillary necrosis, obstructing calculus, genitourinary tuberculosis, trauma (eg, renal biopsy,[5] urinary instrumentation, urologic surgery), immunosuppression, and intravenous drug abuse. Because of nonspecific findings, in many cases, diagnosing a

perinephric abscess can be difficult. Typically, patients present with a history of urinary tract infections. An infection may be followed in 1-2 weeks by fever and unilateral flank pain. However, this is an uncommon presentation. Typically, the onset of symptoms is insidious, and 58% of patients have symptoms for more than 14 days. The most common symptoms include fever (66-90%), flank or abdominal pain (40-50%), chills (40%), dysuria (40%), weight loss, lethargy, and gastrointestinal symptoms (25%). Pleuritic pain may occur due to diaphragmatic irritation.^[6] Various complications can occur, including the following: Bleeding, Flank abscess, Fistula formation to stomach, small bowel, duodenum, lung, Subphrenic abscess, Empyema, Pneumonia, Atelectasis, Sepsis, Possible rupture into peritoneum, Possible perforation through diaphragm. The mainstay of treatment for perinephric abscess is drainage. (incised and drained through a retroperitoneal approach) Antibiotics are mainly used as an adjunct to percutaneous drainage because they help to control sepsis and to prevent the spread of infection.^[7] Surgical intervention may be indicated in cases when a perinephric abscess is not successfully treated with antibiotic therapy and percutaneous catheter drainage. Empiric therapy can be delayed for percutaneous drainage in a stable patient if drainage can be done immediately to identify the causative organism. Surgical drainage of the abscess and/or nephrectomy is warranted in a patient that failed medical treatment. Nephrectomy is also warranted in patients with a chronically infected and atrophic kidney that develop a perinephric abscess.

Conclusion:-

Even uncomplicated urinary tract infection can land up into life-threatening complication such as perinephric abscess, acute obstruction so we kept in mind about this complication. Early diagnosis, immediate drainage, antibiotic therapy with surgical management can reduce the mortality.

References:-

1. Perinephric Abscess. <https://emedicine.medscape.com/article/439831-overview>
2. Okafor CN, Onyeaso EE. Perinephric Abscess. [Updated 2019 Jun 26]. In: StatPearls [Internet]. Treasure Island (FL): StatPearls Publishing; 2019 Jan-. Available from: <https://www.ncbi.nlm.nih.gov/books/NBK536936>
3. Saiki J, Vaziri ND, Barton C. Perinephric and intranephric abscesses: a review of the literature. *West. J. Med.* 1982 Feb;136(2):95-102.
4. Jacobson D, Gilleland J, Cameron B, Rosenbloom E. Perinephric abscesses in the pediatric population: case presentation and review of the literature. *Pediatr Nephrol.* 2014 May. 29 (5):919-25. [Medline].
5. Wickre CG, Major JL, Wolfson M. Perinephric abscess: an unusual late infectious complication of renal biopsy. *Ann Clin Lab Sci.* 1982 Nov-Dec. 12(6):453-4. [Medline]. Edelstein HE, McCabe RE, Lieberman E. Perinephric abscess in renal transplant recipients: report of seven cases and review. *Rev Infect Dis.* 1989 Jul-Aug. 11(4):569-77. [Medline].
6. Cheng CH, Kuo HC, Su B. Endometriosis in a kidney with focal xanthogranulomatous pyelonephritis and a perinephric abscess. *BMC Res Notes.* 2015 Oct 21. 8:591. [Medline].
7. 4-El-Nahas AR, Faisal R, Mohsen T, Al-Marhoon MS, Abol-Enein H. What is the best drainage method for a perinephric abscess?. *Int Braz J Urol.* 2010 Jan-Feb. 36(1):29-37. [Medline].