



Journal Homepage: -[www.journalijar.com](http://www.journalijar.com)

## INTERNATIONAL JOURNAL OF ADVANCED RESEARCH (IJAR)

Article DOI:10.21474/IJAR01/11298  
DOI URL: <http://dx.doi.org/10.21474/IJAR01/11298>



### RESEARCH ARTICLE

#### FATAL INTRACEREBRAL HAEMORRHAGE WITH ACUTE RENAL FAILURE WITHOUT ANY LOCAL MANIFESTATION : A RARE SEQUELAE FOLLOWING SNAKE BITE

Dr. Abhijeet Singh Sachan, Dr. Prakrati Sachan, Dr. Surjeet Singh and Dr. Sateesh Chandra Verma

#### Manuscript Info

##### Manuscript History

Received: 10 May 2020  
Final Accepted: 15 June 2020  
Published: July 2020

##### Key words:-

Snake Bite, Intracranial Haemorrhage,  
Haemotoxin, Coagulopathy

#### Abstract

Snake bite is common entity in tropical countries. India has maximum no of snake bite related deaths. The deaths are commonly due to haemotoxic and neurotoxic properties of snake venom. Intracranial findings occur with activation of coagulation pathway by procoagulant toxins. The snake venom has some toxins and enzymes namely proteases, prothrombinase, metalloproteinases, collagenase, haemorrhagins. Cerebral haemorrhage include intraparenchymal, intraventricular, subarachnoid bleed. Acute tubular necrosis is the most common renal manifestation. These patients are usually treated with polyvalent antsnake venom. They have poor prognosis once cerebral manifestations occur.

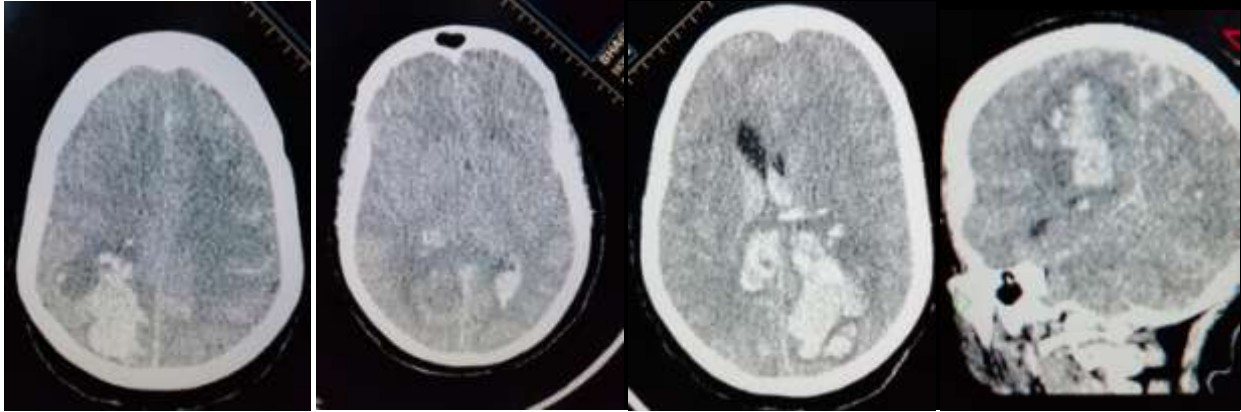
Copy Right, IJAR, 2020. All rights reserved.

#### Introduction:-

Snake bite is a common cause of death in certain parts of the world. India leads the world with maximum number of snakebites and related mortality globally.<sup>1</sup> Approximately 4-18 million people have snakebite worldwide and 20,000-94,000 people die every year.<sup>2</sup> In India annually approximately 2,500,000 snakebites are reported with 30,000-50,000 deaths per year.<sup>3</sup> Deaths can be attributed to their haematotoxic and neurotoxic properties. Elapids (Cobra, Mamba, and Coral snakes and Kraits) are neurotoxic whereas Vipers (Russell's viper, pit viper, rattle snake), Tiger snake, Twig snake are haemotoxic. Clinical presentation of neurotoxicity include hypotension, shock, multiorgan failure while haemotoxicity manifest in the form of local tissue swelling, necrosis, bleeding and coagulopathy.<sup>4-6</sup> Cerebral complication include both haemorrhagic and non-haemorrhagic manifestations. Cerebral haemorrhage include intraparenchymal, intraventricular, subarachnoid bleed. The mechanism is believed to cause toxin induced coagulopathy. This case had all the cranial manifestation without any local symptom.

#### Case Report:

A 60 year old nondiabetic and non-hypertensive female patient presented with history of snakebite 4 days back. She ignored this incident and fell unconscious 3 days after the incident, with no preceding vomiting and headache. She was brought to our centre with GCS of 7/15, and laboured breathing. Her pupils were equal and sluggishly reactive to light. Her blood pressure was 114/72 mmHg, pulse rate was 96/min and respiratory rate was 20/min. There was a snakebite mark seen on Right toe. There was no signs of head injury, any external bleeding, local ecchymosis, local tissue necrosis, DVT. She was immediately intubated and NCCT Head was done which showed a large intraparenchymal haemorrhage in right occipital with intraventricular extension and subarachnoid haemorrhage (Figure 1). With persistent clinical deterioration she was put on ventilatory support. Gradually she developed haematuria and acute renal failure.



**Figure 1:-** ( NCCT brain with large intraparenchymal haemorrhage in right occipital with intraventricular extension and subarachnoid haemorrhage).

Her laboratory investigation showed haemoglobin of 8.9 gm/dl ,Total leukocyte count of 12790/cumm ,decreased platelet count of 83,000 /ml , deranged coagulation profile with prothrombin time of 26.3 sec , INR of 2.38 , PTTK of 30.5 sec , Bleeding Time of 8 min 22 sec , Clotting Time of 7 min 13 sec ,FDP and D-Dimer were positive , and serum creatinine of 1.03 mg/dl and random blood glucose of 221 mg/dl . Her investigations were monitored closely (Table 1) .Her USG abdomen was done which showed maintained corticomedullary junction in bilateral kidney .

**Table 1:-**

	Hb (gm/dl)	TLC (x 1000/cumm)	PLT (/ml)	PT (sec)	INR	PTTK (sec)	S. Urea (mg/dl)	S. Creat. (mg/dl)	RBS (mg/dl)
Day 0	8.9	12.79	83,000	26.3	2.38	30.5	29	1.03	221
Day 1	5.7	13.05	75,000	33.4	3.25	36.5	21.83	0.54	141
Day 2	10.8	16.84	1,04,000	23.0	2.02	33.4	69	1.88	313
Day 3	8.6	18.65	74,000	35.7	3.34	31.4	108	2.24	247

Treatment : She was initially managed with antsnake venom therapy with 10 vials – 100 ml in 500 ml of .9% saline over 2 hours . After that fresh frozen plasma and platelet concentrates were administered to correct coagulation profile . She was managed conservatively with supportive treatment with broad spectrum antibiotics ,antiepileptic ( phenytoin ) , mannitol and ventilator support .With gradual deterioration of neurological status , vasopressor therapy was started . The patient did not show any improvement and finally succumbed to death after 4 days .

### Discussion:-

Snake bite is a common cause of mortality and morbidity in the world with common incidence in Africa , South America and South East Asia . In India Maharashtra has the maximum incidence ( 70 per lakh population ) . Mosquera et al reported a 2.6% incidence of cerebrovascular complication among 309 patients with 7 cases of cerebral haemorrhage .<sup>7</sup> Common Kraits and vipers are responsible for most of the snakebites in india .

Clinically they present with symptoms of neurotoxicity ,haemorrhagic manifestations ,systemic vasculotoxicity , local complications and renal failure .Cerebral involvement after snake bite is rare and includes both infarcts and haemorrhages . Cerebral haemorrhages following snakebite occur mostly due to two phenomenons i) venom induced coagulopathy ii) Haemorrhage induced direct endothelial damage .<sup>8</sup> The snake venom has some toxins and enzymes namely proteases , prothrombinase, metalloproteinases ,collagenase ,haemorrhagins ,thrombin like enzymes , polypeptide toxin ( cardiotoxin,bradykinin and histamine ) and toxic acidic proteins .These products interfere with normal clotting mechanism by producing anticoagulant and coagulant impacts .The viper venom also contain various anticoagulant proteins and activate factors V ,IX,X, XIII causing fibrinolysis and haemorrhage .<sup>9</sup>

VICC (Venom induced consumption coagulopathy) occurs as result of activation of coagulation pathway by procoagulant toxins .It is characterized by prolonged 20WBCT ,PT,PTTK and fibrin degradation products .<sup>10</sup> On

the other hand Metalloproteins (ecarin and carinactivase ) are prothrombin activators which reduce the level of fibrinogen , factor V, and factor VII resulting in cerebral haemorrhage .<sup>11,12,13</sup> Proteases activate fibrinolysis and cause destruction of blood vessels and results in Cerebral haemorrhages .<sup>14</sup> Haemorrhagin toxin can lead to both VICC and direct endothelial damage and can result in cerebral haemorrhages including subarachnoid haemorrhage<sup>10</sup>

**Table 2:-** Cerebral hemorrhages linked to the bite of venomous snakes.

Snake	Toxins	Effect on brain
Bothrops species	Asperctin, hemorrhagins, metalloproteinases	Subarachnoid and parenchymal brain hemorrhages
Daboia russelli (Russell viper)	Proteases	Pituitary hemorrhages
Pseudonaja textilis (Brown snake)	Prothrombinase	Parenchymal brain hemorrhages
Notechis scutatus (Tiger snake)	Toxic acidic proteins	Parenchymal brain hemorrhages

Acute renal failure is a common complication .Its prevalence ranges from 2-10% .<sup>15</sup> The most common finding is acute tubular necrosis but renal cortical necrosis can be seen .<sup>16</sup>The probable mechanism is suggested to be fibrin microthrombi deposition at the glomerular capillary tuft , myoglobinuria and direct injury due to toxins .<sup>17,18</sup>

The mainstay of treatment of snake bite is Anti Snake Venom .The vaccine is polyvalent and effective against all the four common species ; Russells viper , common cobra ,common krait and saw scaled viper . Approx 1 mL of antisnake venom neutralizes 0.60 mg of cobra venom, 0.45 mg of krait venom, 0.6 mg of Russell viper venom, and 0.45 mg of saw-scaled viper venom .Begin with 10 vials of ASV in 100 ml of saline for 2 hours . The dose needs to be repeated after 6 hours , if 20 WBCT is derranged .

Adding to this there should be symptomatic treatment .<sup>19,20</sup>

Poor prognostic indicators are low platelet <20,000/mm<sup>3</sup> , polymorphonuclear leucocytosis with presence of band form , crenated RBC ,Haemo concentration at presentation –indirectly denotes capillary leak , raised D-Dimer , low fibrinogen , low serum protein and albumin ,haemoglobinuria ,bilateral parotid swelling , cerebral anoxia , profound thirst .<sup>19</sup>

### Conclusion:-

Intracerebral event after snake bite is a rare complication involving infarct and haemorrhage .It is associated with poor prognosis and should be managed promptly with Antisnake venom and correction of coagulation profile with Fresh frozen plasma for better outcome .Intracerebral haemorrhagic complications often result in increased intracranial pressure and brainstem herniation . A comprehensive measure should be taken for to improve the outcome after snake bite .

### References:-

1. Kasturiratne A, Wickermasinghe AR , de Silva N, Gunawardene NK, Pathmeswaran A, Premaratna R ,et al .The global burden of snakebite : a literature analysis and modeling based on regional estimates of envenoming and deaths .PLoS medicine .2008;5(11):e218
2. World Health Organization . Prevalence of snakebite envenoming .:WHO ; 31 January 2018
3. David AW , Guidelines for the Clinical Management of Snake-Bites in South- East Asia Region .New Delhi , India: World Health Organization ;2005 :1-67
4. Udaya K . Ranawaka , David G. Laloo , H. Janaka de Silva . Neurotoxicity in Snakebite – The Limits of Our Knowledge . PLoS Negl Trop .2013 Oct ;7(10):e2302
5. Julien Slagboom , Jeroen Kool ,Robert A. Harrison , Nicholas R. Casewell .Haemotoxic snake venoms : their functional activity , impact on snakebite victims and pharmaceutical promise .Br J Haematology.2017 Jun;177(6): 947-959.
6. Priyanka K. Goswami, Mayuri Samant ,Rashmi S. Srivastava . Snake Venom , Anti-Snake Venom and potential of Snake Venom. Int J Pharmacy and Pharmaceutical Sciences: 2014 ;6(5);4-7.

7. Mosquera A, Idrovo LA, Tafur A, Del Brutto OH. Stroke following Bothrops spp. snakebite. *Neurology* 2003;60(10):1577–1580.
8. Yap CH, Ihle BU. Coagulopathy after snake envenomation. *Neurology* 2003;61(12):1788
9. Warrell DA. Snake bite and snake venoms . *Q J Med* 1993 jun ;86(6): 351-353
10. Isbister GK . Snakebite doesn't cause disseminated intravascular coagulation : coagulopathy and thrombotic microangiopathy in snake envenoming . *Semin Thromb Hemost* 2010; 36(4):444-451
11. Cortelazzo A , Guerranti R , Bini L ,et al . Effects of snake venom proteases on human fibrinogen chains . *Blood Transfus* 2010;8s120-s125
12. Maruyama M , Kamiguti AS , Cardoso JL , Sano-Martins IS ,Chudzinski AM , Santoro ML , Morena P , Tomy SC , Antonio LC , Mihara H et al: Studies on blood coagulation and fibrinolysis in patients bitten by Bothrops jararaca *Thromb Haemost* 3: 449-453,1990
13. Boyer LV , Seifert SA , Clark RF ,et al .Recurrent and persistent coagulopathy following pit viper envenomation . *Arch intern Med* 1999;159(7) 706 -710 .
14. Kamiguti AS, Cardoso JL ,Sano-Martins IS,Chudzinski AM ,Santoro ML , Morena P, Tomy SC , Antonio LC , Mihara H et al : Studies on blood coagulation and fibrinolysis in patients bitten by Bothrops jararaca. *Thromb Haemost* 63: 449-453, 1990.
15. Nishioka AS , Silveira PVP : A Clinical and epidemiological study of 292 cases of lance headed viper bite in a Brazilian teaching hospital . *Am J Trop Med Hyg* 47:805-810,1992
16. Burdmann EA , Woronik V , Prada EBA ,Abdulkader RC , Saldanha LB , Barreto OCO ,Marcondes M : Snakebite –induced protection acute renal failure : an experimental model. *Am J Trop Med Hyg* 4: 82-88 ,1993.
17. CastroI I ,Burdmann EA , Yu L ,:Bothrops antivenom prevented snake venom tubular toxicity but not the venom -induced protection against hypoxia –reoxygenation injury . *J Am Soc Nephrol* 10:644A -645A ,1999.
18. Boer –Lima PA, Gontijo JA ,da Cruz –Hofling MA: Histologic and functional renal alterations caused by Bothrops moojeni snake venom in rats . *Am J Trop Med Hyg* 61: 698-706,1999 .
19. Joseph K Joseph ; *Viperidae envenomation in India –Handbook of Toxinology* , Springer 2014 .
20. Joseph J K , Simpson ID et al , First Authenticated cases of life threatening envenoming by humpnosed pit viper in India –*Trans R .Soc Trop Med Hyg* 2007; 101: 85-90 .