



RESEARCH ARTICLE

CHRONIC SDH IN BOXER/WRESTLER ASSOCIATED WITH TEMPORAL ARACHNOID CYST

Kunj Bihari Saraswat¹, Dr. Tushar Marbate² and Ashok Gupta³

1. Associate Consultant Neurosurgery, Max Super Speciality Hospital Dehradun, India.
2. Resident Neurosurgery, Sawai Maan Singh Medical College Jaipur, India.
3. Senior Professor, Neurosurgery, Sawai Maan Singh Medical college Jaipur, India.

Manuscript Info

Manuscript History

Received: 18 March 2020

Final Accepted: 20 April 2020

Published: May 2020

Key words:-

Amateur Boxer/Wrestler, Chronic SDH, Arachnoid Cyst

Abstract

Boxing and wrestling (combat sports) are dangerous sports in which players have risk of brain damage and death. Amateur boxing has low risk of cerebral damage than professional boxing. Although trauma is a most common cause of chronic SDH but other predisposing factor may coexist. Arachnoid cyst is rare cause of chronic SDH may complicate in to chronic SDH in young spontaneously or with minor trauma. Here we report a case of rare combination of young Amateur Boxer/wrestler presented with Chronic SDH associated with Arachnoid cyst in Left temporal region, underwent burr hole and irrigation after thorough evaluation. Chronic SDH in Boxers and wrestlers may result due to multiple co-existing factor and need thorough evaluation and further involvement in sport should withhold.

Copy Right, IJAR, 2020,. All rights reserved.

Introduction:-

Wrestling is a violent sport in which players have the risk of cerebral damage or death. The most common life-threatening injury is SDH, and the most feared complication of chronic insult to the nervous system is dementia pugilistica [4]. Trauma is a most common cause of Chronic SDH. [8]. Other factor beside trauma may be present.[1][2],[12],[9],[14]. Amateur boxing has low risk of cerebral damage than professional boxing. [7]. Arachnoid cysts are rare less than 1% of intracranial space occupying lesion may cause spontaneous chronic SDH in young patient. [13]. Amateur young boxers present with Chronic SDH should be judiciously managed and evaluated for other co-existing cause as in this rare case report of a boxer having Trauma and arachnoid cyst as co-existing factor of chronic SDH.

Case:

A 27 year male patient who was amateur boxer presented with headache since around 1 month without any obvious history of trauma to head. On examination patient was conscious and GCS E4V5M6. CT head and MRI Brain done showing Left fronto-parietal chronic SDH (Figure 1) and left temporal tip Arachnoid cyst (Figure 2). MR angiography was normal. All coagulation profile was normal. Burr hole and irrigation surgery performed with xanthochromic fluid present. Patient improve Post operatively become symptom free. On post operative CT head there was no residual Chronic SDH and Left Temporal tip Arachnoid cyst of same size (Figure 3). Patient restricted from sport and kept in follow up.

Corresponding Author:- Kunj Bihari Saraswat

Address:- Associate Consultant Neurosurgery, Max Super Speciality Hospital Dehradun, India.

Discussion:-

most common sport related intracranial bleed is SDH. SDH is most common cause of sport related death in athlete.[4],[5]. Sub dural haematoma in boxers are different from those commonly seen in the elderly and from SDH in many young due to trauma. There is no large potential subdural space like elderly patient have, and thus a mass effect and increase in intracranial pressure occur rapidly. There is often significant associated contusion or edema also present due to multiple blows. Thus SDH is a commonest cause of death in boxers. [16]. mechanism of injury according to Mawdsley and Ferguson- at the time of the impact of the fist on the skull, there is acceleration of the head. Because of the inertia of the brain brain moves slower than skull. When skull comes to rest, the brain continues to move. As a result, the brain impacts on bony ridges of the skull surface and edge of the dural attachment. Contusions and intra-parenchymal haemorrhages may occur by this mechanism. Stretching forces on the bridging veins that cross the subdural space result in the development of subdural haematoma, which is responsible for most deaths from boxing.[10]. Decrease in consciousness results from damage to the reticular activating system from impact to brain.[6].

Other factor have previously been reported to predispose to Chronic SDH are Coagulopathy, arterio-venous malformation and aneurysm, intracranial hypotension.[2],[9],[11],[15]. Besides, arachnoid cyst, especially located at the middle fossa has long been regarded as a promotive factor.[1],[12],[14],[3].

The speculated mechanism may be that tearing of the outer wall of an arachnoid cyst causes subdural and/or inartistic haemorrhage by breaking the bridging veins, unsupported blood vessels around the cyst wall and leptomeningeal vessels in the base of the cyst. [3]. As in our case, preferring boxing/wrestling, though without obvious head injury history, might have led to tearing of the wall of the arachnoid cyst and its blood vessels. Cerebral spinal fluid (CSF) and blood leaking into the subdural space induced the formation of the outer membrane under the dura mater. The fenestrated neovessels and alterations induced by the subdural degradation products give rise to the collection of subdural haematoma. In case presented patient was a Amateur boxer having Chronic SDH that associated with arachnoid cyst which is a rare combination of Boxer and Arachnoid cyst. The purpose of this report is that one should consider even rare cause of chronic SDH while dealing with Boxer/wrestler with chronic SDH and risk of further participation in to sport should be discussed with patient and family.

Conclusion:-

Chronic SDH in Amateur boxers most commonly caused by Trauma but other Factor should also be thoroughly investigated and should be treated accordingly. Risk of Further involvement in boxing sport should be explained.

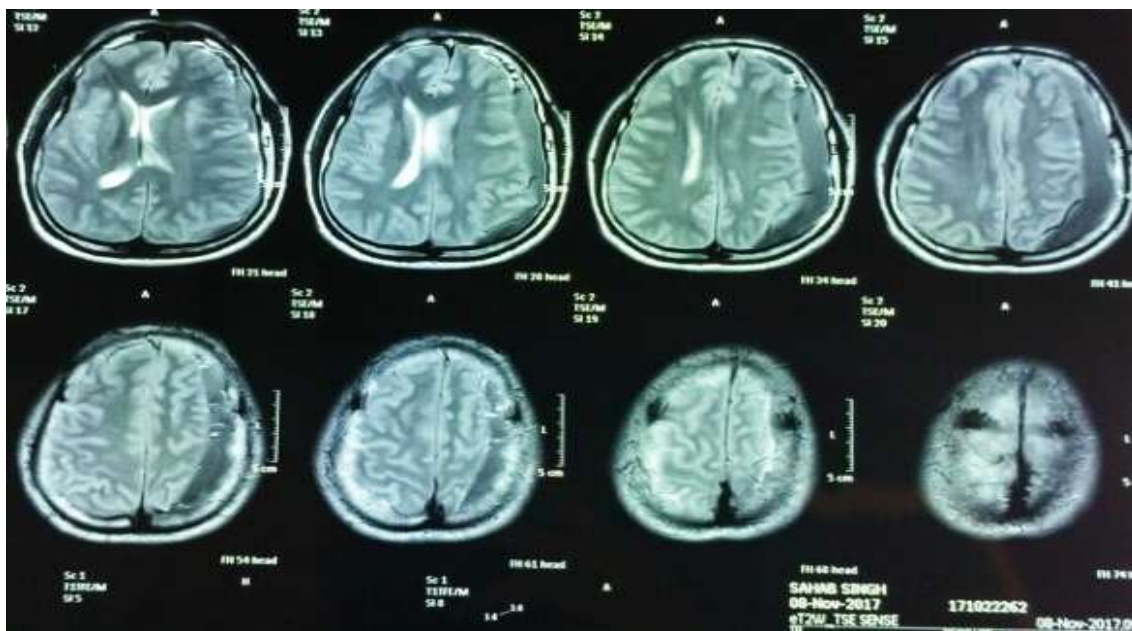

Fig 1:- MRI Axial Section T2WI: Left side Chronic Sub Dural Haematoma with mass effect and midline shift to right.

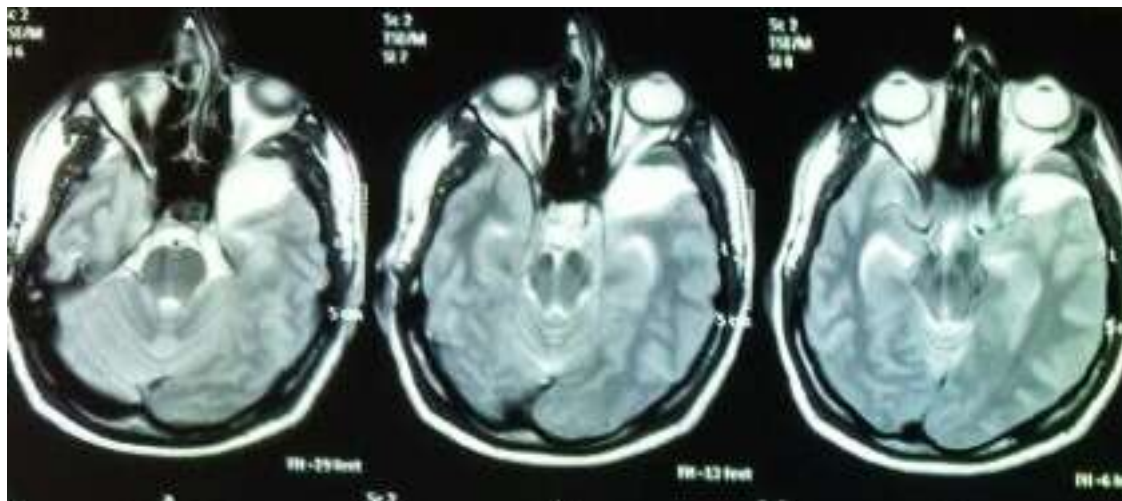


Fig 2:- MRI Axial Section T2WI: Left Temporal Arachnoid Cyst in same patient.

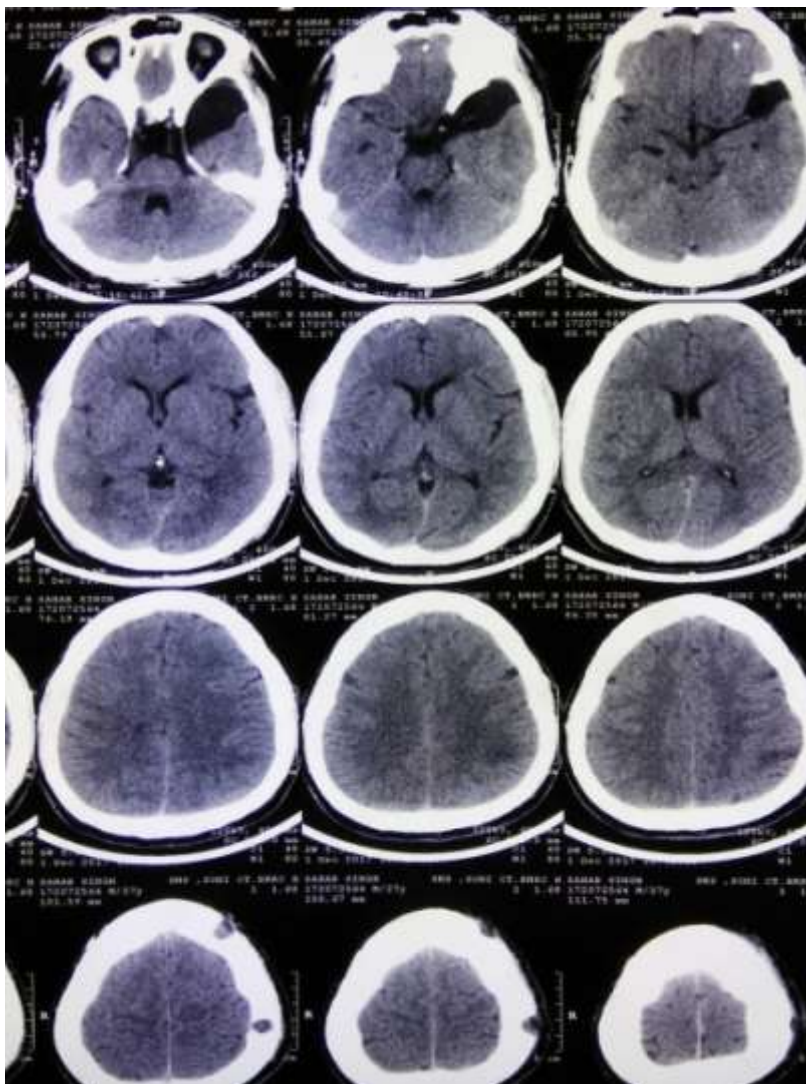


Fig 3:- Post Operative CT head of same Patient showing complete resolution of Chronic SDH with Left Temporal Arachnoid Cyst.

References:-

1. Albuquerque FC, Giannotta SL (1997): Arachnoid cyst rupture producing subdural hygroma and intracranial hypertension : case reports. *Neurosurgery* 41 : 951-955; discussion 955-956,
2. Albanese A, Tuttolomondo A, Anile C, Sabatino G, Pompucci A, Pinto A, et al. (2005): Spontaneous chronic subdural hematomas in young adults with a deficiency in coagulation factor XIII. Report of three cases. *J Neurosurg* 102 : 1130-1132,
3. Aoki N, Sakai T . (1990): Intraoperative subdural hematoma in a patient with arachnoid cyst in the middle cranial fossa. *Childs Nerv Syst* 6 : 44-46,
4. Bailes JE, Cantu RC (2001): Head injury in athletes. *Neurosurgery* 48:26-46. .
5. 10-5. Cantu RC, Mueller FO (2003): Brain injury-related fatalities in American football, 1945-1999. *Neurosurgery* 52:846-853.
6. Govons S. (1968) Brain concussion and portuse: the knockdown blow of the boxing ring. *Confin Neurol* ;30:77-84.
7. Jordan B and Campbell E. (1988) Acute injuries among professional boxers in New York State: two year survey. *Physician and Sports Medicine* 1988;16:87-91.
8. Kotwica Z and Brzezinski J. (1991) Chronic subdural haematoma treated by burr holes and closed system drainage: personal experience in 131. *Br J Neurosurg*;5:461e465.
9. Kotwica Z and Polis L (1986) : The association of arteriovenous malformation, aneurysm and chronic subdural hematoma. Case report. *Zentralbl Neurochir* 47 : 158-160.
10. Mawdsley C and Ferguson FR. (1963) Neurological disease in boxers. *Lancet*;19:799-801.
11. Missori P, Maraglino C, Tarantino R, Salvati M, Calderaro G, Santoro A, et al.(2000) : Chronic subdural haematomas in patients aged under 50. *Clin Neurol Neurosurg* 102 : 199-202.
12. Oka Y, Kumon Y, Ohta S, Sakaki S, Ohue S, Takeda S(1994) : Chronic subdural hematoma associated with middle fossa arachnoid cysts--three case reports. *Neurol Med Chir (Tokyo)* 34 : 95-99.
13. Robinson RG. (1971) Congenital cysts of the brain: Arachnoid malformations. *Progr Neurosurg* ; 4:133-74
14. Servadei F, Vergoni G, Frattarelli M, Pasini A, Arista A, Fagioli L (1993): Arachnoid cyst of middle cranial fossa and ipsilateral subdural haematoma : diagnostic and therapeutic implications in three cases. *Br J Neurosurg* 7 : 249-253.
15. Takahashi T, Senbokuya N, Horikoshi T, Sato E, Nukui H, Kinouchi H (2007): [Refractory chronic subdural hematoma due to spontaneous intracranial hypotension]. *No Shinkei Geka* 35 : 799-806.
16. Unterharnscheidt F (1970): About boxing: review of historical and medical aspects. *Tex Rep Biol Med* 28:421-495.