



Journal Homepage: - www.journalijar.com

INTERNATIONAL JOURNAL OF ADVANCED RESEARCH (IJAR)

Article DOI: 10.21474/IJAR01/10981

DOI URL: <http://dx.doi.org/10.21474/IJAR01/10981>



RESEARCH ARTICLE

DENTAL IMPLANTS: A REMEDY OR HINDRANCE

Dr. Navneet Kour¹, Dr. Kousain Sehar¹, Dr. Nadia Irshad², Dr. Sarish Latief³, Dr. Adeel Ahmed Bajjad⁴, Dr. Manju Tagra⁵ and Dr. Burhan Atlatf Misgar⁶

1. MDS Dept of Periodontology and Implantology, BRS Dental College and Hospital Sultanpur Panchkula.
2. MDS Dept of Paedodontics and Preventive Dentistry, BRS Dental College and Hospital Sultanpur Panchkula.
3. MDS Dept of Oral and Maxillofacial Surgery, BRS Dental College and Hospital Sultanpur Panchkula.
4. MDS Dept of Orthodontics, Kothiwal Dental College and Research Center, Moradabad Uttar Pradesh.
5. MDS Dept of Paedodontics and Preventive Dentistry, BRS Dental College and Hospital Sultanpur Panchkula.
6. MDS Dept of Paedodontics and Preventive Dentistry Guru Nanak Dev Dental College and Research Institute, Sunam.

Manuscript Info

Manuscript History

Received: 14 March 2020

Final Accepted: 16 April 2020

Published: May 2020

Key words:-

Classification, Implant Failure,
Osseointegration, Periimplantitis,
Prosthesis

Abstract

Implant-supported restoration offers a higher and predictable treatment for tooth replacement with greater amounts of success rates. Nevertheless, failures that mandate instant implant removal do occur. The reverberations of implant removal threaten the clinician's efforts to accomplish satisfactory function and esthetics. For the patient, this usually involves further cost and extra procedures. Despite the advances in dental implants materials, design and techniques, the failure of implant may be a nightmare for both dentists and patients. The failure of dental implants increased over the time. When an implant fails, a tailor made treatment plan should be provided to every patient consistent with all relevant variables. Patients should be told regarding all possible treatment modalities following implant failure and provides their consent to the foremost appropriate treatment option for them. The aim of this paper is to explain different methods and treatment modalities to affect implant failure.

Copy Right, IJAR, 2020,. All rights reserved.

Introduction:-

Beginning with rather primitive forms of replacement, artificial teeth have been placed in the oral cavity in the form of removable and fixed partial dentures. Removable partial dentures offer an economic and simple method of tooth replacement yet, the discomfort associated with its repeated insertion and removal has reduced patient acceptance of this modality. Fixed partial denture requires removal of considerable amount of sound tooth structure from the adjacent teeth, which may lead to pulpal problems and hypersensitivity. Failure to restore the function of the natural teeth completely by these means led to search for better alternatives¹.

Implant dentistry is the second oldest discipline in dentistry followed by exodontias. Intense research over the past 50 years has culminated in the introduction of dental implants as an effective and predictable way of replacing lost teeth and currently dental implantology has become one of the major specialties of dentistry in terms of restoring

Corresponding Author:- Dr Nadia Irshad

Address:- MDS Dept of Paedodontics and Preventive Dentistry, BRS Dental College and Hospital Sultanpur Panchkula.

function, esthetic and patient acceptance. Now day's dental implants are the best permanent and secure solution in the replacement of one or more missing teeth giving a natural appearance².

Since the introduction of the concept of osseointegration by Branemark³ in 1977, the success of dental implants has increased dramatically because of better understanding of bone response and the improvement in bone loading concepts. From the time of the studies of osseointegration, millions of patients have been treated worldwide using variations of these techniques using implants with different geometries and surface characteristics. The main and important finding of osseointegration is that when a hole is prepared without overheating or traumatizing the tissue, an inserted biocompatible implantable device would definitely achieve an immediate bone apposition, until micro movement at the interface are prevented during early healing periods.⁴

Still the ultimate success of any implant supported prosthesis is directly related to the clinicians understanding of the biology of the human host and the mechanical aspects of the implant system⁵. Numerous multi centre studies and several meta-analyses have indicated 93% survival rates of dental implants but the incidence of implant loss due to failure to osseointegrate or to loss of integration after loading has also been well-documented in numerous prospective and retrospective reports.⁶

Implant failure is defined as the total failure of the implant to fulfill its purpose (functional, esthetics, or phonetics) because of mechanical and biological reasons. Dental implants may fail for different reasons, with a range that differentiates between complication and failure. Esposito et al stated that this definition includes biological fracture and mechanical failures of the component, and include considering fracture of the implant connecting screws and prosthesis as failures.⁷ To date, the primary factors shown to predispose to implant failure are low density as evidenced in a 5 year Branemark study that showed that fixture failure in maxillary type IV bone is 44%⁴.

Despite rigid adherence to established protocols, certain groups of patients lose a disproportionately high number of endosseous implants. Systemic conditions identified as risk factors for implant failure include: uncontrolled diabetes, postmenopausal women not on hormone replacement therapy, untreated osteoporosis, and high levels of head and neck radiation, smoking and alcoholism. Among parameters that have been examined, smoking is acknowledged as the leading predisposing factor in implant failure, particularly in cases of multiple failures occurring in same level individuals⁶.

Classification Of Implant Failure:

Iatrogenic failure and biologic failure:

1. Ailing implants
2. Failing implants
3. Failed implants
4. Surviving implants

Rosenberg: classified implant failures as:

1. Traumatic failure
2. Infectious failure

Esposito 1998: classified implants according to the Osseointegration Concept:

1. Biological:
 - a. Early: failure to establish osseointegration.
 - b. Late: failure to maintain the achieved osseointegration.
2. Mechanical: fracture of implants, connecting screws, bridge framework, and coating.
3. Iatrogenic: nerve damage, wrong alignment of implant.
4. Inadequate patient education: phonetical, esthetical, pshycological problems.

Truhlar in 1998, classified failures as:

Early failure:

That occurs with in weeks to few months after placement. Caused by factors that can interfere with normal healing processes or by an altered healing response.

Late failures:

Failure that arise from pathologic processes that involve a previously osseointegrated implant.

Kees Heydenrijk: classified failure to occurrence of time:

Early failure:

1. Surgical trauma
2. Insufficient quantity or quality of bone
3. Premature loading of implant
4. Bacterial infection

Late failure:

1. **Soon late failure:** during first year of loading.
2. **Delayed late bone:** implant failure in subsequent years.

According to Cranin:

1. Intraoperative complication
2. Short term complication (first six post operative months)
3. Long term complication

Clinical evaluation to check prognosis of implant:

At the individual level, clinical evaluation is important to optimize maintenance, detect early signs of disease and plan corrective interventions.

The commonly used parameters used for assessing prognosis of implants are given below.

Mobility:

Clinically visible mobile implant after an appropriate healing period leads to failure to achieve osseointegration. Mobility at follow-up is a sign of the final stage of peri implant pathology and indicates complete osseointegration failure implants with less advanced stages of peri-implantitis may still appear immobile due to some remaining osseointegration. To interpret low degrees of mobility the use of an electronic device has been proposed (Perio test, Siemens, Bensheim Germany)⁸.

Peri-implant probing:

Increasing probing depth and loss of clinical attachment are pathognomic of periodontal diseases. Pocket probing is, therefore, a crucial procedure in diagnosis of the peri-implantitis and for evaluation of its therapy.

According to **Bragger et al 1997**⁸, probing the peri-implant soft tissue zone render information regarding the:

1. Level of mucosal margin
2. Peri-implant probing depth
3. Level of the tissue in the peri-implant zone providing resistance to probing.
4. Effects of probing regarding bleeding exudation and suppuration.

Probe penetration at implant sites is heavily dependent upon the conditions of the peri-implant tissue⁹. The probe tip is stopped at or around the level of the most coronal aspect of the connective tissue adhesion of the implant neck at healthy sites. At inflamed sites the probe consistently reached close to or was in contact with the bone level. The optimal force for probing at teeth has been suggested to be 0.25 N¹⁰.

Clinical indices:

Swelling, redness of the marginal tissues and bleeding upon gentle probing have been reported as typical signs of peri-implant infections¹⁰. Parameters developed for teeth may not be strictly applicable to the features of the peri-implant tissues. Thus, indices used are:

Modified Sulcus Bleeding Index (Mombelli 1997):

Score 0 No bleeding when a periodontal probe is passed along the gingival margin adjacent to the implant.

Score 1 Isolated bleeding spots visible.

Score 2 Blood forms a confluent red line on margin.

Score 3 Heavy or profuse bleeding.

Modified Plaque Index (Mombelli 1987):

Score 0 No detection of plaque.

Score 1 Plaque only recognized by running a probe across the smooth marginal surface of the implant. Implants covered by plasma spray in this area always score 1.

Score 2 Plaque can be seen by the naked eye.

Score 3 Abundance of soft matter

Lindquist et al (1988)¹¹ oral hygiene assesement was made according to a 3-point scale (0: no visible plaque; 1: local plaque accumulation; 2: general plaque accumulation >25%) and found a significant relationship between the two over a 6- year period.

Keratinized mucosa:

Whether or not keratinized mucosa is required for the future maintenance of peri-implant tissue health are remains under debate. Nevertheless, clinical studies in humans revealed that the absence of marginal keratinized tissue is comparable with soft tissue health provided adequate levels of plaque control are maintained.

Assessment of implant stability during loading:

It has been suggested that osseointegration of screw-shaped titanium implants are tested clinically by the application of a counterclockwise torque ranging to 20 Ncm (reverse torque test) at second-stage surgery ^[12]. While osseointegrated implants will resist a reverse torque at this level, osseointegration failure with fibrous encapsulation will lead to an unscrewing.

Bone density:

bone density is a key determinant clinical success. Highest clinical failure rates have been reported in the posterior maxilla^[1].

Based on radiographic examination, Lockhalm and Zarb in 1985 classified the bone on the basis density into 4 types: (Fig:1)

1. type I bone – the bone is very dense and homogenous
2. type II bone – the cortex is very thin and the cancellous bone appears dense
3. type III bone – the cortex bone is fine and the cancellous bone appears sparse
4. type IV bone – the cortex is not visible and the medullar bone appears very sparse

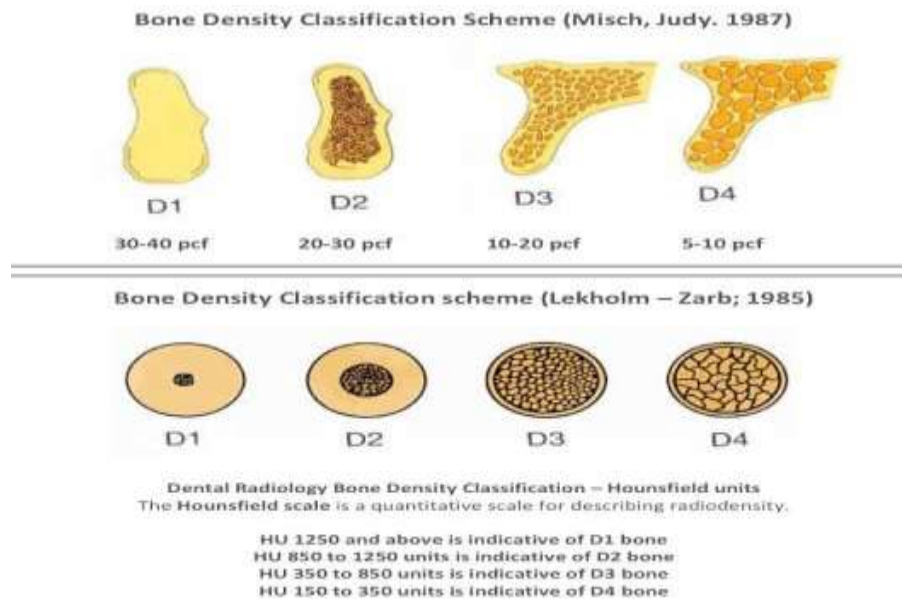


Fig 1:-

In 1988 Misch classified bone density into

1. D 1 – dense cortical bone
2. D 2 – thick dense to porous cortical bone on crest and coarse trabecular bone within
3. D 3 – thin porous cortical bone on crest and fine trabecular within
4. D 4 – fine trabecular bone

Success and failure of implants in relation to systemic condition of patient

Endocrine disorders:

Diabetes mellitus:

Approximately 75% of these patients suffer from periodontal diseases and exhibit increased alveolar bone loss and inflammatory gingival changes. Tissue abrasions are more likely in denture wearers, because the depletion in oxygen tension decreases the rate of epithelial growth and decrease tissue thickness. In diabetes type II patients, the survival rate of implants was significantly lower than in non-diabetic patients (Morris 2000)¹³. Antimicrobial therapy appeared to reduce the implant failure rate.

Hematological diseases:

Erythrocytic disorder:

There are two main categories of erythrocyte disorder:

Polycythemia:

Death usually occurs within 6-10 years due to splenic enlargements, hemorrhages and thrombosis of peripheral veins due to which complicated implants or reconstruction procedures are usually contraindicated.

Anemia:

Complications in the implant patient having anemia may affect both short-term and long term prognosis. The decrease in bone density affects the initial placement and influence the initial amount of mature lamellar bone formed at the interface of an osteointegrated implant. Abnormal bleeding is additionally a standard complication of anemia and through extensive surgery, a decreased vision from the hemorrhages, or difficulty in bone impressions for subperiosteal implants, could be encountered. Increased edema and subsequent increased discomfort postsurgically are common consequences.

Leukocytic disorders:

The most common complication is infection, not only during the initial healing phase, but also several years later. Most oral implants procedures are contraindicated for the patient with acute or chronic leukemia^[15].

Hepatic disorder:

Cirrhosis:

Patients with liver diseases have a prolonged prothrombin time and clinical bleeding. The inability to detoxify drugs may result in over sedation or respiratory depression. Elective implant therapy is relatively contraindicated in the active alcoholic patient with symptoms.

Bone disease:

Diseases of the skeletal system and specifically the jaws are often influence decisions regarding treatment in the field of oral implants.

Osteoporosis:

the most common disease of bone metabolism the implant dentist will encounter is osteoporosis. Changes in the jaws are similar to the osteoporotic changes found in other bones in the body. In a study investigating the effect of estrogen replacement therapy had nearly twice the maxillary implant failure rate (13.6%) compared to other groups (8.1%, 6.3% and 7.6%) respectively, for the postmenopausal women plus estrogen replacement therapy. Poor bone quality may also encourage, for these special indication, the use of more active surfaces than the classical machined commercially pure titanium surface^[17].

Fibrous dysplasia:^[18]

Osteitis Deformans (Paget's diseases):

Oral implants are contraindicated in the regions of this disorder.

Multiple myeloma:**Central nervous system^[16]****Seizures disorder:**

Dental implants and related prosthetics are contraindicated. However, gold or metal occlusal surfaces may be indicated to decrease the risk of fracture of porcelain and additional implants are indicated to improve excess stress distribution and decrease abutment fracture.

Parkinson's disease:

oro-pharyngeal musculature is often affected in this disease, leading to problems with speaking, chewing and swallowing. **Heckmann and coworkers** investigated three patients with Parkinson's disease who were treated with implants in the interforminal regions as retention units for an overdenture ^[19]. Patient comfort as assessed by questionnaire was judged to be greatly improved. Chewing ability and body weight as assessed by the gastrointestinal scale, was found to be improved in all three patients. Diseases affecting motor skills can profit from implant- retained overdentures.

Developmental disorders of skin:

Include a large series of ectodermal anomalies which may be characterized by hypodontia or anodontia and aggressive form of juvenile periodontitis, which often lead to a need for the use of implants. In a case report of patient with Paillon-Lefevre syndrome, successful implantation was reported ^[20].

Effect of smoking:

Smoker's exhibit less favorable healing response following flap debridement surgery shows greater loss of bone height, less favorable reduction in probing depth and clinical attachment gain. Smoking also compromises the function of PMNs and macrophages and microcirculation in several ways. Bain and Moy (1993) carried out a retrospective evaluation of 2,194 consecutive Branemark system implants placed by one surgeon between 1984 and 1991 ^[21]. An overall failure rate of 4.76% in non-smokers as against 11.3% in smokers was found. Implant failure decreased with increased implant length, but in maxilla there was a significantly higher rate in smokers at implant length up to 15mm. De Bruyn and Collaert (1994)²² confirmed these results. They identified 9% failure in the maxilla of smokers as against 1% in the non-smokers. From the clinical perspective it is important to note that at least one failed implant was found to be one in three smokers, while only one in 25 non-smokers had one or more failures.

Effect of radiotherapy:

The publication by Esposito and coworkers (1998)²³ is an evidence based review article using met-analysis. The authors came to the conclusion that irradiation per se is no contraindication to implant installation. Various studies performed by Jacobsson (1985), ²⁴ Albrektsson (1988), ²⁵ Granstrom et al (1993)²⁶ and many more concluded, that it seems reasonable to assume that full-coverage radiotherapy (50-65 Grays) is no contraindication to implant surgery, but implant surgery in patients irradiated with even higher doses must be performed with the utmost care and the patient must be informed of the possible consequences.

Success And Failure In Relation To Selection Of A Case:

After proper evaluation of systemic condition of the patient, proper dental evaluation is done. Dental evaluation includes both past dental history and thorough dental history.

Past Dental History:

Past dental history includes all previous treatment and evaluation of parafunctional habits.

Parafunction:

Parafunctional forces on teeth or implants have long been recognized as harmful to the stomatognathic system. The most common cause of implant bone loss or lack of rigid fixation during the first year after implant treatment is the result of parafunction. These implant related conditions occur with greater frequency in the maxilla because of decreases in bone density and increase in the moment of force.

Bruxism:

It has been reported that non-satisfied complete denture wearers had significantly higher oral loading levels than satisfied ones and similar results were present also after successful implant treatment of the originally dissatisfied group. (Glantz et al 1985)²⁷.

Crown Implant Ratio:

Lateral forces result in a movement of force on implant and an increase in horizontal stresses implant placed in the anterior placed in the anterior part of maxilla experience more frequent complications because of lateral stresses and the moment of forces. The higher the crown implant ratio, the higher will be the moment of force under lateral loads.

Bone Density:

The amount of implant-bone contact is in direct relationship with the density of the bone. Bone contact percentage is significantly found to be greater in cortical bone than in trabecular bone. The bone density initially found not only provides mechanical immobilization during healing, but also helps to distribute and transmit stresses from the implant-bone interface.

Dental examination should include both extra-oral and intra-oral examination.

Extra-oral examination:

The position of the smile line should be noted at the first visit. A patient who exposes a larger portion of gingiva while smiling is considered as a risk patient from an aesthetic point of view.

Intra Oral Examination:

Jaw opening Horizontal bone thickness Oral hygiene Vertical bone resorption Meso-distal distance Interarch relationship	Presence of lesion Depth of vestibule Vestibular concavity Adjacent implant Height between bone crest and opposing tooth
--	--

Intra-Oral Palpation:

1. Sharpness of the ridge
2. Gingival quality(Bone mapping)
3. Papillae of adjacent teeth

Success and failure in relation to surgical procedure & its management:

Improper surgical procedure may compromise the success of the implant. Each step in surgical placement of implant is important. Complication may occur in any step, thus affecting the prognosis of implant.

Complication that occurs can be divided into

1. Intra-operative complication
2. Short term complication (those that occur during the first 6 months after surgery.)
3. Long term complication

Intraoperative:**Oversized osteotomy:**

The best way to manage problem is to place in large diameter implant that successfully retaps and grasps the internal environment of the osteotomy. If large diameter implant is not available, place some hydroxyapatite graft material against the internal walls of the osteotomy (maximum space of 0.5 mm) and then reinsert the implant.

Perforations of cortical plates:

If perforation has occurred, it is wise to use a membrane or gently tap some synthetic or autogenous bone at the base of the defect and close the soft tissue and re-operate after 6 months.

Fractured cortical plate:

If cortical plate is displaced with periosteum attached to it, replacing it after implant insertion and suturing presents a good prognosis for healing. If fragment is detached, it can be wedged back into position, but the prognosis is

guarded. If the implant diameter prevents replacement, particulate the bone segment with decalcified freeze dried bone and place it external to the surface of defect and place a resorbable membrane over the entire graft complex. If plate fracture is not displaced, it may be left untreated.

Broken burs:

It may be removed by releasing bur from the hand piece & then rotating it counter-clockwise direction with fingers or Howe pliers.

Hemorrhage:

Unusual bleeding may result from soft tissue dissection or perforation of a vessel. Bleeding has to be controlled for adequate visibility at implant site. Bleeding may be controlled by fine hemostatic forcep or firm pressure pack for 5 or more minutes.

Poor angulation or position of an implant:

Due to improper bur hole in the surgical stent or not using surgical stent and thus misdirecting the bur. Rotation of implant to a position that makes the abutment parallel to the adjacent teeth can be achieved in press fit implants with internal threading and without antirotational devices.

Short term complication (first 6 postoperative months):

1. Post-operative Infection:
2. Dysesthesia
3. Dehiscent wounds
4. Dehiscent implants
5. Postsurgical scar contracture

Long term complications

Bone loss around implants begins with gingival inflammation. The causes of bone loss may be unacceptable oral hygiene, nutrition or age related, secondary to systemic disease, bruxism, traumatic occlusion, improperly designed superstructures or physiologically incompetent implant design.

1. Failed implant
2. Failing implant
3. Ailing implant
4. Fractured root form implants
5. Implant of improper angulations
6. Broken prosthetic inserts.
7. Breakage of retention screws

Success And Failure In Relation To Loading Of Implant:

One of the basic requirements for achieving osseointegration is that the implant must remain unloaded during the healing period. Ideally, the prosthesis should not be worn for the first 2-3 weeks, so as not to interfere with the initial bone and soft tissue healing process.

Loading or the restorative problems can be summarized as

Excessive Cantilever:

Many problems can be associated with cantilevers supported by dental implants. Such problems include fracture of the prosthesis, loss of osseointegration and fracture. Cantilevers can be supported by teeth, dental implants, or both. They can be in a distal or mesial orientation opposed by natural teeth, a fixed bridge, or a complete denture. The cantilever can use in a parafunctional or nonparafunctional patient. All of these variants directly affect the success rate of the cantilevers; for example the classic cantilever anterior implants placed in D1 bone explains its own high success rate, contrary cantilevered units supported by implants placed in D4 bone.

Pier Abutments:

Because of the difference in mean axial displacement between natural teeth and implants placing the implant in a pier situation is significant. The breakdown of supporting tissues is extremely rapid because the dental implant will take most of the load as a result of the difference in mean of axial displacement.

No Passive Fit:

A passive fit reduces long term stresses in the superfracture implant components and bone adjacent to the implants. The absence of passive fit may be manifested clinically by pain and discomfort in the short term, and loosening or fracture of implant components in the long term because of excessive strains on the peri-implant bone.

Improper Fit of the Abutment:

Achieving a proper abutment - fixture interface fit is critical. Improper locking between the two parts of the antirotational implant device, leads to an increased microbial population and increased strain on the implant components, with subsequent bone loss and rapid screw-joint failure.

Improper prosthetic design:

Five prosthetic options are available in implant dentistry. Three restorations are fixed and two are removable. Broad knowledge, proper patient selection, better psychological understanding, proper pre-surgical prosthetic planning and a very good biomechanical background are the main components from achieving proper prosthetic design.

Bending Moments:

Bending overload can be defined as a situation in which occlusal forces on an implant-supported prosthesis exert a bending moment on the implant cross section at the crestal bone, leading to marginal bone loss and/or eventual implant fatigue. Connecting Implants to Natural Dentition: Connecting natural teeth to dental implants is controversial and unresolved.

Premature loading:

Too rapid loading of the implant support system is considered to be one of the most common causes of prosthetic related failure. Branemark stated that strict protocol requires a stress free healing period of 3 to 6 months for osseointegration to occur. Misch stated that at 16 weeks, the surrounding bone is only 70% mineralised and still has woven bone as a component. The woven bone has an unorganized structure that cannot withstand full-scale stresses.¹

Excessive Torquing:

Misch recommended at the initial delivery of coping fixation that the screw be tightened to approximately two-thirds to three-fourths of the final torque force and after 4 weeks may be tightened to the full 20 Ncm torque force. More than 20/ cm of torque force could lead to implant failure¹.

Success and failure in relation to maintenance of implants:

Bacterial plaque accumulation and the development of the inflammatory changes in the soft tissue surrounding oral implants have been shown as a cause effect relationship. If this condition is left untreated, it may lead to progressive destruction of the tissue supporting an implant, which may compromise its future and ultimately lead to its failure. Patients who have lost their teeth as a result of a trauma or an accident are usually compliant patients, because they did not expect to lose their teeth. Conversely, patients who have lost their teeth as a result of periodontal disease or neglect are often more challenging³⁰. Since dental implants are highly maintenance intensive, noncompliant patients must be thoroughly educated and retrained before deciding to begin implant therapy. The patient understanding of the maintenance requirements is crucial, and these obligations must be made clear to the patient initially and during subsequent appointments.

Prosthesis Design and maintenance:

The design of the prosthesis should allow for access by the patient and clinician to keep the areas free of plaque. If the patient has a retrievable superstructure, it should be removed every 18-24 months and placed in an ultrasonic cleaning solution³⁰. When scaling around an implant, the scaling pressure applied is important. The tissue cuff around an implant should be tight when healthy, which can create difficulty while scaling. Because of the delicacy of the peri-mucosal seal, the best method for removing calculus is by using short working strokes with light pressure.

Instrument selection:

The maintenance of a smooth surface of the titanium without pits and scratches is important to prevent plaque accumulation. Stainless steel and titanium-tipped instruments are detrimental to a smooth titanium surface³¹. Cavitron and sonic scalers have also been found to gouge titanium³². A plastic sleeve over a sonic scaler appears not

to alter titanium and may be used in cases of heavy calculus accumulation.³³ Air polishing systems will blast many scratches into the titanium and should not be used.

Darby ML (2002)³⁴ gave the following general guidelines for maintenance of implants:

1. Special plastic instruments are used most commonly for assessing and debridement of the implant material.
2. Metal instruments may leave scratches on the surface of the implant.

Scratches or surface roughness on an implant may promote accumulation of plaque.

Surface coating of an implant may be disturbed, thereby reducing the biocompatibility of the implant with the surrounding tissues.

3. Some plastic instruments contain graphite fillers; these types of instruments may be used on the implant superstructure but should not be used directly on the implant abutment.
4. Some plastic instruments may be sterilized by autoclaving.
5. Working end design of plastic instruments.
wrench-shaped, crescent-shaped, and hoe shaped working ends--useful for the debridement of an implant's superstructure.

Working ends that are similar in design to conventional metal probes, sickle scalers, and curettes are useful for the assessment and debridement of an implant abutment.

6. Instrumentation for calculus removal.

Calculus is removed easily from implants because- there is no interlocking or penetration of the deposit within the implant surface.

Light lateral pressure with a plastic scaler or curette is recommended. Numerous amounts of plastic, nonmetallic, nylon coated plastic, graphite, or Teflon-coated instruments are available and are proven as safe to use on titanium implant surfaces.

Polishing: Rubber cup polishing with toothpaste, finely prophylactic paste, commercial implant polishing pastes, and tin oxide have been shown not to alter titanium surfaces (Meschenmoser et al 1996).³¹ In addition to rubber cups, a rubber point or soft unitufted rotary brush may be used.

Sub gingival irrigation: Irrigation of the implant sulcus by chemotherapeutic agents may be useful as long term maintenance procedure.

Toothbrushes: With the vast number of manual and automatic toothbrushes available, patient preference are the key guides, a soft or extra-soft toothbrush will accomplish plaque and debris removal without traumatizing tissue.

Floss: patient instruction for using floss should be aimed at gentle insertion and motion to avoid trauma to tissue. There are also numerous woven flosses with threaders built in to help access and clean larger embrasure space and under connecting bars. (Fig:2)

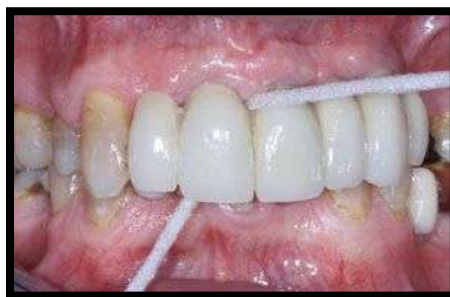

Fig 2:-

Interdental aids:

Many companies manufacture interdental brushes. It is important that the bristles are plastic or coated with nylon to prevent scratching of the titanium components. Patients should also be instructed to inspect and change the brush when signs of wear are evident. Common brush designs include straight and cone-shaped. Embrasure size and shape should be considered to prevent brush bending and tissue trauma.

Oral Irrigation:

Oral irrigation helps remove plaque and debris from around dental implants and their restorations. The flow of irrigation should be aimed to pass contacts never be directed into tissue. Incorrect use could cause trauma to tissue adaptation around the implant and could bacteremia.³⁵

Chemotherapeutic Agents:

Chlorhexidine gluconate has been shown to be a major asset in reducing plaque oral cavity and around dental implants. Long-term use of antimicrobials (e.g. chlorhexidine gluconate) may be used with brushes and floss to avoid accumulation.³⁵

Pocket Watch:

Steri-oss markets a product called Pocket watch, which consists of chemically treated, strips reagent, and testing trays. It assesses the presence & quantity of aspartate aminotransferase (Ast) in gingival crevicular fluid.³⁵

Peri-Implantitis:

Periimplantitis begins at the coronal portion of the implant, (fig: 3) while the more apical portion of the implant maintains an osseointegrated status. This means that the implant is clinically not mobile until the late stages when bone loss has progressed to involve the complete implant surface.

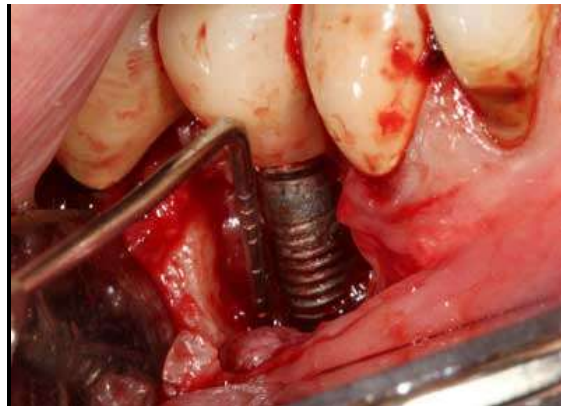


Fig 3:-

Etiology:

Bacterial infection and biomechanical factors are found to be the two major etiologic factors which are associated with resorption of crestal periimplant bone tissue with an overloaded implant site.

Experimental and clinical evidence supports the concept that excessive biomechanical forces may lead to high stress or microfractures in the coronal bone-to-implant contact and thus lead to loss of osseointegration around the neck of the implant (Hadeen et al 1998, Quirijnen et al 1990)³⁷.

Removal Of Failed Implants:

In cases in which osseointegration has been reduced severely and bone loss has extended into the apical half of the implant, or in which the implant demonstrates mobility, implant removal should be considered. After the implant is removed, ridge defects can be reconstructed to their original level using bone graft and membrane techniques. This treatment usually enables the clinician to place new implants in a previously compromised situation.

Indications for Implant removal are:

1. Severe periimplant bone loss (>50% of implant length)

2. Bone loss involving implant vents or holes
3. Unfavorable advanced bone defect (one wall)
4. Rapid, severe bone destruction (within 1 year of loading)
5. Non-surgical or surgical therapy ineffective
6. Esthetic area precluding implant surface exposure

Conclusion:-

Truly to De Vans dictum of meticulous preservation of what remains is more important than meticulous replacement of what is missing. The most desired characteristics of an implant are those that ensure the tissue - implant interface will be established quickly and then will be firmly maintained. Long term success of dental implants was previously based on osseointegration status which was measured by parameters such as mobility, suppuration and peri-implant bone loss. However more recently they should also meet certain esthetic and functional requirements.

The success of dental implants is difficult to predict as it depends on various biomechanical factors. It is difficult to assess whether the various modifications in the latest implants deliver improved performance so, it is well established that the failure can occur even under best care.

Abbreviations:

Mds: Master In Dental Surgery

Dept. Department

Fig: Figure

Declarations:

Ethical Approval: Not Applicable

Consent For Publication: Given To The Journal Of Implant Dentistry

Availability Of Supporting Data: References Attached

Competing Interest: Nil

Funding: Nil

Authors Contribution: Not Applicable

Acknowledgement: Nil

Authors Information: Nil

References:-

1. Misch CE. Contemporary implant dentistry. Implant Dentistry. 1999 Jan 1;8(1):90.
2. Goutam M, Singh M, Patel D, and Goutam M. Effect of smoking on the success of dental implant: A literature review. Int Dent J Stud Res. 2003;1:44-50.
3. Brånemark PI, Hansson BO, Adell R, Breine U, Lindström J, Hallén O et al. Osseointegrated implants in the treatment of the edentulous jaw. Experience from a 10-year period.Scand J Plast Reconstr Surg 1977; 16:1-132
4. Jaffin RA, and Berman CL. The excessive loss of Branemark fixtures in type IV bone: a 5- year analysis. Journal of periodontology. 1991 Jan;62(1):2-4.
5. Lang LA, May KB, and Wang RF. The effect of the use of a counter-torque device on the abutment-implant complex. The J Prosthet Dent. 1999 Apr 1; 81(4):411-7.
6. Bain CA, Weng D, Meltzer A, Kohles SS, and Stach RM. A meta-analysis evaluating the risk for implant failure in patients who smoke. Int j oral maxillofac impl 1994; 9:653-662.
7. Yeshwante B, Patil S, Baig N, Gaikwad S, Swami A, and Doiphode M. dental implants- classification and success and failure- an overview-JDMS 2015 14(5) 1-8
8. Brägger U, Bürgin WB, Hämmerle CH, and Lang NP. Associations between clinical parameters assessed around implants and teeth. Clin oral impl res. 1997 Oct;8(5):412-21.
9. Ericsson I, Glantz PO, and Brånemark PI. Use of implants in restorative therapy in patients with reduced periodontal tissue support. Quintessence international (Berlin, Germany: 1985). 1988 Nov;19(11):801-7.
10. Mombelli A, and Lang NP. Antimicrobial treatment of peri- implant infections. Clin oral impl res. 1992 Dec;3(4):162-8.
11. Lindquist LW, Rockler B, and Carlsson GE. Bone resorption around fixtures in edentulous patients treated with mandibular fixed tissue-integrated prostheses. J prosthet dent. 1988 Jan 1;59(1):59-63.

12. Sullivan DY, Sherwood RL, Collins TA, and Krogh PH. The reverse-torque test: a clinical report. *Int J Oral Maxillofac Impl.* 1996 Mar 1;11(2).
13. Morris HF, Ochi S, and Winkler S. Implant survival in patients with type 2 diabetes: placement to 36 months. *Ann of Periodontol.* 2000 Dec; 5(1):157-65.
14. Sembulingam K, and Sembulingam P. *Essentials of medical physiology.* JP Medical Ltd; 2012 Sep 30.
15. Curtis Jr JW. Implant placement and restoration following bone marrow transplantation for chronic leukemia: a case report. *Int J Oral Maxillofac Impl.* 1996 Jan 1;11(1).
16. Edwards CR, Bouchier IA, Haslett C, and Chilvers ER. *Davidson's principles and practice of medicine.* Edinburgh: Churchill Livingstone; 1991 Sep 20.
17. Fujimoto T, Niimi A, Sawai T, and Ueda M. Effects of steroid-induced osteoporosis on osseointegration of titanium implants. *Int J Oral & Maxillofac Impt.* 1998 Mar 1; 13(2).
18. Rajendran R. *Shafer's textbook of oral pathology.* Elsevier India; 2009.
19. Heckmann SM, Heckmann JG, and Weber HP. Clinical outcomes of three Parkinson's disease patients treated with mandibular implant overdentures. *Clin oral impl res.* 2000 Dec;11(6):566-71.
20. Van Steenberghe D, Jacobs R, Desnyder M, Maffei G, and Quirynen M. The relative impact of local and endogenous patient- related factors on implant failure up to the abutment stage. *Clin oral impl res.* 2002 Dec; 13(6):617-22.
21. Bain CA, and Moy PK. The association between the failure of dental implants and cigarette smoking. *Int J Oral & Maxillofac Impl.* 1993 Nov 1;8(6).
22. De Bruyn H, Collaert B. The effect of smoking on early implant failure. *Clin oral imp res.* 1994 Dec;5(4):260-4.
23. Esposito M, Hirsch JM, Lekholm U, and Thomsen P. Biological factors contributing to failures of osseointegrated oral implants,(I). Success criteria and epidemiology. *Eur j oral sci.* 1998 Feb;106(1):527-51.
24. Jacobsson M. *On Bone Behaviour After Irradiation.* 1985(Doctoral dissertation, Ph. D. Thesis. Biomaterials Group, Dept of Anatomy, institute for Applied Biotechnology, University of Göteborg, Göteborg, Sweden, 1985. Thesis).
25. Albrektsson T. A multicenter report on osseointegrated oral implants. *J Prosthet Dent.* 1988 Jul 1;60(1):75-84.
26. Granström G, Tjellström A, Brånemark PI. Osseointegrated implants in irradiated bone: a case-controlled study using adjunctive hyperbaric oxygen therapy. *J oral and maxillofac surg.* 1999 May 1;57(5):493-9.
27. Glantz PO. Aspect of prosthodontic design in Branemark PI Zarb GA, Albrektsson T. *tissue integrated prosthesis. Osseointegration in clinical dentistry.* Carol Stream, IL, Quintessence Publishing, 1985, 329-331.
28. Naert I, Quirynen M, van Steenberghe D, and Darius P. A study of 589 consecutive implants supporting complete fixed prostheses. Part II: Prosthetic aspects. *The J prosthet dent.* 1992 Dec 1;68(6):949-56.
29. Steinemann S. The properties of titanium. In Schoeder A, Sulter F, Buser D, Krekeler G. *oral implantology. Basics ITI Dental Implant System.* 2nd edn. New York: Theime Medical Publishers, 1996: 37-59. *Oral Maxillofac Implants* 2000; 15:811-818, cited in *periodontal* 2000; 33: 163-171.
30. Meffert RM, Langer B, and Fritz ME. Dental implants: a review. *J periodontol.* 1992 Nov;63(11):859-70.
31. Meschenmoser A, d'Hoedt B, Meyle J, Elßner G, Korn D, Hämmerle H, et al. Effects of various hygiene procedures on the surface characteristics of titanium abutments. *J periodontol.* 1996 Mar;67(3):229-35.
32. Hallmon WW, Waldrop TC, Meffert RM, and Wade BW. A comparative study of the effects of metallic, nonmetallic, and sonic instrumentation on titanium abutment surfaces. *Int J Oral Maxillofac Impl.* 1996 Jan 1;11(1).
33. Bailey GM, Gardner JS, Day MH, and Kovanda BJ. Implant surface alterations from a nonmetallic ultrasonic tip. In *J Western Society of Periodontol/Periodontal abstracts* 1998 (Vol. 46, No. 3, pp. 69-73).
34. Darby ML. *Mosby's Comprehensive Review of dental hygiene,* 5th edition 2002; 708-710.
35. Gantes BG, and Nilveus R. The effects of different hygiene instruments on titanium surfaces: SEM observations. *The International journal of periodontics & restorative dentistry.* 1991;11(3):225.
36. Staurt J Froum . *Dental implant complication and failure*
37. Hadeed GJ, Ismail YH, Garrana H, and Pahountis LN. Three-dimensional finite element stress analysis of Nobelpharma and Core-Vent implants and their supporting structures. *J Dent Res.* 1988;67:286.