



Journal Homepage: -www.journalijar.com

INTERNATIONAL JOURNAL OF ADVANCED RESEARCH (IJAR)

Article DOI:10.21474/IJAR01/10902
DOI URL: <http://dx.doi.org/10.21474/IJAR01/10902>



RESEARCH ARTICLE

HURLER SYNDROME: A CASE REPORT AND A REVIEW OF THE LITERATURE

S.A. Malik, K. Imrani, N. Allali, S. El Haddad and L. Chat
Pediatric Imaging Department, Pediatric Teaching Hospital-Rabat-Morocco.

Manuscript Info

Manuscript History

Received: 05 March 2020
Final Accepted: 07 April 2020
Published: May 2020

Key words:-

Mucopolysaccharidosis (MPS) Type I,
Hurler Syndrome, Neurologic
Manifestations

Abstract

Clinical manifestations of the different types of mucopolysaccharidosis vary from one type to another. MPS type I show a chronic, progressive and multisystemic evolution and Hurler syndrome remain the most severe form of mucopolysaccharidosis type I. The involvement of the central nervous system is characteristic and MRI remains the imaging of choice to assess cerebral and spinal cord abnormalities. [8] Certain diagnosis only retained after biochemical proof of the enzyme deficiency. Some neuroimaging features are characteristic of Mucopolysaccharidosis. However, the correlation between them and disease severity remains controversial, without well-established imaging biomarkers at this time. The role of imaging is to evaluate disease progression and detect some complications particularly cord compression or massive hydrocephalus, so that the patient can benefit from early intervention before the installation of irreversible damage [8]. Early diagnosis remains a key success factor essential to prevent the appearance of irreversible lesions and increase the benefits of treatment.

Copy Right, IJAR, 2020., All rights reserved.

Introduction:-

Mucopolysaccharidosis type I (MPS) are lysosomal overload diseases due to glycosaminoglycan's degradation defect by deficiency of the alpha-L-iduronidase enzyme. This enzyme is responsible for intralysosomal accumulation of GAG resulting in their increased excretion in the urine [1,3,9].

MPS type I occurs in the form of a phenotypic continuum from Hurler syndrome (a severe phenotype with severe cognitive impairment) to Scheie syndrome passing through the intermediate Hurler Scheie phenotype [1].

These autosomal recessive transmission diseases are characterized by great heterogeneity in clinical and biological aspects, which makes their diagnosis difficult [7].

Case report:

A 12 years old girl, admitted to emergency for corticospinal tract syndrome. On clinical examination, we discovered a facial dysmorphism with macrocephaly, macroglossia, gingival hypertrophy, psychomotor developmental delay, stubby hands, and dorsal kyphosis. We concluded to the diagnosis of a malformation syndrome. An additional genetic consultation confirmed the diagnosis of MPS I H (or Hurler syndrome). Biological assessment was in favour of an increase of urinary glycosaminoglycans. Radiology examinations revealed multiple dysostoses, an active quadriventricular hydrocephalus with a dilatation of Virchow-Robin spaces, and a thickened C1-C2 posterior

Corresponding Author:- S.A. Malik

Address:- Pediatric Imaging Department, Pediatric Teaching Hospital-Rabat-Morocco.

ligament extending over 34 mm with spine compression. A general treatment with enzymotherapy has been started and the child is waiting for a bone marrow transplant.

Discussion:-

Hurler syndrome is the most severe form of mucopolysaccharidosis type I (MPS I), its prevalence is estimated at 0.69 to 3.8 per 100,000 live births [1]. It is due to an autosomal recessive genetic disorder that affects the IDUA gene (chromosome 4p16.3). The clinical manifestations of MPS I show a chronic, progressive and multisystemic evolution [1-7].

Patients with Hurler syndrome present with multi-systemic involvement, including developmental delay, hepatosplenomegaly, dysostosis, arthropathies and a “gargoyle” facies. Their auditory, visual, respiratory and cardiovascular functions are also affected. Clinical signs appear from the first 2 years of life, life expectancy being around 10 years. [1,4,6]

The child is born after a normal pregnancy, neonatal examination is normal but a giant mongoloid spot as well as a megacornate can be observed. The signs appear gradually, during the first year of life. The diagnosis is usually made under the observation of visceral and orthopedic signs between the 4th and the 18th months.

The clinical picture usually moves towards multi-visceral involvement, but symptomatology that is often partial and the slow evolution of moderate forms make the diagnosis often difficult. Certain diagnosis is only retained after biochemical proof of the enzyme deficiency. [7,9,4]

Clinical manifestations of the different types of MPS vary from one type to another. The involvement of the central nervous system is characteristic and MRI remains the imaging of choice to assess cerebral and spinal cord abnormalities. [2,6,8]

Skeletal anomalies are grouped under the term of multiple dysostosis and are elements of orientation towards MPS [5].

Several aspects are found: Skull (macrocephaly, premature closure of the sagittal suture, saddle turcica flared in the shape of a J, malformation of the teeth...), chest (short and thick collar bones, enlarged ribs, tapered at their insertion vertebral...), spine (antero-superior hypoplasia of the vertebral bodies of the thoracolumbar hinge, oval vertebral bodies, reduced in height or flattened, secondary thoracolumbar kyphosis), long bones (metaphyseal and diaphyseal enlargement, delay epiphyseal ossification). [5,6]

Neurological aspects are characterized by anomalies common to all MPS (perivascular spaces increase, white matter anomalies, ventriculomegaly, cortico-subcortical atrophy) without any specific radiological abnormality being demonstrated or any correlation between the anomalies observed and the clinical severity [2,6,11].

Ct scans allow the diagnosis of hydrocephalus, cerebral atrophy, white substance hypodensity, flared sellaturcica, arachnoid cysts, dura mater infiltration, and odontoid dysplasia [2,6].

On MRI, we typically found a white matter cribriform appearance, corpus callosum and basal ganglia, due to accumulation of GAG in Virchow Robin spaces, represented by multiple deep pseudo lacunar images that appear to be located in the white matter but actually correspond to spaces expansion [6].

We can also notice a white matter signal abnormality predominantly periventricular and in the oval centers suggesting gliosis, edema, or demyelination. Cortical atrophy are frequently observed, and arachnoid cysts are occasionally seen.

In addition, MR spectroscopy shows a broad peak around 3.7 ppm, considered to contain signals from accumulated GAG.

Enzyme replacement therapy consists on intravenous administration of the recombinant alpha-L- iduronidase enzyme at regular intervals, which reduces lysosomal overload and thus improves some clinical signs [7]. However, it does not cross the hematopoietic barrier, hence its low neurological efficiency. In addition, its high cost reduces its

accessibility. Hematopoietic stem cell transplantation is currently the treatment of choice in Hurler's disease, especially when performed early before the onset of psychomotor developmental delay. [3,7,10]

These treatments should be combined with psychological support and genetic counseling. The genes of the different enzymes involved are now located and many mutations have been identified. Prenatal diagnosis is possible on culture of amniotic cells. [3,10]

Whatever the form of treatment chosen, early diagnosis remains a key success factor essential to hope to prevent the appearance of irreversible lesions and increase the benefits of treatment.

Conclusion:-

Patients with Hurler disease must benefit from a multidisciplinary and global diagnostic approach, before any biological confirmation. This allows exploring and treating multi-systemic disorders that this condition generates, at the early stage, since symptomatic treatment is of certain importance.

It therefore seems essential that everyone be aware of clinical signs of mucopolysaccharidosis type I in order to undertake early appropriate additional examinations and optimize therapeutic management.

Enzyme treatment alternatives generates great hope for patients because of its effectiveness on non-neurological disease symptoms, but its high cost limits its accessibility.

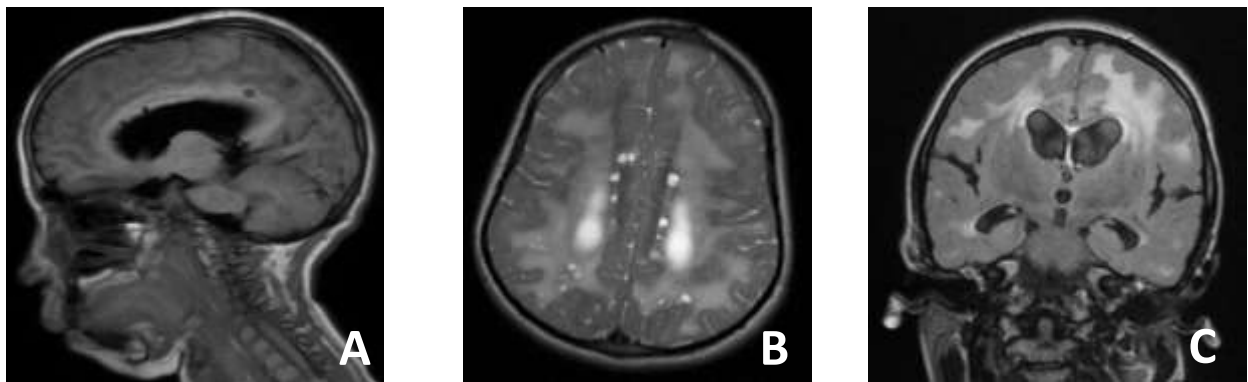


Figure 1:- Axial T2- weighted MR image (B), Sagittal T1 (A) and coronal Flair (C) of the brain: marked perivascular space enlargement in the corpus callosum and subcortical white matter, isointense to cerebrospinal fluid at all sequences.

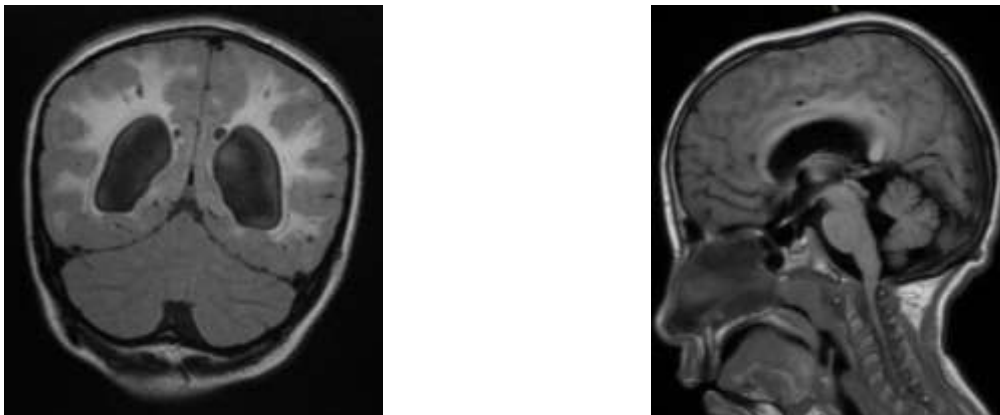


Figure 2:- Coronal FLAIR weighted MR image of the brain: Symmetric periventricular white matter lesions, associated with mild ventriculomegaly (A). Sagittal T1-weighted MR image of the cervical spine: Large isointense soft-tissue mass surrounding the short odontoid process and the anterior arch of C1, determining substantial reduction of spinal canal caliber and consequent compression of the spinal cord (B).

References:-

1. Belaid Imessaoudene, Sihem Hallala,*, Meriem Amina Ghoualia, Arezki Berhounea. La maladie de Hurler : à propos de 30 cas. Revue francophone des laboratoires – Novembre 2011 - n°436.
2. B. Héron. Neurologic manifestations in mucopolysaccharidoses, Archives de Pédiatrie 2014;21: S14-S21.
3. S. Leroux, J.-B. Mullera,*, E. Boutarica, A. Busnel, F. Lemouela, M. Andro-Garc ,ona, B. Nevenb, V. Valayannopoulos, C. Vincelasa. Hurler syndrome : Early diagnosis and treatment. Archives de Pédiatrie 2014;21:501-506 0929-693X/ 2014 Elsevier Masson SAS.
4. N. Alif I*, K. Hess, J. Straczekz, S. Sebbar, Y. Belahsenl, N. Mouane, A. Abkari, P. Nabet, M.A. Gelot. Mucopolysaccharidose de type I au Maroc : manifestations cliniques et profil génétique. Arch Wdiatr 2000 ; 7 : 597-604.
5. F.Chalard, C.Falip, G.Kalifa, G.Sebag. Imagerie des maladies métaboliques osseuses.Service de Radiologie, Hôpital Robert Debré.Journée de radiologie pédiatrique-Trousseau 16,17,18 janvier 2008.
6. Roberta Reichert , Lillian Gonçalves Campos, Filippo Vairo, Carolina Fischinger Moura de Souza, Juliano Adams Pérez, Juliana Ávila Duarte, Fernando Araujo Leiria, Maurício Anés, Leonardo Modesti Vedolin.Neuroimaging Findings in Patients with Mucopolysaccharidosis: What You Really Need to Know. RadioGraphics 2016; 36:1448–1462
7. Vedolin L, Schwartz IV, Komlos M, et al. Brain MRI in mucopolysaccharidosis: effect of aging and correlation with biochemical findings. Neurology 2007;69(9):917–924. 6. Muenzer J. The mucopolysaccharidoses: a heterogeneous group of disorders with variable pediatric presentations. J Pediatr 2004;144(5 suppl):S27–S34.
8. Khan SA1, Sehat K, Calthorpe D.Spine (Phila Pa 1976). Cervical cord compression in an elderly patient with Hurler's syndrome: a case report. US National Library of MedicineNational Institutes of Health 2003 Aug 15;28(16):E313-5.
9. Clarke LA. Mucopolysaccharidosis Type I. Initial Posting: October 31, 2002; Last Update: February 11, 2016. In: Adam MP, Ardinger HH, Pagon RA, et al., editors. GeneReviews® [Internet]. Seattle: University of Washington; 1993–2018. Available from: <http://www.ncbi.nlm.nih.gov/books/NBK1162>. Visited on August 18, 2018.
10. Muenzer J, Wraith JE, Clarke LA. International Consensus Panel on Management and Treatment of Mucopolysaccharidosis I. Mucopolysaccharidosis I: management and treatment guidelines. Pediatrics. 2009; 123(1):19–29. <https://doi.org/10.1542/peds.2008-0416>.
11. Hamid Assadeck, Moussa Toudou Daouda, Harouna Bako & Fatimata Hassane Djibo. Hurler–Scheie syndrome in Niger: a case series. Journal of Medical Case Reports volume 13, Article number: 102 (2019).