



Journal Homepage: - www.journalijar.com
**INTERNATIONAL JOURNAL OF
 ADVANCED RESEARCH (IJAR)**

Article DOI: 10.21474/IJAR01/3918
 DOI URL: <http://dx.doi.org/10.21474/IJAR01/3918>



RESEARCH ARTICLE

A NEW APPROACH FOR MAKING A HOLLOW DENTURE USING CAMELIZED SUGAR AND PUMICE MIX- A CLINICAL REPORT.

Dr. Dhakshani M.R¹, *Dr. Supriya Chauhan², Dr. Raghavendraswamy KN³ and Dr. Anil Kumar Gujjari⁴

1. Professor and Head, Department of Prosthodontics and crown & bridge, JSS dental college and hospital, A Constituent college of Jagadguru Sri Shivarathreeswara University, SS Nagara, Mysuru, 570015, Karnataka, India.
2. PG Student, Department of Prosthodontics and crown & bridge, JSS dental college and hospital, A Constituent college of Jagadguru Sri Shivarathreeswara University, SS Nagara, Mysuru, 570015, Karnataka, India.
3. Professor, Department of Prosthodontics and crown & bridge, JSS dental college and hospital, A Constituent college of Jagadguru Sri Shivarathreeswara University, SS Nagara, Mysuru, 570015, Karnataka, India.
4. Principal and Professor, Department of Prosthodontics and crown & bridge, JSS dental college and hospital, A Constituent college of Jagadguru Sri Shivarathreeswara University, SS Nagara, Mysuru, 570015, Karnataka, India.

Manuscript Info

Manuscript History

Received: 19 February 2017
 Final Accepted: 13 March 2017
 Published: April 2017

Abstract

Fabricating a denture with perfect retention, stability and support is a challenging task for a prosthodontist. In the patients with long lips or highly resorbed ridges the denture height has to be increased which might compromise on these principles. With the increase in height subsequent increase in weight also occurs. For achieving a satisfactory esthetics, retention, stability and support, it becomes mandatory to make the denture light. This paper describes a simplified approach for making a hollow denture using sugar caramel and pumice mixture. This technique allows the caramelized sugar pumice to be bounded and stiff to sustain the packing pressure. At the same time it also dissolves easily when it comes in contact with water. The area required to be hollow is entirely under the control of the dentist with this cost effective and simple technique.

Copy Right, IJAR, 2017,. All rights reserved.

Introduction:-

Severely atrophied maxilla and long lips possess a clinical challenge for fabricating a successful denture. In order to attain an acceptable occlusal plane, the final result is a long and heavy denture. The denture thus formed has compromised retention and stability owing to the gravitational pull and unusual leverage.[El Mahdy 1969] Reducing the weight of the obturators have been successfully tried. Various methods have been tested in the past to reduce the weight of the dentures. Materials used to make the cavity in the planned space in dentures were dental stone[Challian 1972], silicone putty[Holt 1981, O'Sullivan 2004], modeling clay[Eliott 1983], thermocol, salt etc. primary problem with salt was that it was not easy to control the spread while packing. Salts could not be confined in the planned hollow space, which could result in exposure in the unwanted denture surface. Thermocol dissolves readily on contacting with the monomer. Other procedures were difficult to retrieve or costly. This led to the necessity of a material which was easy to contain and easy to retrieve. This paper describes an innovative method of using the sugar and pumice mix to create a hollow denture.

Corresponding Author: - Supriya Chauhan.

Address:- Department of Prosthodontics and crown & bridge, JSS dental college and hospital, A Constituent college of Jagadguru Sri Shivarathreeswara university, SS Nagara, Mysuru, 570015, Karnataka, India.

Case Report:-

A 82 year old man reported to the Department of Prosthodontics and Crown & Bridge, JSS Dental College and Hospital, a constituent college of Jagadguru Sri Shivarathreeswara University, Mysuru, Karnataka with looseness of the previous dentures and desired the replacement of the same. He had been edentulous since 13 years and a denture wearer since 12 years. Intraoral examination revealed that he had a more than normal interarch distance. Extraoral examination revealed a long unsupported lip. Considering his requirements a treatment plan was made. It was decided to provide him with a hollow denture.

Preliminary and final impressions were made in the conventional way. Jaw relation was carefully recorded because of the long lip length and an increased interarch distance. After teeth selection and teeth arrangement, try in was done. All the methods were conventionally followed till dewaxing (Figure 1).

- ❖ After dewaxing a layer of aluminum foil was adapted to the cast in the dewaxed mould (Figure 2).
- ❖ Sugar and pumice was mixed and placed on a spatula. Spatula containing the mix was heated over the flame till the sugar caramelized; this can be assured by the change in the color of the mixture to brown. The hot melted sugar and pumice mix was in a flowable consistency, and hence poured carefully from one end over the aluminum foil to the other (Figure 3).
- ❖ This mixture was allowed to set till it became hard.
- ❖ A layer of wax was placed over the teeth in the counter flask and inverted over the caramelized sugar mix to check the overextensions if any. Any overextension of the sugar mix will be seen as an indentation on the wax. The overextended area of the caramelized sugar mix can be carefully trimmed with a sharp knife. This stage helps to inspect and plan the exact hollow area required. This also allows making sure if there is sufficient space for a uniform layer of acrylic resin on the buccal and palatal surface.
- ❖ The hard set mixture is then peeled off easily from the aluminum foil (Figure 4,5).
- ❖ Separating medium is applied to both the sides of the flask, like in a conventional packing.
- ❖ A thin layer of heat cure poly methyl methacrylate (DPI, Mumbai) is placed in a dough stage on both the sides of the dewaxed moulds.
- ❖ The set caramelized sugar pumice mix is then placed over the acrylic dough in one of the sides of the mould and packed (Figure 6). This mixture doesn't shift during packing due the hard consistency of the caramelized sugar.
- ❖ After processing, denture is deflasked, trimmed and polished.
- ❖ A layer of brown caramelized sugar and pumice can be easily detected (Figure 7).
- ❖ Holes are created on the flange area and the denture is immersed in water for 2 days. The sugar mix dissolves and the remnants, if any, are cleared by forceful injection of water into the holes.
- ❖ The holes are then filled with autopolymerizing polymethylmethacrylate (DPI RR, Mumbai) in a doughy consistency (Figure 8). Hollow consistency was confirmed by placing the denture in water. The denture must float and no air bubbles must be evident.
- ❖ Denture is trimmed, polished and inserted in the patient's mouth (Figure 7). Post insertion instructions were explained to the patient.

Brief summary of the procedure:-

1. Dewaxing
2. Place Aluminum foil on the cast
3. Heat sugar and pumice (equal quantity) on a spatula
4. Flow the heated viscous mix on the aluminum foil
5. Let it set
6. Place a sheet of wax on counter flask
7. Invert the counter flask for trial closure
8. Check the indentation on the wax
9. Any indentation on the wax means insufficient space for acrylic resin in that area
10. Trim the excess pumice sugar mix from the area indenting on the wax
11. Peel off the aluminum foil from the mix
12. Apply separating media
13. Place thin layer of heat cure acrylic resin on both the halves of the flask
14. Create a trough on the teeth area
15. Place the sugar pumice mix in the trough
16. Invert the counter flask on it
17. Process the denture

- 18. Drill two holes on the buccal sides
- 19. Place the denture in water
- 20. All the sugar pumice gets dissolved
- 21. Fill the holes with autopolymerizing resin
- 22. Trim and polish the denture



Figure 1:- Dewaxed moulds

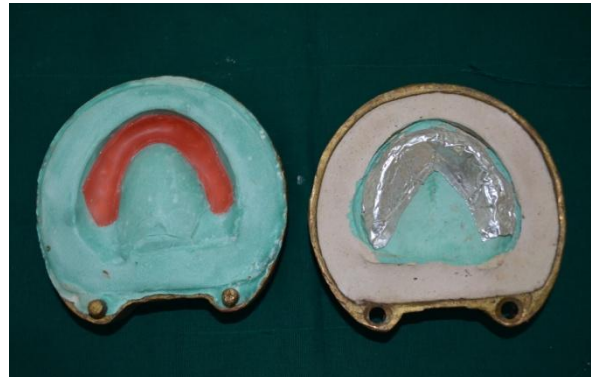

Figure 2:- Two layers of aluminum foil on the cast side of the flask and one layer of wax sheet placed on the counter flask containing teeth

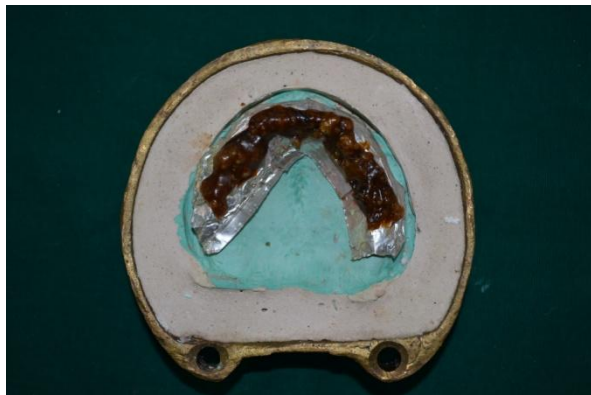

Figure 3:- sugar pumice mixture caramelized and placed carefully on the aluminum foil.

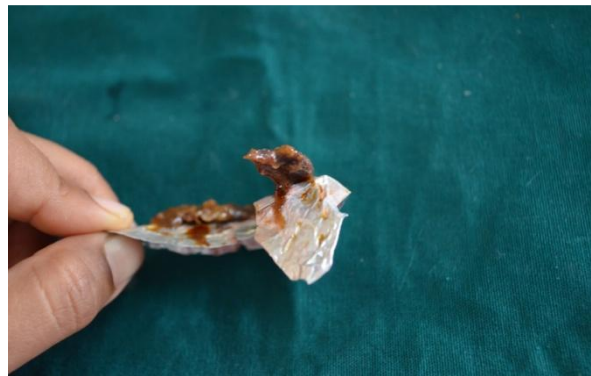

Figure 4:- Aluminum foil peeled off from the set sugar pumice mixture

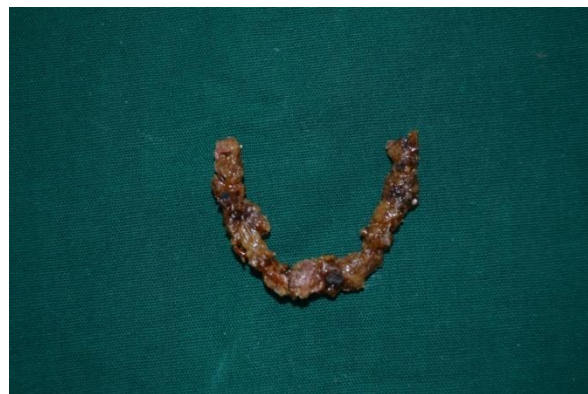


Figure 5:- sugar pumice mixture is hard enough to be contained in the resin dough without getting displaced.

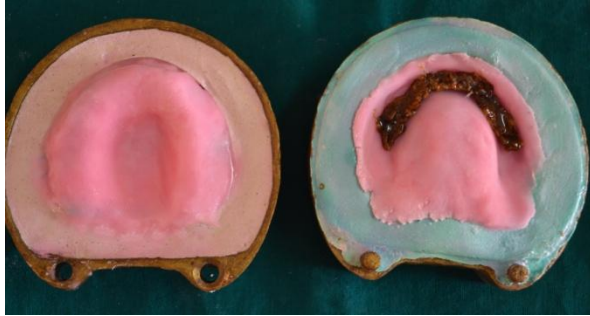

Figure 6:- sugar pumice mixture is placed in the flask containing teeth and sandwiched between two layers of acrylic dough.

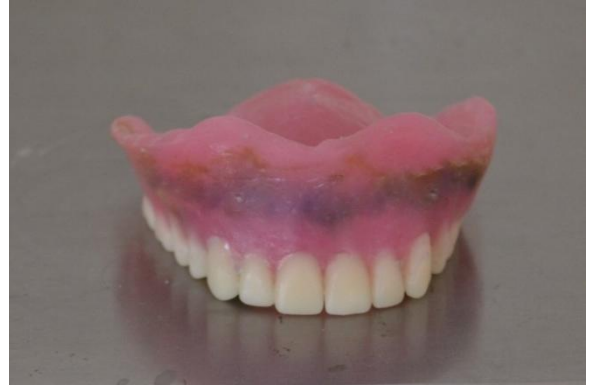

Figure 7:- Processed denture with sugar pumice mixture.

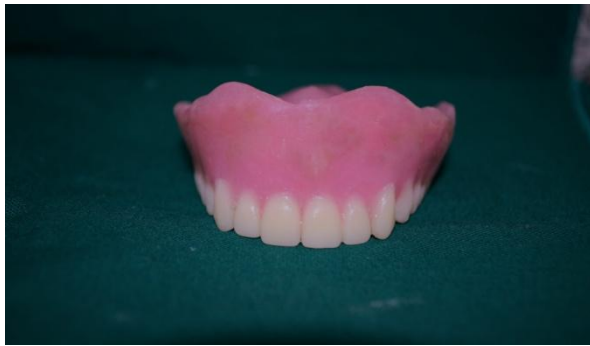

Figure 8:- After removal of pumice sugar mix.

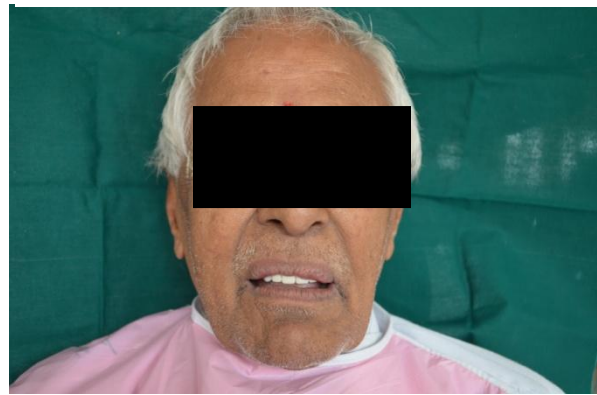

Figure 9:- Post insertion photograph.

Discussion:-

Geriatric patients have limited treatment modalities when it comes to rehabilitation of the missing teeth. Heavy dentures have the poor retentive ability and cause a lot of discomfort. Reducing the weight in such cases give a satisfactory result. Lost salt technique is the most widely used technique to make a denture hollow. But it is difficult to contain salt at a particular area. The present article describes the technique using caramelized sugar and pumice which becomes hard when set and doesn't change in shape during packing. Also the retrieval is not a difficult procedure.

Some authors suggest the use of putty for creating hollow space, but putty is a costly material and also retrieval of putty is a cumbersome task. Thermocol do not stay in one particular position. If stabilizing the thermocol is attempted by using cyanoacrylate, thermocol is seen to dissolve. Thermocol also dissolves by monomer during packing. This questions the credibility of the thermocol to be used as an effective material in hollow dentures.

The main advantage of caramelized sugar is the containability and easy retrievability. The sugar and pumice mixture when heated forms a viscous fluid and flows easily to the desired area (on the aluminum foil). After cooling this mixture becomes hard and sustain its shape without distorting. This hard set mix can be placed wherever possible, easily without sticking or breaking. When it comes in contact with water, it readily dissolves and creates a hollow cavity. Precaution to be taken in this present technique is the dimension of the sugar mix. The dimension should not be too big to take up the space for the acrylic resin around the sugar pumice mix. To check this, a sheet of wax is kept on the counter flask and trial closures are performed till uniform space for resin is established. The disadvantage of this procedure could be the time consuming nature and the handling of the sugar till a precise temperature requires skill of the clinician.

Conclusion:-

Modification in the impression procedures is paid attention to, in the resorbed ridge cases. Similarly, weight of the denture should be considered as a very important factor in the planning of the dentures. Light weight dentures help to prevent the detrimental forces and maintain the health of the already abused underlying tissue and bone. This technique is simple and effective. The clinician has entire control of the space to be made hollow with easy placement of the material and easy retrievability.

References:-

1. Chalian VA, Barnett MO. A new technique for constructing a one piece hollow obturator after partial maxillectomy. *J Prosthet Dent* 1972; 28: 448-53.
2. El Mahdy AS. Processing a hollow obturator. *JPD* 1969;22:682-6.
3. Elliott DJ. The hollow bulb obturator: its fabrication using one denture flask. *Quintessence Dent Technol* 1983; 7: 13-4.
4. Holt RA Jr. A Hollow Complete Lower Denture. *J Prosthet Dent* 1981; 45: 452-4.
5. O'Sullivan M et al. The hollow maxillary complete denture: A modified technique. *J Prosthet Dent* 2004; 91: 591-4.