



Journal Homepage: -www.journalijar.com
**INTERNATIONAL JOURNAL OF
 ADVANCED RESEARCH (IJAR)**

Article DOI:10.21474/IJAR01/7212
 DOI URL: <http://dx.doi.org/10.21474/IJAR01/7212>



RESEARCH ARTICLE

DIAGNOSTIC RELIABILITY OF BLIND FNAC AND ULTRASOUND GUIDED FNAC USING HISTOPATHOLOGICAL DIAGNOSIS AS THE GOLD STANDARD.

Baba iqbal khaliq¹, Bilal ahmad sheikh², baba aijaz khaliq³, omar sharif kirmani⁴ and farzana manzoor⁵.

1. Senior resident department of pathology.
2. Proffesor department of pathology.
3. Senior resident department of ent.
4. Associate proffesor department of radiodiagnosis.
5. Post graduate department of pathology government medical college srinagar kashmir 190010.

Manuscript Info

Manuscript History

Received: 05 April 2018
 Final Accepted: 07 May 2018
 Published: June 2018

Keywords:-

Fnac (fine needle aspiration cytology),tbsrtc(the bethesda system of reporting thyroid ytopathology),hpe(histopathological examination) benign,malignant.

Abstract

Background: thyroid swellings are common clinical problems and it is important to know exact pathology before treating such conditions. Fnac is now a well-established, cheap, reliable and safe first line diagnostic test for the evaluation of diffuse thyroid lesions with the main purpose of confirming benign lesions and thereby, reducing unnecessary surgeries. Ultrasound guided fnac has the potential to reduce inadequacy rates and is regarded as the optimal cytological method for diagnosis.

Objective: to compare the results of blind and ultrasound-guided fnac of thyroid swellings and to find out the diagnostic reliability of blind fnac and ultrasound-guided fnac using histological diagnosis as the gold standard.

Methods: hundred patients with thyroid swelling who were subjected to blind and ultrasound-guided fnacs and who subsequently underwent surgery over 2 and a half years were studied.

Results: ultrasound guided fnac results revealed 64% benign lesions and 29 % of malignant lesions, and blind fnac revealed 54% benign and 20% malignant cases. Histological gold standard diagnosis comprised of 57 % benign and 43 % malignant cases. Sensitivity and specificity of blind fnac as compared to hpe was 91.48% and 87.7%, positive predictive value (ppv) and negative predictive value (npv) was 84.31% and 93.4%,while sensitivity, specificity, ppv and npv of usg guided fnac as compared to hpe was 97.7%, 92%, 89.58% and 98.27% respectively.

Conclusion: blind fnac of thyroid swellings is more convenient and cost effective as compared to ultrasound guided fnac. However, the diagnostic yield in ultrasound guided fnac is significantly more in terms of accuracy.ultrasound guided fnac significantly helps in categorising the tbsrtc category i patients and guides there subsequent management.

Copy Right, IJAR, 2018,. All rights reserved.

Introduction:-

Thyroid nodules represent a common problem in ent & hns, with an estimated prevalence of 4-7% in the adult population for palpable nodules. The prevalence is higher in women (5%) than in men (1%)¹. The prevalence of nodules found during autopsies, operations or ultrasound examinations is considerably higher and increases with age²⁻⁴. The majority of nodules are benign. Cancer can be present in 3–10% of nodules, depending on age, gender, radiation exposure, family history, and other factors⁵. Over the last few years, many advances have been achieved in diagnosing thyroid nodules. In addition, various clinical and radiological features have been studied to increase detection rate of differentiated thyroid carcinoma. Unfortunately, these features lack specificity and sensitivity⁶⁻⁹, and none have been so far recommended for a routine use¹⁰ fnac has been established as the first line diagnostic test for thyroid lesions and has proven to be the most valuable modality for preoperative distinction of benign from malignant nodules and to confirm the diagnosis¹¹. The accuracy of fnac and the inadequacy rates are influenced by operator technique, experience and the reliability of inserting the needle into the area of interest particularly in cystic nodules. Ultrasound guided fnac has the potential to reduce inadequacy rates, to facilitate accurate targeting of the lesion, to sample the part most likely to yield diagnostic material and to sample the solid portion of cystic nodules which are too small for palpation¹². Recently, using ultrasound guided fnac increased the sensitivity ranging from 65% to 98%, whereas; the specificity ranges from 72% to 100%, with overall accuracy for cytological diagnosis approaches 95%¹³⁻¹⁸. This study was done to compare the results of blind v/s ultrasound-guided fnac in cases of thyroid swellings keeping histopathology as gold standard

Methods:-

This study was conducted in department of pathology government medical college srinagar in collaboration with department of ent and department of radiodiagnosis government medical college srinagar kashmir from august 2014 to february 2017. Patients presenting with thyroid swelling were subjected to blind fnac followed by ultrasound guided fnac after taking proper consent. Only those patients who subsequently underwent surgery were included in the study and those in whom surgery was not done were excluded from study. Total 100 patients were included in study. After taking informed consent in local language all patients with thyroid swelling underwent blind fnac followed by ultrasound guided fnac and subsequently underwent surgery and histopathological examination of specimen was done and subsequently compared with fnac findings (both blind as well as usg guided).

Results:-

The 100 patients included in this study who underwent surgery for thyroid swelling following blind and ultrasound guided fnac were studied and the following observations were made. The age of patients ranged from 11 to 68 years (table 1). The male : female ratio was 1 : 4. Durations of symptoms ranged from 1 month to 3 years. At the time of surgery all patients were euthyroid. During blind fnac 15 cases showed nondiagnostic or unsatisfactory results (tsrtc category i) in 65 cases lesions were benign and 20 cases were diagnosed as malignant (table 2) ultrasound guided fnac revealed benign pathology in 62 cases and malignant pathology in 38 cases (table 3). postoperatively on histopathological examination 57 patients had benign pathology and 43 patients had malignancy (table 4). As compared to histopathology blind fnac showed 91.48% sensitivity, 87.7% specificity, positive predictive value of 84.31% and negative predictive value of 93.4% (table 5), while as compared to histopathology results ultrasound guided fnac showed sensitivity of 97.7%, specificity of 92%, positive predictive value of 89.58% and negative predictive value of 98.27% respectively (table 6a and 6b)

Discussion:-

The importance of fnac investigation in the diagnosis of thyroid tumors has been well established as this is a safe and cost effective and diagnostic procedure; the cost of fnac is minimal, equipment is inexpensive and the technique is simple and results are available in short time^{19,20}. Fnac is a well established method and its reliability depends on several factors, such as the skill of the physician or the experience of the cytopathologist. Use of ultrasonography in fnac increases significantly the sensitivity, specificity and accuracy compared with conventional palpation-guided fnac¹⁷.

In our study, it was observed that majority of patients presented between age group of 21 to 40 years with mean age of 34 years. Youngest patient was 11 years old boy and eldest was 65 years old male. This was similar to m. Aggarwal et al who had mean age of 36.5 years and rd bapat et al who had median age of 35 years. Most studies report the majority of the patients with thyroid swellings to be females. In this study also we observed that the major bulk of patients were females. In our study 80% patients were female and 20% were male with female : male ratio of

4:1. In a study conducted by m .aggarwal etal they found 46 (83.6%) females and 9(16.4%) males. Safirulla et al in their study also observed that 90% of the patients were females and males comprised of only 10%. In our study on blind fnac of thyroid swelling in 15 (15%)cases sample obtained was inadequate; in 54 (54%)cases lesions were benign and 20 (20%) cases were malignant. On usg guided fnac 64 (64%) patients had benign pathology , 29 (29%) patients had malignant disease. Mundasad b et al reported that fnac analysis revealed 13.88% nonneoplastic, 65.27% neoplastic and 4.16% suspicious aspirates, 13.88% samples were inadequate and 2.77% samples were indeterminate. The inadequate (non-diagnostic) sampling rate of 15% was similar to 14.55% by m aggarwal etal, 19 % rates reported by cai et al and 14% by guhamallick. In our study the sensitivity and specificity of blind fnac and usg guided fnac in predicting thyroid malignancies was 91.48%, 87.7% and 97.7% , 92% respectively. This was similar to that of m. Aggarwal etal, . The positive predictive value and negative predictive for blind fnac and ultrasound guided fnac with histopathology as the gold standard was 84.31%, 93.4%; and 85.58% , 98.27% respectively were found to be almost similar to studies by m aggarwal etal.these findings were also similar to the findings of the study conducted by moon h et al who reported that ultrasound guided fnac has a high diagnostic accuracy with the sensitivity and specificity of 65% to 98% and 72% to 100% respectively. Ogawa y et al in their retrospective study of 1012 samples from 806 thyroid nodules by usg guided method reported that the accuracy of fnac as 75 % and the rate of indeterminate diagnosis as 16 %. The false negative rate was 13 % and the positive malignancy rate was 99 %.

Age Distribution in Years	Frequency	Percentage
11-20	13	13%
21-30	23	23%
31-40	33	33%
41-50	16	16%
51-60	13	13%
61-70	2	2%
Total	100	100%

Table 1:-age distribution in years

Blind fnac variant	Frequency	Percentage	Tbsrtc category
No material	15	15%	I
Colloid, macrophages, lymphocytes,no follicular cells	10	10%	I
Lymphocytic thyroiditis	2	2%	Ii
Colloid goitre	42	42%	Ii
Colloid goiter with Papillary Hyperplasia	7	7%	Ii
Follicular neoplasm	4	4%	Iv
Medullary Carcinoma	1	1%	Vi
Papillary Carcinoma	19	19%	Vi
Total	100	100%	

Table 2:-Result of blind fnac.

Usg guided Fnac results	Frequency	Percentage	Tbsrtc category
Lymphocytic thyroiditis	4	4%	Ii
Colloid nodule	51	51%	Ii
Colloid goiter With papillary Hyperplasia	1	1%	Ii
Follicular	6	6%	Iv

Neoplasm			
Medullary Carcinoma	1	1%	Vi
Papillary Carcinoma	37	37%	Vi
Total	100	100%	

Table 3:-Result of usg guided fnac.

Histological Diagnosis	Frequency	Percentage
Lymphocytic thyroiditis	3	3%
Adenomas	3	3%
Colloid nodule	51	51%
Follicular Carcinoma	6	6%
Medullary Carcinoma	1	1%
Papillary Carcinoma	36	36%
Total	100	100%

Table 4:-histopathological results of 100 operated patients.

Sensitivity= $a/a+b$	$43/43+4= 91.48$
Specificity= $d/d+c$	$57/57+8= 87.7\%$
Ppv = $a/a+c$	$43/43+8= 84.31\%$
Npv = $d/b+d$	$57/57+4= 93.4\%$

Table 5:-showing sensitivity, specificity, positive predictive value and negative predictive value of blind fnac as compared to hpe

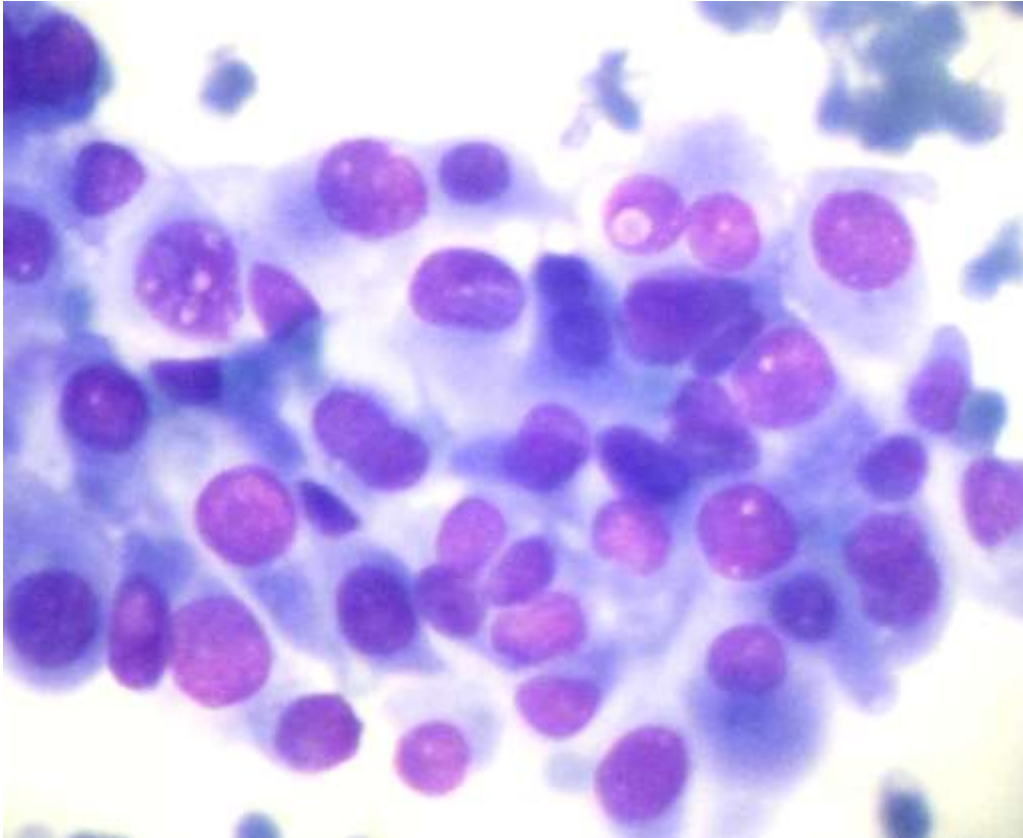
True positive[a] 43	False negative[c] 5
False positive[b] 1	True negative[d] 57

Table 6a:-

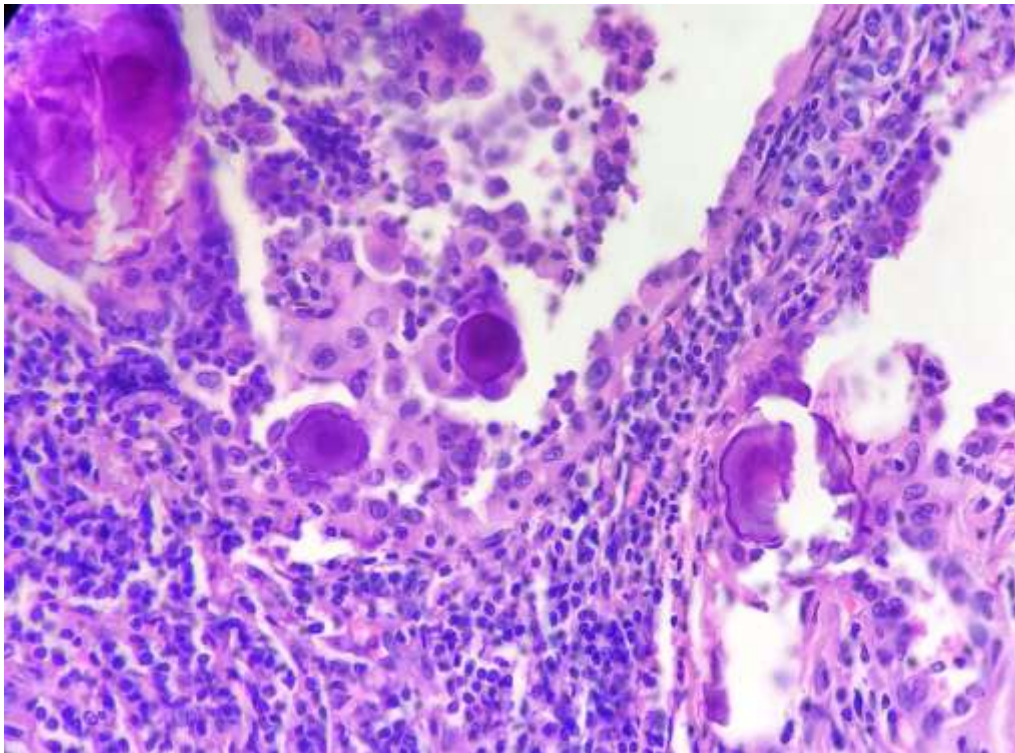
Sensitivity= $a/a+b$	$43/43+1= 97.7$
Specificity= $d/c+d$	$57/57+5= 92\%$
Ppv = $a/a+c$	$43/43+5= 89.58$
Npv = $d/b+d$	$57/57+1= 98.27\%$

Table 6 B:-

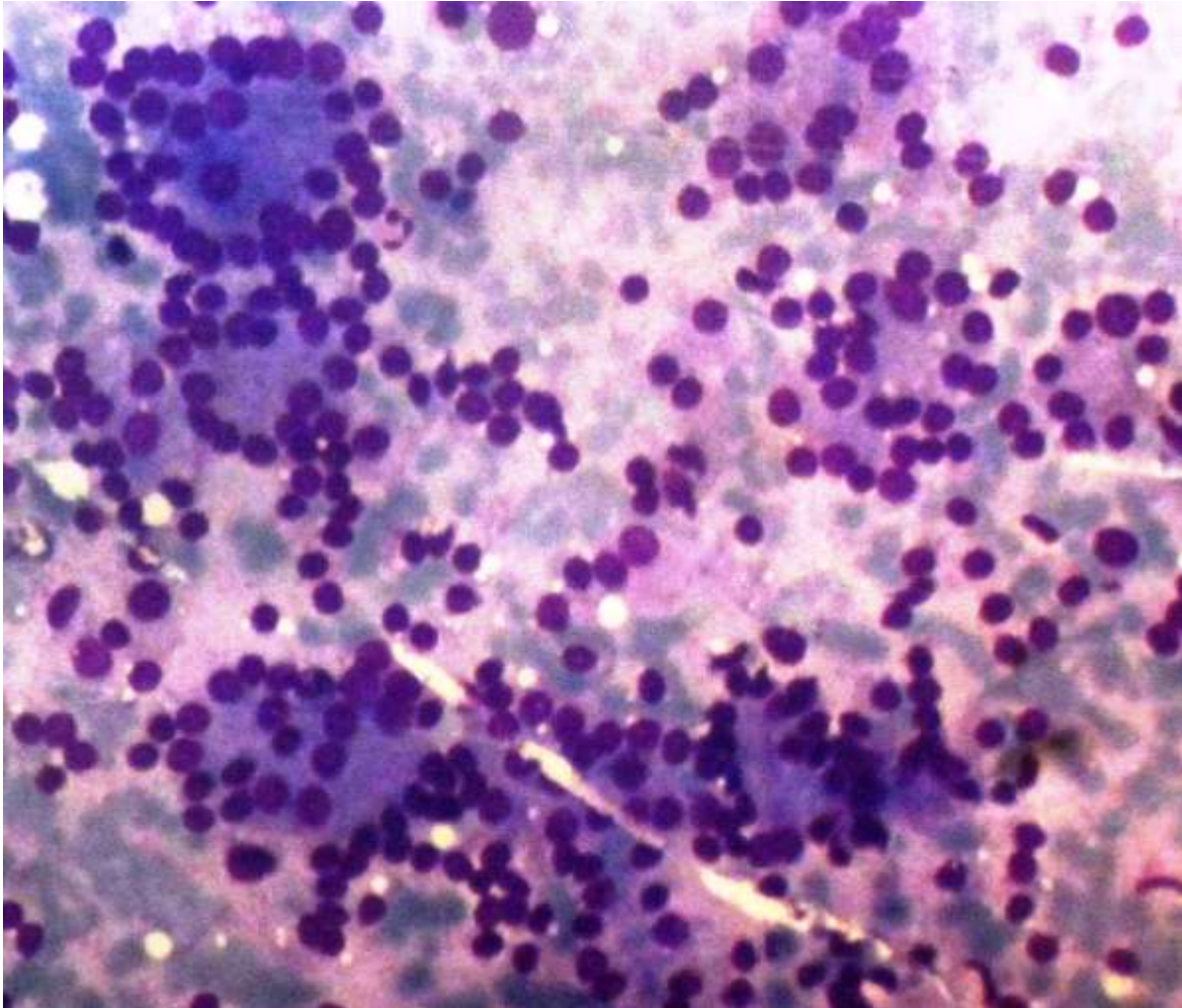
Table 6a and 6b showing sensitivity, specificity ppv and npv of usg guided fnac as compared to hpe.



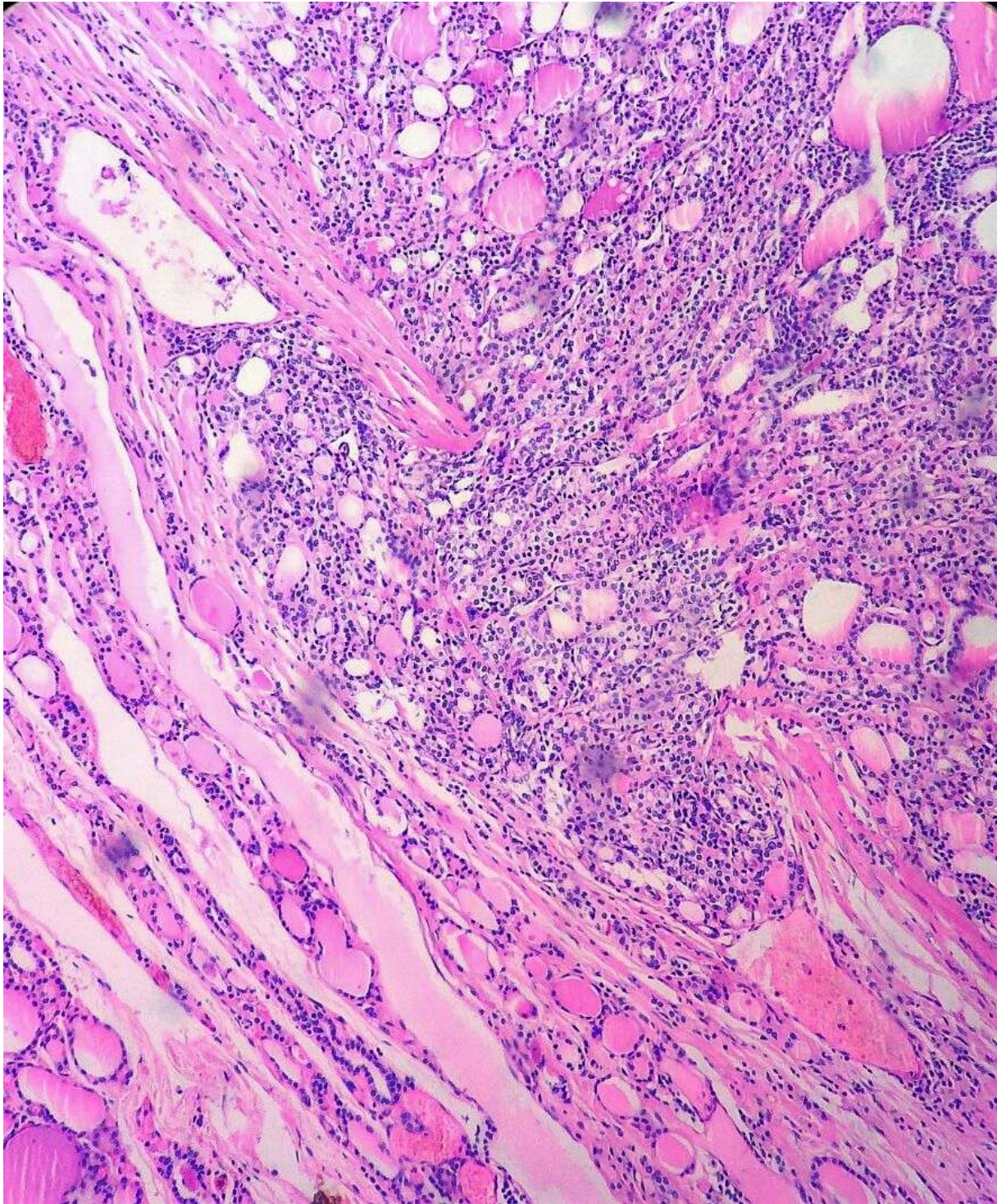
Microphotograph 1:-Blind fnac of a thyroid nodule reported as papillary carcinoma (tbsrtc category vi).



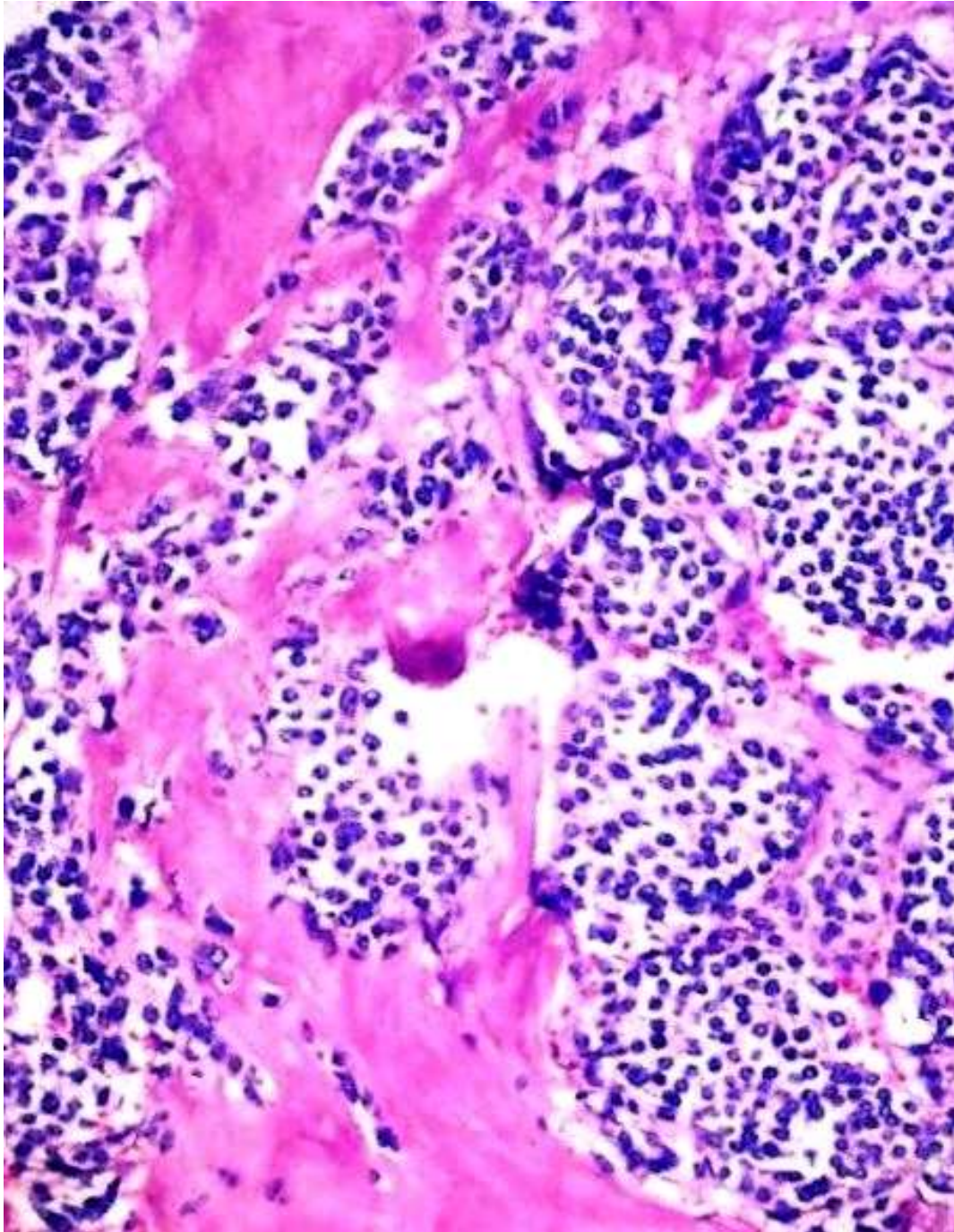
Microphotograph 2:-Hpe of the same patient after total thyroidectomy (papillary carcinoma thyroid) showing psammoma bodies.



Microphotograph 3:-Usg guided fnac repoted as follicular neoplasm (tbsrtc category iv)



Microphotograph 4:-hpe of the same patient after lobectomy showing minimally invasive follicular carcinoma.



Microphotograph 5:-hpe of patient who was reported on fnac as medullary carcinoma thyroid (tbsrtc category vi)

Conclusion:-

Although fnac has been established as the first line diagnostic test for thyroid lesions and has proven to be the most valuable modality for preoperative distinction of benign from malignant nodules and to confirm the diagnosis. However, the diagnostic yield in ultrasoundguided fnac is significantly more in terms of accuracy especially in cystic lesions and small swellings.further ultrasound guided fnac significantly helps in categorising the tbsrtc category i patients and guides there subsequent management.

Bibliography:-

1. tunbridge wm, evered dc, hall r, appleton d, brewis m, clark f, evans jg, young e, bird t & smith pa. The spectrum of thyroid disease in a community: the whickham survey. *Clinical endocrinology* 1977 7 481–493.
2. Dean ds & gharib h. Epidemiology of thyroid nodules. *Best practice and research. Clinical endocrinology and metabolism* 2008 22 901–911.
3. Mazzaferri el. Management of a solitary thyroid nodule. *New england journal of medicine* 1993 328 553–559.
4. Wang c & crapo lm. The epidemiology of thyroid disease and implications for screening. *Endocrinology and metabolism clinics of north america* 1997 26 189–218.
5. Hegedus l. Clinical practice. The thyroid nodule. *New england journal of medicine* 2004 351 1764–1771.
6. Cappelli c, castellano m, pirola i, cumetti d, agosti b, gandossi e & agabiti rosei e. The predictive value of ultrasound findings in the management of thyroid nodules. *Quarterly journal of medicine* 2007 100 29–35.
7. Iannuccilli jd, cronan jj & monchik jm. Risk for malignancy of thyroid nodules as assessed by sonographic criteria: the need for biopsy. *Journal of ultrasound in medicine* 2004 23 1455–1464.
8. Mchenry cr, huh es & machekano rn. Is nodule size an independent predictor of thyroid malignancy? *Surgery* 2008 144:1062–1068 (discussion 1068–1069).
9. Morris lf, ragavendra n & yeh mw. Evidencebased assessment of the role of ultrasonography in the management of benign thyroid nodules. *World journal of surgery* 2008 32 1253–1263.
10. Hegedus l. Thyroid ultrasound. *Endocrinology and metabolism clinics of north america* 2001 30 339–360.
11. Söderstrom n. Puncture of goiters for aspiration biopsy. A preliminary report. *Acta med scand* 1952; 144:235-244.
12. Cai xj, valiyaparambath n, nixon p, waghorn a, giles t, helliwell t. Ultrasoundguided fine needle aspiration cytology in the diagnosis and management of thyroid nodules. *Cytopathology* 2006; 17(5):251-6.
13. Gharib h, goellner jp. Fine needle aspiration biopsy of the thyroid: an appraisal. *Ann intern med* 1993; 118:282-9.
14. Bartolazzi a, gasparri a, papotti m et al. Application of an immunodiagnostic method for improving preoperative diagnosis of nodular thyroid lesions. *Lancet* 2001;357:1644-50.
15. Vidal-casariago a, lópez-gonzález l, jiménez- pérez a, ballesteros-pomar md, kyriakos g, urioste- fondo a, alvarez-san martín r, cano- rodríguez i, jiménez-garcía de la marina jm. Accuracy of ultrasound elastography in the diagnosis of thyroid cancer in a lowrisk population. *Exp clin endocrinol diabetes*. 2012; 120 (10):635-8. Doi: 10.1055/s-0032- 1323804.
16. Gharib h, papini e. Thyroid nodules: clinical importance, assessment, and treatment. *Endocrinol metab clin north am*. 2007; 36:707-35.
17. Cochand-priollet b, guillausseau pj, chagnon s,hoang c, guillausseau- scholer c, chanson p. The diagnostic value of fine-needle aspiration biopsy under ultrasonography in nonfunctional thyroid nodules: a prospective study comparing cytologic and histologic findings. *Am j med*. 1994;97:152-7. Erratum in: *am j med*. 1994;97:311.
18. Izquierdo r, arekat mr, knudson pe, kartun kf, khurana k, kort k, et al. Comparison of palpationguided versus ultrasound-guided fine-needle aspiration biopsies of thyroid nodules in an outpatient endocrinology practice. *Endocr pract*. 2006;12: 609-14.
19. Tofé povedano s, argüelles jiménez i, garcíafernández h, quevedo juanals j, díaz medina s, serra soler g, burguera gonzález b, codina marcet m, mena ribas e, urgeles planella jr, pereg macazaga v. Routine performance of thyroid ultrasound and fineneedle aspiration biopsy in the setting of a high resolution endocrinology practice. *Endocrinol nutr*. 2010; 57(2): 43-8. Doi: 20.1016/j.endonu.2009. 12.001. Epub 2010 feb 6. Spanish.pmid:20138596.
20. Zhang yx, zhang b, zhang zh, guo hq, wang y, xu zg, tang pz. *Zhonghua er bi yan hou tou jing wai ke za zhi*. Fine-needle aspiration cytology of thyroid nodules: a clinical evaluation. 2011; 46(11):892- 896. Chinese. Pmid:22335973.
21. Desai ss, sarkar s, borges am. A study of histopathologic features of medullary carcinoma of the thyroid. Cases from a single institute in india. *Indian j cancer* 2005; 42:25-29