



Journal Homepage: -www.journalijar.com
**INTERNATIONAL JOURNAL OF
 ADVANCED RESEARCH (IJAR)**

Article DOI:10.21474/IJAR01/5593
 DOI URL: <http://dx.doi.org/10.21474/IJAR01/5593>



RESEARCH ARTICLE

ONE CASE OF MANIFESTATION TROMBOTIC MICROANGIOPATHY.

Guliko Kiliptari¹ and Merab Sutidze².

1. Head of Department of critical care. The First University Clinic, MD, PhD. Prof.of TSMU (Tbilisi, Georgia).
2. Head of Department Nefrology. Prof.

Manuscript Info

Manuscript History

Received: 11 August 2017
 Final Accepted: 13 September 2017
 Published: October 2017

Key words:-

HUS,renal replacement
 therapy,coma,vena cava thrombosis.

Abstract

Purpose: Presentation of one case of HUS. Shiga-like toxin producing *E coli* hemolytic-uremic syndrome (STEC-HUS) is a disorder that most often occurs when an infection in the digestive system produces toxic substances. These substances destroy red blood cells and cause kidney injury. Hemolytic-uremic syndrome (HUS) often occurs after a gastrointestinal infection with *E .coli* bacteria (*Escherichia coli* O157:H7). However, the condition has also been linked to other gastrointestinal infections andnongastrointestinal infections. atypical HUS(aHUS)is not infection-related. It is similar to another disease called thrombotic thrombocytopenic purpura TTP/TMA(tromboticmicroangiopathy)and is related to other diseases,lik lupus erythematosus ,antiphospholipidsyndrome.Haemolytic-uraemic syndrome (HUS) and thrombotic thrombocytopenic purpura (TTP) are two clinically similar disorders characterized by severe microangiopathic haemolytic anaemia and thrombocytopenia. Thus, the two disorders are often difficult to distinguish.

We presented case discussion of 32 old women with bloody diarrhea,oligoanuria and changes of awareness.

Results: Increased level of LDH,creatinine, urea. Decreased level of ADAMTS 13. Anisocytosis, shisocytosis ,poikilocytosis .Renal biopsy revield global sclerotic changes, In CSF was found HSV1 virus, After treatment patient state was improved .motor and sensoric activation was increased. Spontan breathing parameters improoved. Later Patient state was worsened despite of suitable treatment developed pulmonary embolizm and inferior vena cava embolizm .

Conclusion: In patients with HUS , the fraquency of mortality is high, clinical manifestation also is nontypical.Adequite estimations of clinical signs in premorbid period and examination of organ function after hospitalization,prevention and management of complications gives a real chance of convalescence

Copy Right, IJAR, 2017,. All rights reserved.

Corresponding Author:-Guliko Kiliptari.

Address:-Head of Department of critical care. The First University Clinic, MD, PhD. Prof.of TSMU (Tbilisi, Georgia).

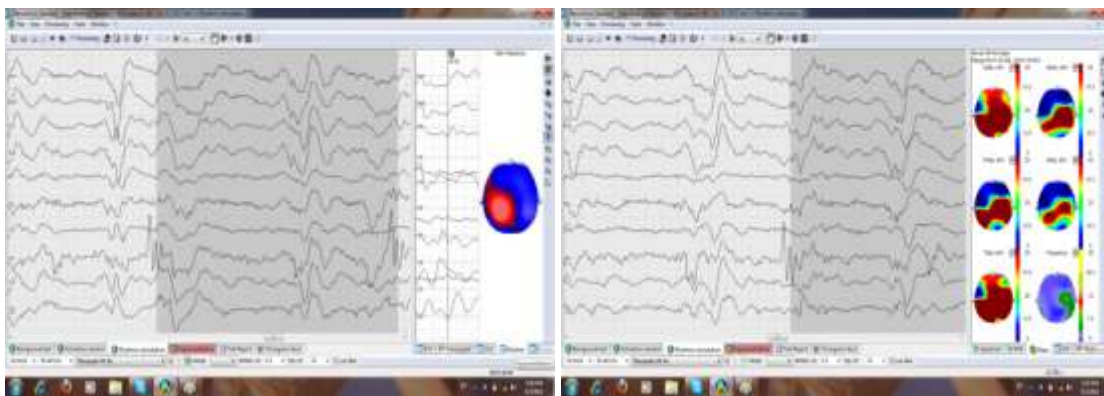
Introduction:-

HUS /TTP(thrombotic microangiopathy) is syndroms ,characterized with microangiopathic hemolytic anemia , trombocytopenia , acute renal falure ,severe neurological violations .Bloody diarrhea is caused with E.Coli(0157:H7).In georgia revealed other strain –E.coli(0104:H4). changing(coma , seizures.).Atypical HUS(aHUS) is not infection-related. It is similar to another disease called thrombotic thrombocytopenic purpura(TTP).haemolytic-uraemic syndrome (HUS) and thrombotic thrombocytopenic purpura (TTP) are two clinically similar disorders characterized by severe microangiopathic haemolytic anaemia and thrombocytopenia. Thus, the two disorders are often difficult to distinguish.

ADAMTS13 levels < 10% with the presence of antibody against ADAMTS13 is characteristic of most adults with TTP and these patients respond to plasma exchange. Testing for ADAMTS13 activity ,deficit or decreaseion of activity of H Factor is appropriate in patients with suspected TTP-HUS. The combination of clinical and laboratory data, activity of ADAMTS13, and response to plasma exchange allows for better differentiation between these thrombotic microangiopathies, which itself is very important considering that both have different treatment options. Thrombotic microangiopathies are diseases characterized by thrombocytopenia , erythrocyte fragmentation, and elevated levels of LDH. Thickening of the arterioles and capillary walls with prominent endothelial swelling and detachment and subendothelial accumulation of proteins and cell debris characterize and define the pathologic lesion seen in all thrombotic microangiopathies .. Patient admitted in hospital after one weak from onset of clinical simptoms. Regardless of bacteriological investigations of feces , the microb does not revealed.Progress of disease was severe,with many complication:renal failure with severest neurological violations. We prented case when illness started with bloody diarrhea, oliguria and neurological changing(coma , seizures). Illness progress was severe with many complication.

Discussing:-

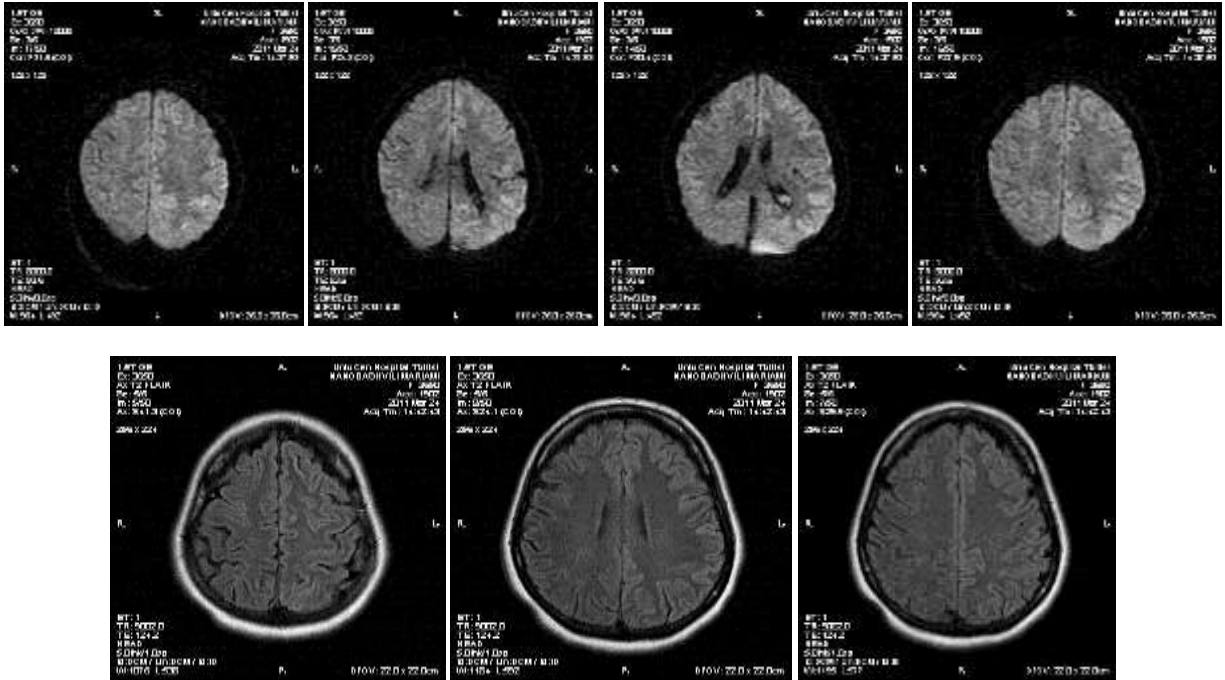
32 yarsold women was admitted in ICU with oligoanuria,chills. Diseases started with diarrhea,vomiting, abdominal pain ,oliguria ,fever .Changes of awareness revealed after generelaized seizures. Patient was intubated and started artificial ventilation. Brain CT scan revealed ventriculs dilatation ,Without dislocation of midline structures. After episodes of focal seizures treatment was started with carbamazepin(400mg per day).OnEEG revealed generelaized ,spike slow wave activity (pict.1)



Pict.1:- EEG

MRI detected (Flair mode)—cortex damage of left temporal –occipital area(pict2),

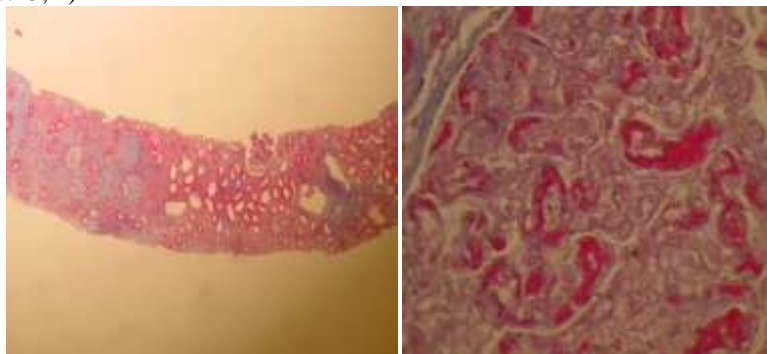
Lumbar aspirate—protein—0.48g/l,leicocytes—7/mm³,limph—68%,neutrophils—32%.In lumbarasprate was detected HSV 1 vires. After treatment with aciclovir and repeated investigation of lumbar aspirate , HSV 1 vires was not found .Antibacterial treatment was based on bacteriological investigations and suitable antibacterial therapy.



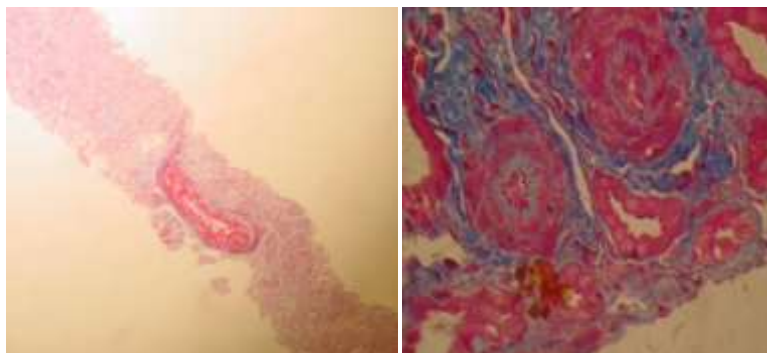
pict.2:-BBrain MRI

At first creatinine , LDH and urea level was high(6.72mg/dl.198 mg/dl,3916 u/l).

After renal biopsy was found 20 glomerulus,in 9 glomerulus was discovered necrotic changing(focal cortical necrosis) ,in 5 glomerulus ---complex replication of basement membrane and enlargement of mesangial matrix(pict 3,4)

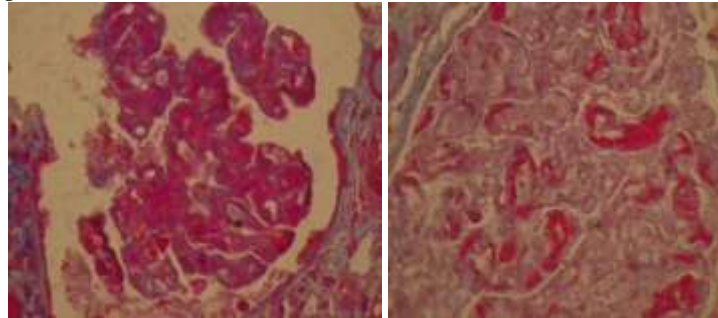


Pict.3:-Renal biopsy material



Ppict.4:-Renal biopsy material

In preglomerular arterioles revealed fibrosis of intima, thrombus into lumen and arterial-arterioles sclerosis. 35% of tubules was necrosed (focal cortical necrosis), remaining part was atrophic with thickening of basament membrane.(pict 5)



Pict. 5:- Renal biopsy material

In arterial wals and focal glomerulus was found fibrin/ fibrinogen deposits (pict 3,4,5).ADAMTS-13 activity was normal -64.9%(N40-130),ADAMTS -13 antigen was 0.46u/ml,slightlydecreased,and antibody was not found.ADAMTS inhibitor -3.5 u/ml(N<12u/l)

At first platelets count was decreased-80000/mm³,then platelets count returned to normal value.Immunity parameters was normal(schedule1)

CD3 lymphocytes-65%	IgG 14.3g/l(N8-18)
CD4 lymphocytes-45%(N29-57)	IgA 3.4g/l(N 0.9-2.5)
CD4-abs.number-1431(N404-1612)	IgM-0.2g/l(N0.6-2.8)
CD8lymphocytes-20%(N11-38)	IgE-9.19 g/l (N<200)

Sched.1 Immunological tests

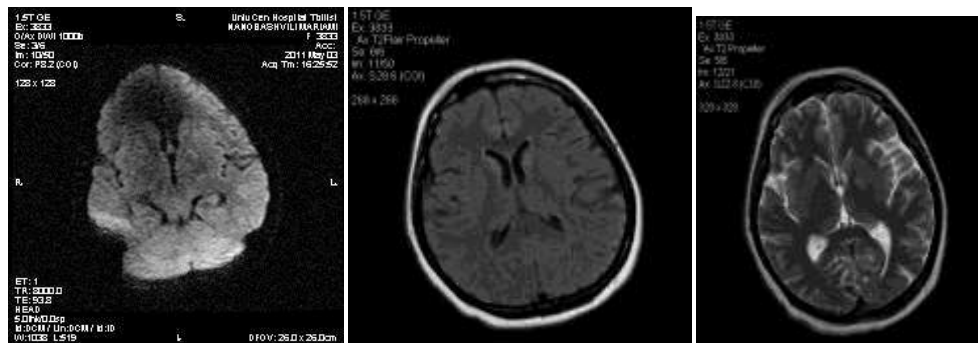
Antinuclear antibody was not found .In peripheral blood revealed leucocytosis: white blood cell count--41000/mm³,anisocytosis,shisocytosis ,poikilocytosis,Neutrophils count 31.4mg/d l

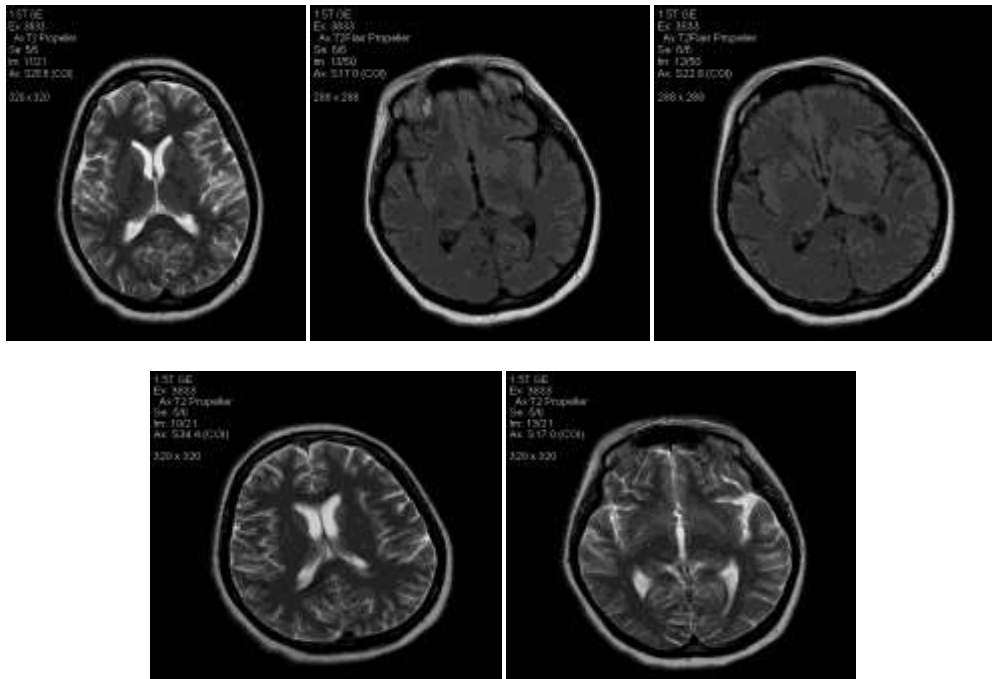
Secondary coagulation hemostasis was changed : decreased antithrombin III, increased soluble fibrin-monomer complex(sched.2)

FDP --21mg%	AT-III----70%
D-dimer 9000 ng/ml(<500ng/ml)	

Shed.2 Tests of coagulation hemostasis

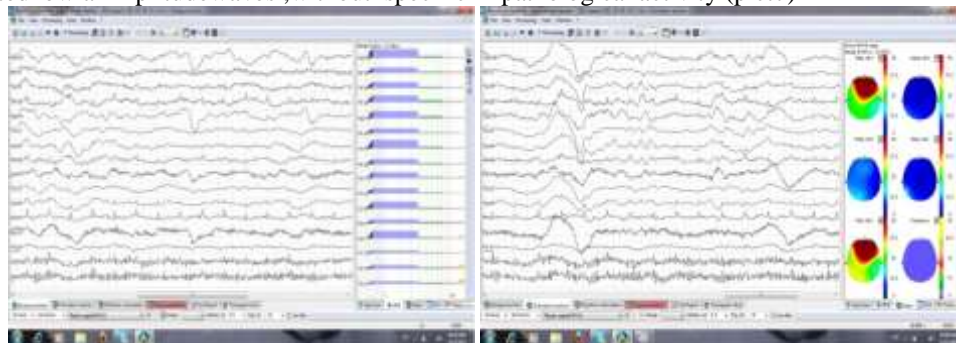
Chest Ct scan ---detected pneumonia,abdominal CT scan---fluid accumulation .Brain MRI-detected (T2,Flair) ischemic damage in left subcortical nodes(pict6).





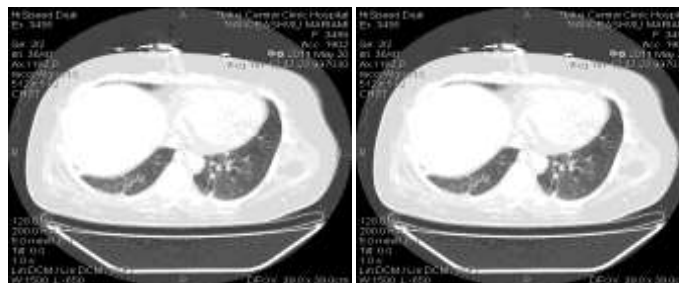
Pict6:- Brain MRI

EEG—detected low amplitudewaves ,without specific pathological activity (pict7)



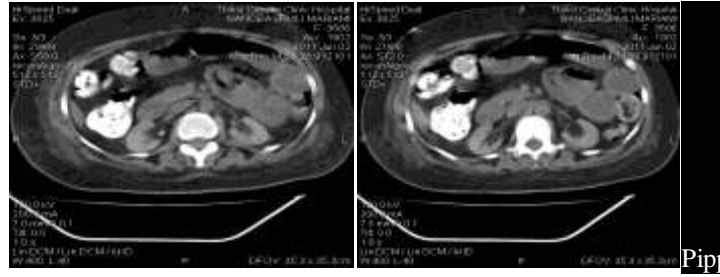
Pict 7:- EEG

After 35 day from hospitalization neurological state improved, awareness was adequate,without cognitive violations.lasted renal replacement therapy . Chest Ct scan (pict8) detected impruiment of lung radiological findings.



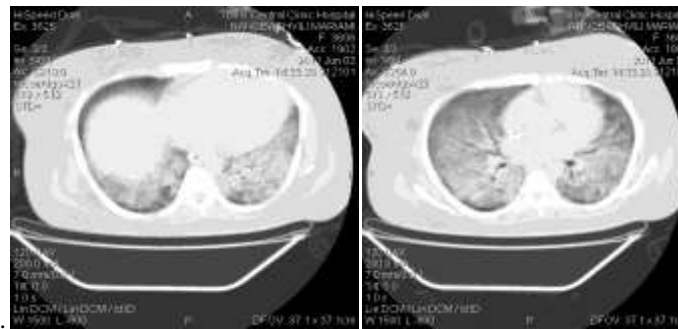
Pict 8:- Chest CT scan

Patient was extubated ,parameters of spontaneous breathing was normal . After one weak revealed abdominal distension,vomiting .Abdomen CT scan and angiography was found bowel distension, dynamic obstruction and excluded mezenteric thrombosis. (pict 9)



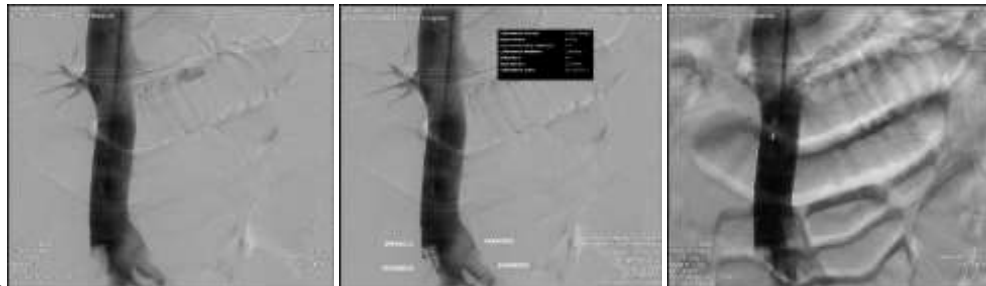
Pict9:- Abdomen CT scan

Later patient state was aggravated , developed acute respiratory failure .Chest CT scan detected bilateral pneumonia.(pict 10)



Pict10:- Chest CT scan

Low extremity vessels ultrasonography revealed thrombus in common femoral ,deep femoral vein .Despite suitable treatment ,ventilation parametres worsened.Echocardiography revealed dilation of right chambers ,increased PASP(65mm.hg).Low extremity vessels ultrasonography revealed thrombus in left external iliac and great saphenous vein.After cavagrapy in vena cava bifurcation area detected filling defects- thrombus -- 8.2X16.8. and 6.7X 20.8 (pict 11).In infrarenal part of inferior vena cava was performed placement of vena cava filter(Vena TeechLP,B.Braun Medical).



Pict 11:-Cavagrapy. Placement of filter

Regardless of suitable treatment developed severe obstructive shock .

Discussing:-

disease started with bloody diarrhea, vomiting ,after 7 day from onset patient was admitted in hospital . Identification of microb was not possible with Feces bacteriological analysis .D iagnosis was based on results of renal biopsy and morphological researches,laboratory and clinical parameters .unconsciousness and right side hemiparesis revealed after seizures .MRI detected left side subcortical nodes ischemic damage.In lumbar aspirate by PCR method detected vires (HSV1).Patient was treated with antiviral drugs (ZOVIRAX),For treatment of sepsis was identified source of infection(pneumonia,VAP) , antibacterial treatment started empirically and considering bacteriological analysis .LDH level was high, Haptoglobin level was decreased ,what referred to microangipathic hemolysis .In peripheral blood smear revealed red blood cells fragmentation ,reduction of platelet count .D dimer and FDP level was increased . after renal biopsy,in arterial

wall and in glomerulus was found fibrin/fibrinogen deposits. Reason of renal failure was thrombotic microangiopathy, activation of platelets after endothelium damage and activation of coagulation hemostasis. In several glomerulus detected 35% necrosed tubules and remaining part of tubules was atrophic. Patient was treated with renal replacement therapy, plasma exchange therapy. Causes of coma was thrombotic microangiopathy, with accompanying reasons. Regardless of suitable treatment developed DVT, pulmonary embolism, low vena cava thrombosis.

Establishing the diagnosis of TTP or HUS was a 2-step process: verifying the presence of triad of microangiopathic hemolytic anemia and thrombocytopenia, excluding systemic/secondary conditions that would cause these changes. Among other causes, disseminated intravascular coagulation could also cause microangiopathic hemolytic anemia and thrombocytopenia, but it was distinguished by laboratory results.

Conclusion:-

We have discussed the case, when the disease started with bloody diarrhea, vomiting. By fecal bacteriological analysis microbes have not been identified. Unconsciousness manifested after hospitalization with generalized seizures. MRI revealed temporal and parietal cortex damage, later left ischemic damage of left subcortical nodes, what probably was the reason of seizures. LDH level was high in early stage, haptoglobin level was low what referred microangiopathic haemolysis. In the smears of peripheral blood was observed erythrocyte fragmentation. Platelets counts was mildly decreased. Reduction in activity or absence of ADAMTS13 was not observed. In lumbar aspirate revealed virus (HSV1), but MRI scan can not fix the changes, specific for encephalitis. FDP increased (D dimer also increased). Therefore genesis of renal failure and coma was thrombotic microangiopathy and other accompanying causes. The manifestation of this syndrome sometimes is atypical. The frequency of mortality is high, clinical manifestation also is nontypical. Adequate estimations of clinical signs in premonitory period and examination of organ function after hospitalization, prevention and management of complications gives a real chance of convalescence.

References:-

- Interventions for hemolytic-uremic syndrome and thrombotic-thrombocytopenic purpura, a systematic review of randomized controlled trials. Michael EM - *Am J Kidney Dis* 01-Feb-2009;53(2):259-72
- Thrombotic thrombocytopenic purpura-hemolytic-uremic syndrome and adult onset Still's disease: case report and review of the literature - Sayarioglu M - *Mod Rheumatol* 01-Jan-2008,18(4):403-6
- Is there a shared pathophysiology for TTP and HUS? - Desch K - *J Am Soc Nephrol* 01-Sep-2007;18(9):2457-60
- Therapeutic plasma exchange in patients with TTP-HUS: the 10 year experience of a single center. Kirn - *Hematology* 01-MAR-2011;16(2):73-9
- Platelet count and prothrombin time help distinguish thrombotic thrombocytopenic purpura-hemolytic uremic syndrome from DIC in adults. PARK IA - *Am J Clin Pathol* 01-MAR-2010;133(3):460-5
- Inherited ADAMTS13 deficiency-unique presentation and treatment. - Born H - *Pediatr Blood Cancer* 01-MAY-2008;50(5):956-7
- Atypical hemolytic uremic syndrome - Kavanagh D - *Curropin hematol* 01-Sep-2010;15(5):432-8
- Rituximab therapy in two children with autoimmune thrombotic thrombocytopenic purpura - Albavamki JH - *Pediatr Nephrol* 01-SEP-2009;24(9):1749-52
- Treating TTP-HUS with plasma exchange: a single centre, 25 year experience - Forzley BR - *J Haematol* 01-Oct-2008;143(1):100-6
- Thrombotic microangiopathy (TTP and HUS): advances in differentiation and diagnosis. Schneide M - *Clin Lab Sci* 01-Oct-2007;20(4):216-20
- Elevated procalcitonin and C reactive protein as potential biomarkers of Sepsis in subpopulation of thrombotic microangiopathy patients. Erickson YO - *J Clin Pathol* 01-Jan-2009;24(4):150-4
- HUS-TTP update: 2008. Clark WF - *Kidney Int Suppl* 01-Feb-2009(112):91-3
- Atypical Hemolytic-Uremic Syndrome: A Case Report and Literature Review
- Arsalan Rafiq^{A,B,C,D,E,F} Hassan Tariq^{A,B,C,E,F} Naem Abbas^{E,F} and Roopalekha Shenoy^{A,E}, *Am J Case Rep*. 2015; 16: 109-114. Published online 2015 Feb 24. doi: 10.12659/AJCR.8929072
- Anti-Factor H Autoantibody-Associated Hemolytic Uremic Syndrome: Review of Literature of the Autoimmune Form of HUS. Marie-Agnes Dragon-Durey, Caroline Blanc, *Nature reviews Nephrology* 8,622-633, November 2012, doi:10.1038/neph. 2012.

16. Platelet count and prothrombin time help distinguish thrombotic thrombocytopenic purpura-hemolytic uremic syndrome from DIC in adults. *PARK IA-AM j Clin Pathol*-01-MAR-2010;133(3):460-5
17. Therapeutic plasma exchange in patients with TTP-HUS :the 10 year experience of a single center. *Kirn - Hematology* -01-MAR-2011;16(2):73-9
18. Atypical hemolytic uremic syndrome and thrombotic thrombocytopenic purpura: clinically differentiating the thrombotic microangiopathies. Nester CM, Thomas CP. *Eur J Intern Med.* 2013;24(6):486–91. [PubMed]
19. Diagnostic criteria for atypical hemolytic uremic syndrome proposed by the Joint Committee of the Japanese Society of Nephrology and the Japan Pediatric Society. *ClinExpNephrol.* 2014;18(1):4–9. [PubMed]
20. Neurological involvement in children with E. coli O104:H4-induced hemolytic uremic syndrome. *Bauer A, Loos S, Wehrmann C, et al. PediatrNephrol* 2014; 29:1607.
21. Thrombotic microangiopathy(TTP and HUS):advances in differentiation and diagnosis. *Schneide M-Clin Lab SCI-oi-oct-2007;20(4):216-20*
22. Interventions for hemolytic-uremic syndrome and thrombotic-thrombocytopenic purpura,a systematic review of randomized controlled trials. *Michaellem-AM j Kidney dis*-01-Feb-2009;53(2):259-72
23. A Case Report and Literature Review of Eculizumab Withdrawal in Atypical Hemolytic Uremic Syndrome. *Borja Quiroga ,Alberto de Lorenzo ,Cristina Vega ,Fernando de Alvaro, Am J Case Rep,* 2016; 17: 950-956
24. Acute neurological involvement in diarrhea-associated hemolytic uremic syndrome. *Nathanson S, Kwon T, Elmaleh M, et al. Clin J Am SocNephrol* 2010; 5:1218.
25. Atypical hemolytic uremic syndrome-Kavanagh D-*Curropin hematol*-01-Sep-2010;15(5):432-8