



Journal Homepage: - [www.journalijar.com](http://www.journalijar.com)  
**INTERNATIONAL JOURNAL OF  
 ADVANCED RESEARCH (IJAR)**

Article DOI: 10.21474/IJAR01/6019  
 DOI URL: <http://dx.doi.org/10.21474/IJAR01/6019>



### RESEARCH ARTICLE

#### ONE CASE OF REFRACTORY STATUS EPILEPTICUS AND AUTOIMMUNE ENCEPHALITIS.

Guliko Kiliptari<sup>1</sup> and Ia Rukhadze<sup>2</sup>.

1. Head of Department of critical care., university central clinic after acad. N. Kipshidze ,MD, PhD. Prof.of TSMU (Tbilisi, Georgia).
2. Neurologist, Md, PHD (Tbilisi, Georgia).

#### Manuscript Info

##### Manuscript History

Received: 10 October 2017  
 Final Accepted: 12 November 2017  
 Published: December 2017

#### Abstract

**Purpose:** Encephalitis is a severe inflammatory disorder of the brain with many possible causes and with difficult differentiate of diagnosis. Existing criteria for autoimmune encephalitis are too reliant on antibody testing and response to immunotherapy, which might delay the diagnosis. Several particular features raise the suspicion of an autoimmune cause in otherwise unexplained seizure disorders. One of the most important challenges is the elucidation of the causes of seizure disorders.

We presented one case of unexplained coma and refractory status epilepticus. Patient, 20 yrs old.men, was admitted in hospital with coma , stable hemodynamics, on mechanical ventilation. On MRI research was discovered existence of inflammatory infiltration.At primery stage , EEG- discovered polymorphic dysrhythmia,bilateral activity,than plural peak shurp-slow wave paroxysms and status epilepticus. It was conducted combined treatment with anticonvulsive drugs ,Immunoglobulin, pulse corticosteroid therapy with methylprednisolone and plazma exchange therapy.

**Conclusion:** An autoimmune cause was suspected based on frequent or medically intractable seizures and the presence of neural antibody, inflammatory changes indicated in spinal fluid and on MRI. Patients had abnormal findings on brain MRI, with extensive multifocal or diffuse cortical and subcortical involvement. EEG showed generalized periodic discharges and status epilepticus . within investigation of IgG autoantibodies against proteins on the surfaces of neurons, we received difference result from two different laboratory,but refractory status epilepticus,radiological changes ,EEG pattern and progress of illness has indicated autoimmune character of process.

Copy Right, IJAR, 2017,. All rights reserved.

#### Introduction:-

Encephalitis is a severe inflammatory disorder of the brain with many possible causes and with difficult differentiate of diagnosis. existing criteria for autoimmune encephalitis are too reliant on antibody testing and response to immunotherapy, which might delay the diagnosis.

**Corresponding Author:- Guliko Kiliptari.**

Address:- Head of Department of critical care. The First University Clinic, MD, PhD. Prof.of TSMU (Tbilisi, Georgia).

Several particular features raise the suspicion of an autoimmune cause in otherwise unexplained seizure disorders.

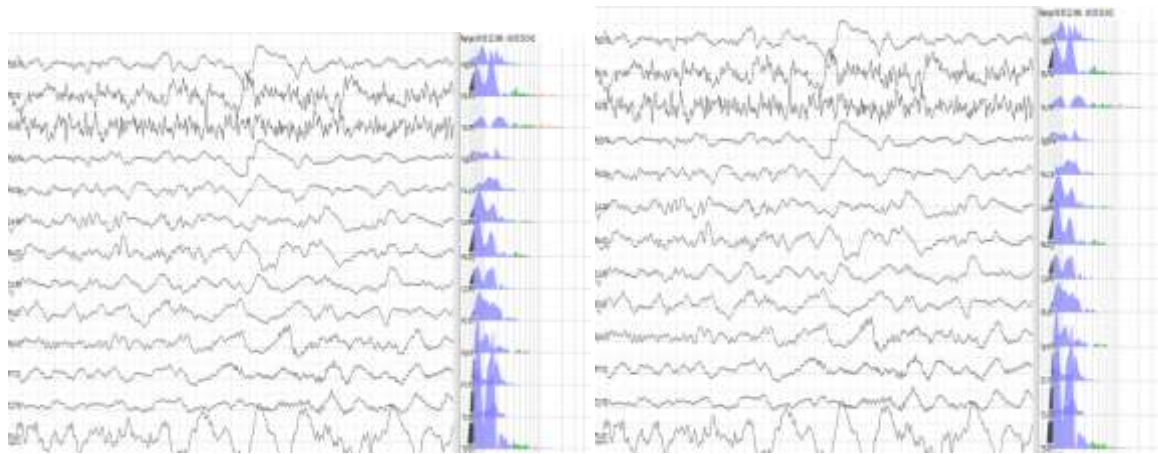
One of the most important challenges is the elucidation of the causes of seizure disorders. IgG autoantibodies against proteins on the surfaces of neurons were identified as markers and pathogens in autoimmune encephalitides that are accompanied by repetitive focal seizures. The antibodies against surface antigens contribute directly to the disease processes. In particular Anti-NMDA receptor encephalitis is a disease occurring when antibodies produced by the body's own immune system attack NMDA receptors in the brain. In the absence of a reliable biomarker, it is difficult to gain systematic and general insights into these patients.

Because autoantibody test results and response to therapy are not available at disease onset, treatment is based on the initial diagnostic approach on neurological assessment and conventional tests that are accessible to most clinicians.

We presented one case of unexplained coma and refractory status epilepticus.

#### Case report:-

Patient, 20 years old, male, Caucasian was admitted in hospital at 06.07.2017. with coma, stable hemodynamics, on mechanical ventilation (patient was transferred from another clinic) CT of brain could not discover any pathological changes. MRI within admission (07.07.2017) was without acute pathological intracerebral changes, EEG- discovered polymorphic dysrhythmia, bilateral activity (Fig.1).



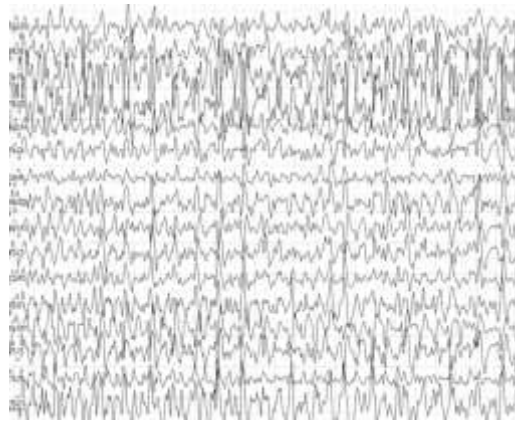
**Fig 1:-** The patient was examined on viruses, parasites, bacteria.

Borrelia burgdorferi	IgM -30u/ml, IgG-negative.
Mycobacterium tuberculosis	PCR in CSF -- negative.
Cryptococcus Ag quantitative analysis	negative.
Brucella	IgM -10lu/ml, IgG - negative
Leptospira	IgM, IgG -negative
Blood test of gamma interferon (ESAT-6, CFP-10, TB7.7)	negative
Measles IgG ab - 9600IU/L	N>350, immunity confirmed
Measles-Virus - Ak. IgM negative	Normal range -negative
Tick borne encephalitis virus	(NORM 0.8-1.1)
0.7 Ig M Ig G 0.1	

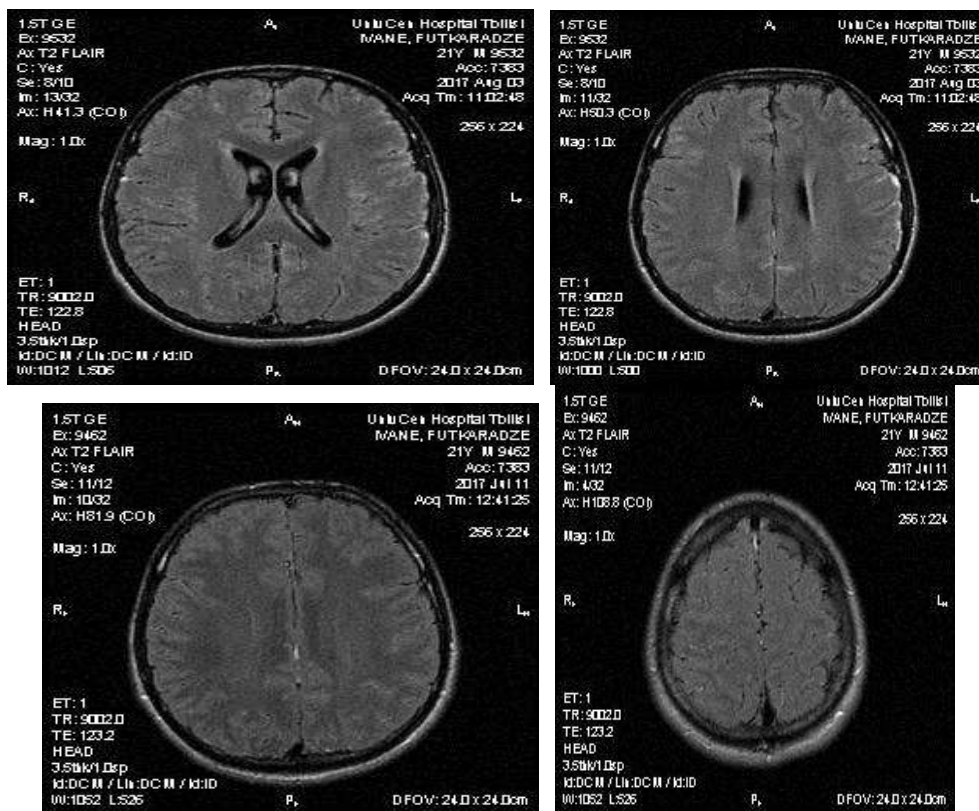
Patient CSF and serum was examined on autoantibodies against proteins on the surfaces of neurons, in particular for diagnosing of NMDA receptor antibody encephalitis. CSF was sent to the lab at 7.07.17.

Treatment was started empirical, with antiviral (Acyclovir) and antibacterial drugs. After 6 days from the beginning of investigation, autoantibody test result was positive NMDAR AAB in CSF was 1:2, in serum 1:160. (serum and CSF was investigated in Heidelberg laboratory of Limbach)

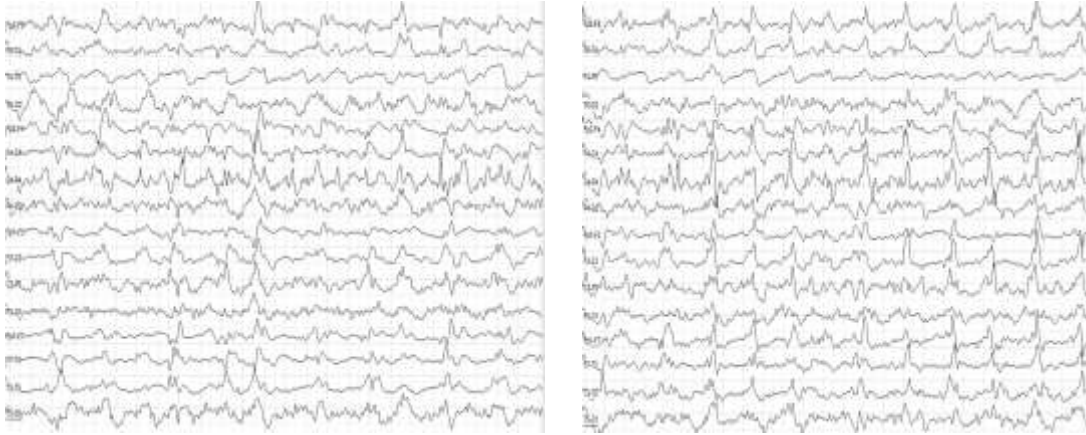
After 4 days EEG revealed status epilepticus (Fig.2)



**Fig.2:-** On Repeated MRI research (1.07.17) was discovered existence of inflammatory infiltration (encephalitis) in right frontal and parietal lobes and around of hippocampus, intracranial arteriovenous hyperemia.(Fig.3).



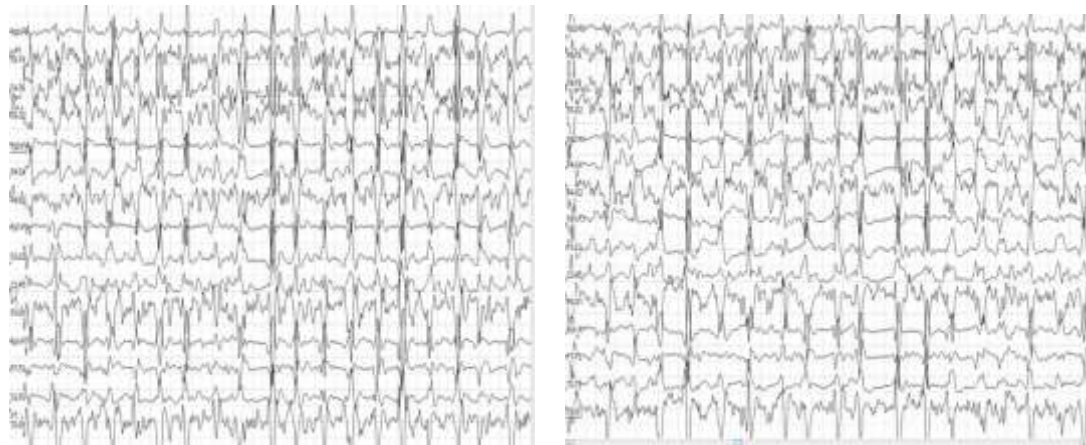
**Fig.3:-** For status epilepticus was initiated treatment with valproic acid (Depakin), Levetiracetam (Epixx) and carbamazepin. Regardless of this drugs EEG at 17.07 revealed plural Peak sharp-slow wave paroxysms (Fig.4)



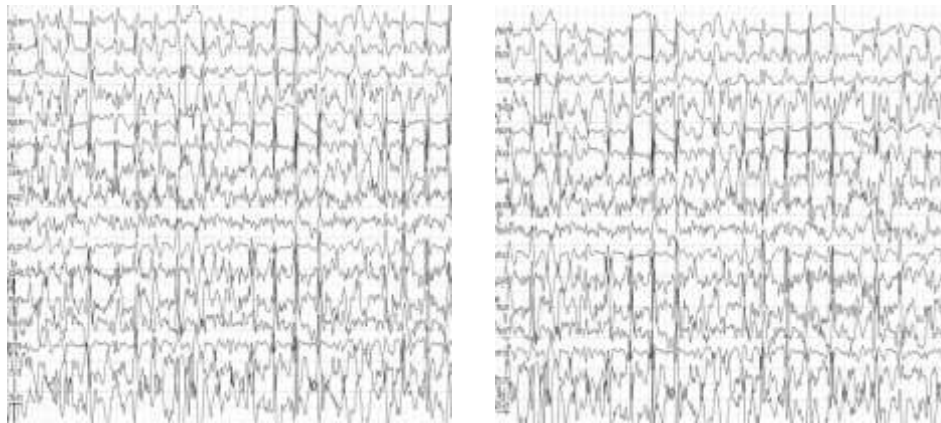
**Fig.4:-** After detection of NMDAR AAB in CSF, was started immunoglobulin therapy(0.4g/kg/day for 5 day). Treatment was lasted with peroral intake of Epixx and Depakin, intravenous infusion of levetiracetam (Keppra), Valproate sodium(Depakin) and intravenous infusion of propofol (4mg/kg/day), pulse corticosteroid therapy with methylprednisolone. Propofol infusion rate and maximum dosage was selected by considering to avoid of propofol infusion syndrome. We periodically were testing the concentration of anti-conventional drugs in the blood and the dosage was adjusted accordingly.

Additionally was used thiopental infusion and ketamin infusion with dosage 2.75mg/kg.h(3 day), But the convulsion on EEG was continued.

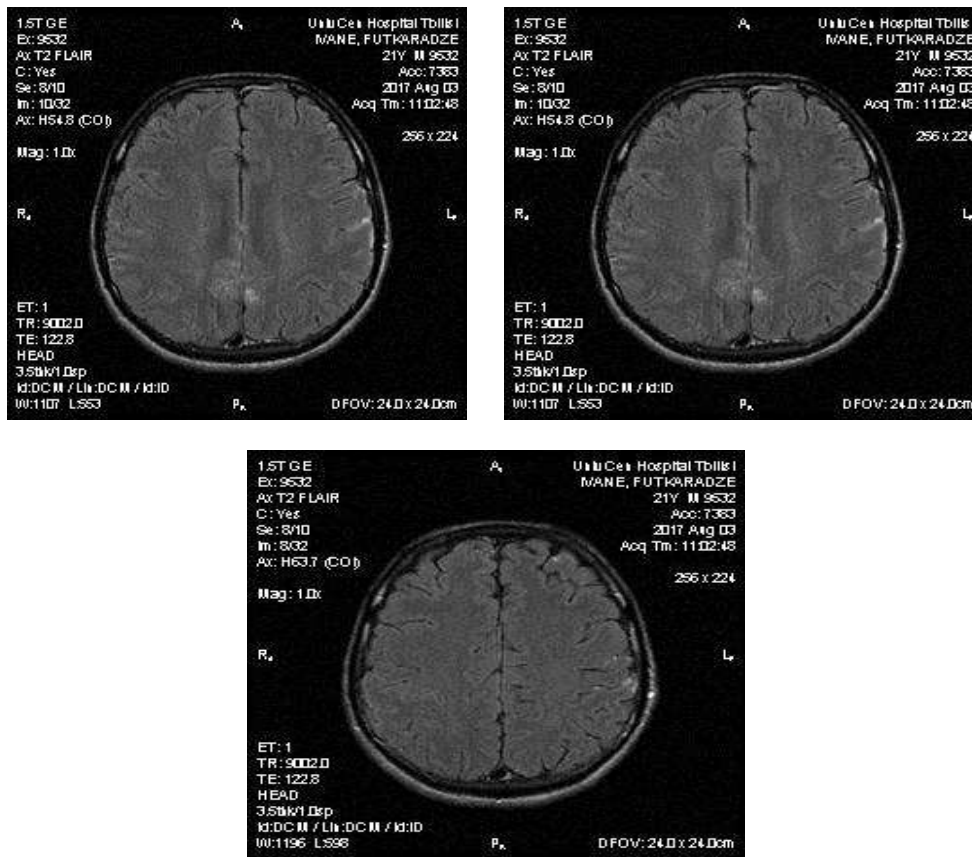
Epi pattern(27.07.17) had negative dynamics, increased amplitude of epileptic form activities(Fig. 5)



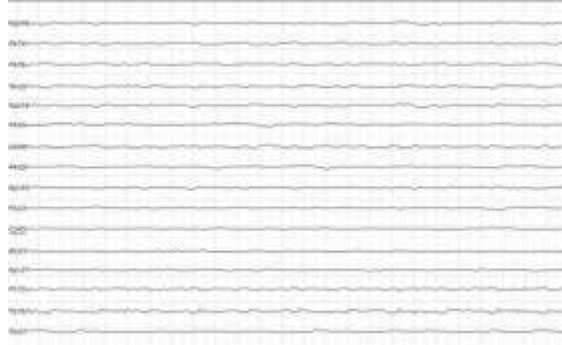
**Fig.5:-** Plasma exchange (PE) was used as one of the treatment modalities in addition to immunosuppressive therapy, including corticosteroids, intravenous immunoglobulin (IVIG). Regardless of such combined and multilateral treatment, EEG (31.07.17) detected negative electrophysiological dynamics (Fig.6), MRI revealed negative radiologic changings(Fig.6)



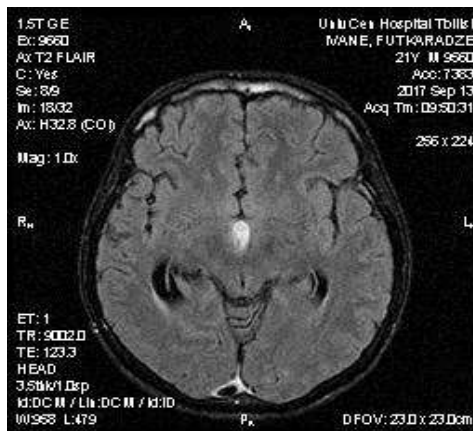
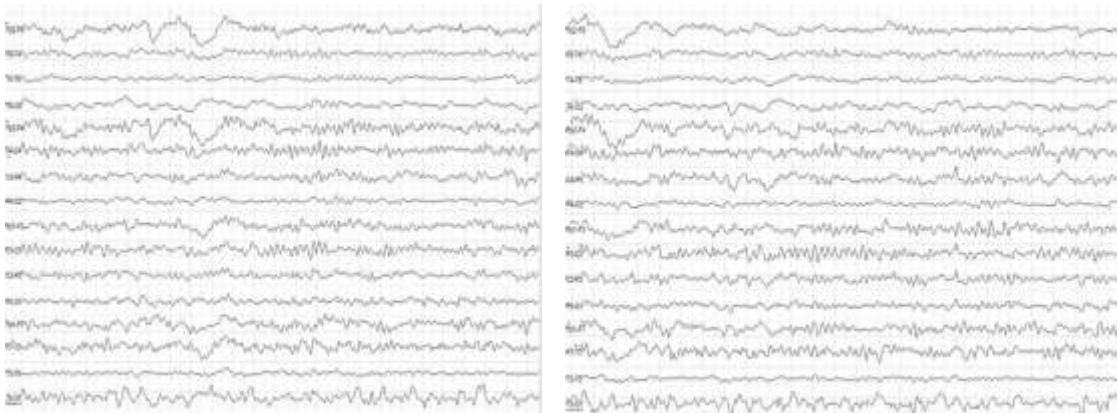
**Fig.6:-**In large hemispheres, hyperintensiveness of subarachnoid spaces was reduced. However after contrasting, the focal point of contrast substance was much more manifested in parahippocampus and fragmentately in the area of the membranes (more left).



**Fig.7:-**For maximal captured and decrease of brain bioactivity was used thiopental with high dose infusion. We achieved absolute decrease of brain bioactivity and full resolution of convulsion(8.08.17)



After 48 h.from cessation of thiopental infusion ,we received normal EEG and later improvement of MRI parameters. Fig.8



**Fig.8:-** Patient CSF and serum we were sent to The Austrian Clinical Institute of Neurology.

a) This institute investigated serum and cerebrospinal fluid of our patient for presence of anti-neuronal antibodies.

b) In this laboratory screening for surface receptor antibodies (avidin-biotin-peroxidase technique; rat brain; IIFT Euroimmun) was negative for antibodies such as NMDAR, LGI1, CASPR2, AMPAR, GABA(B)R, and DPPX. A cell-based assay was negative for glycine-receptor antibodies (in-house; GlyR alpha1).

Institute has noticed that negative test result does not exclude autoimmune logically mediated syndromes of other origin.

Later, after 36 days from admission, the patient's state has become stable, the patient was weaned from artificial ventilation. The level of consciousness has been gradually improved and finally the patient has been discharged from hospital.

### Discussing:-

We presented drug-resistant status epilepticus that persisted following the continuous administration of intravenous anesthetics and anticonvulsive drugs for more than several days.

Acute onset, resistance to anti-seizure medication, evidence of CNS inflammation were clinical features suggestive of autoimmune epilepsy.

For treatment, we used first-line therapies—steroids, intravenous immune globulin, plasma exchange therapy, combinations of these interventions. Anticonvulsive drugs, valproate sodium, levetiracetam, midazolam, propofol infusion, and some drugs (carbamazepin, depakin, epixx) taken from the gastrointestinal route, were not effective.

Many researchers have reported that, during prolonged seizures, the number of activated GABA-A receptors on the postsynaptic membrane gradually decreases, whereas the number of inactive GABA-A receptors increases. These changes cause a significant reduction in the efficacy of antiepileptic drugs (AEDs). Recent studies have found that, during prolonged seizures, when the numbers and activities of GABA receptors gradually decrease, simultaneously, the numbers and activities of glutamatergic NMDA receptors increase. Thus, the commonly used first-line and second-line AEDs gradually fail, often causing RSE and thus providing the possibility of the use of ketamine to treat RSE. Ketamine is a noncompetitive NMDA receptor antagonist that might play a role in treating SE by blocking NMDA receptor-mediated glutamatergic transmission. But after ketamine infusion, its anticonvulsant effects have not been reached. For maximal capture and decrease of brain bioactivity, we used thiopental with a high dose (400 mg/h) infusion. We achieved absolute decrease of brain bioactivity and full resolution of convulsion.

### Conclusion:-

An autoimmune cause was suspected based on frequent or medically intractable seizures and the presence of neural antibody, inflammatory changes indicated in spinal fluid and on MRI. Patients had abnormal findings on brain MRI, with extensive multifocal or diffuse cortical and subcortical involvement. EEG showed generalized periodic discharges and status epilepticus. Within investigation of IgG autoantibodies against proteins on the surfaces of neurons, we received a different result from two different laboratories, but refractory status epilepticus (resistance to anti-seizure medication), radiological changes, EEG pattern, and progress of illness have indicated an autoimmune character of the process.

### References:-

1. Hocker S, Tatum WO, LaRoche S, Freeman WD. Refractory and super-refractory status epilepticus—an update. *Curr Neurol Neurosci Rep* 2014;14:452.
2. Hunter G, Young B. Status epilepticus: a review, with emphasis on refractory cases. *Can J Neurol Sci* 2012;39:157–69.
3. Brophy GM, Bell R, Claassen J, Alldredge B, Bleck TP, Glauser T, et al. Guidelines for the evaluation and management of status epilepticus. *Neurocrit Care* 2012;17:3–
4. Borris DJ, Bertram EH, Kapur J. Ketamine controls prolonged status epilepticus. *Epilepsy Res* 2000;42:117–22.
5. Tarocco A, Ballardini E, Garani G. Use of ketamine in a newborn with refractory status epilepticus: a case report. *Pediatr Neurol* 2014;51:154–6.
6. Synowiec AS, Singh DS, Yenugadhati V, Valeriano JP, Schramke CJ, Kelly KM. Ketamine use in the treatment of refractory status epilepticus. *Epilepsy Res* 2013;105:183–8.
7. Zeiler FA, Kaufmann AM, Gillman LM, West M, Silvaggio J. Ketamine for medically refractory status epilepticus after elective aneurysm clipping. *Neurocrit Care* 2013;19:119–24.
8. Esaian D, Joset D, Lazarovits C, Dugan PC, Fridman D. Ketamine continuous infusion for refractory status epilepticus in a patient with anticonvulsant hypersensitivity syndrome. *Ann Pharmacother* 2013;47:1569–76.
9. Kramer AH. Early ketamine to treat refractory status epilepticus. *Neurocrit Care* 2012;16:299–305.
10. Irani SR, Bien CG, Lang B. Autoimmune epilepsies. *Curr Opin Neurol* 2011;24:146–153

11. Lee WJ, Lee ST, Byun JI, Sunwoo JS, Kim TJ, Lim JA, Moon J, Lee HS, Shin YW, Lee KJ, Kim S, Jung KH, Jung KY, Chu K, Lee SK. Rituximab treatment for autoimmune limbic encephalitis in an institutional cohort. *Neurology* 2016;86:1683–1691.
12. Bien CG. Value of autoantibodies for prediction of treatment response in patients with autoimmune epilepsy: review of the literature and suggestions for clinical management. *Epilepsia* 2013;54(suppl2):48–55.
13. McKeon A, Lennon VA. NMDAR encephalitis: which specimens, and the value of values. *Lancet Neurol* 2014;13:133–135.
14. Gresa-Arribas N, Titulaer MJ, Torrents A, Aguilar E, McCracken L, Leypoldt F, Gleichman AJ, Balice-Gordon R, Rosenfeld MR, Lynch D, Graus F, Dalmau J. Antibody titres at diagnosis and during follow-up of anti-NMDA receptor encephalitis: a retrospective study. *Lancet Neurol* 2014;13:167–177
15. Höftberger R, Dalmau J, Graus F. Clinical neuropathology practice guide 5-2012: updated guideline for the diagnosis of antineuronal antibodies. *Clin Neuropathol* 2012;31:337–341.
16. DeSena AD, Noland DK, Matevosyan K, King K, Phillips L, Qureshi SS, Greenberg BM, Graves D. Intravenous methylprednisolone versus therapeutic plasma exchange for treatment of anti-n-methyl-daspartate receptor antibody encephalitis: a retrospective review. *J Clin Apher* 2015;30:212–216
17. Christian G. Bien,<sup>1\*</sup> Martin Holtkamp<sup>2</sup> “Autoimmune Epilepsy”: Encephalitis With Autoantibodies for Epileptologist ,Current Review , Clinical Science Epilepsy Centre Bethel, Krankenhaus Mara, Bielefeld, Germany, Epilepsy-Center Berlin-Brandenburg, Department of Neurology, Charité – Universitätsmedizin Berlin, Berlin, Germany,