



ISSN NO. 2320-5407

Journal Homepage: - www.journalijar.com

INTERNATIONAL JOURNAL OF ADVANCED RESEARCH (IJAR)

Article DOI:10.21474/IJAR01/4326
DOI URL: <http://dx.doi.org/10.21474/IJAR01/4326>



INTERNATIONAL JOURNAL OF
ADVANCED RESEARCH (IJAR)
ISSN 2320-5407
Journal homepage: <http://www.journalijar.com>
Journal DOI:10.21474/IJAR01

RESEARCH ARTICLE

ROLE OF MITOMYCIN C AS ADJUNCT THERAPY FOR 3-SNIP PUNCTOPLASTY IN CORRECTING PUNCTAL STENOSIS.

Dr Deepak Choudhury¹, Dr. J P Rout², Dr. P K Sharma³, Dr. S Behera⁴, Prof. Dr. J Dora⁵ and Dr. K C Tudu⁶

1. MS, Senior Resident, Regional Institute of Ophthalmology, SCB Medical College, Cuttack.

2. Department of Ophthalmology, Veer Surendra Sai Medical College & Hospital, Burla, Orissa.

Manuscript Info

Manuscript History

Received: 24 March 2017

Final Accepted: 29 April 2017

Published: May 2017

Key words:-

Punctal stenosis, Three snip punctoplasty, Mitomycin c.

Abstract

Aim: To assess the efficacy of intraoperative mitomycin C in improving the success rate of the 3-snip punctoplasty procedure for punctal stenosis.

Materials and Methods: prospective study of 36 eyes of 22 patients who underwent 3-snip punctoplasty between April 2014 to April 2015. The procedure was done without mitomycin C in 14 eyes and with mitomycin C 0.01% intraoperatively for 2 min in 22 eyes.

Results: In group without mitomycin c, 4 of 14 (28.6%) eyes had complete anatomic obstruction and scarring of their puncta after surgery, compared with 0 of 22 (0.0%) eyes in group with mitomycin c. The difference was statistically significant (P=0.03). No significant complications were observed.

Conclusion: Mitomycin C appears to be a safe and effective adjunct therapy in correcting punctal stenosis.

Copy Right, IJAR, 2017.. All rights reserved.

Introduction:-

Stenosis of lacrimal punctum can result from numerous disorders. Infectious agents such as herpes simplex, herpes zoster, and Chlamydia trachomatis, actinomyces & HPV have been noted to cause punctal stenosis. It can be caused by rare systemic conditions such as porphyria cutanea tarda and acrodermatitis enteropathica. It may occur secondary to irradiation topical or systemic chemotherapy & irradiation. Direct and thermal trauma have been associated with punctal stenosis.¹ Senile punctal stenosis can occur due to atony of orbicularis fibers. Initially patients with punctal stenosis may undergo punctum dilatation. In many cases this procedure fails. The surgery involved in attempting to resolve the stenosis is now commonly described as a 1-, 2-, or 3-snip procedure. These descriptions imply the exact number of cuts required to perform the procedure. In this study patients undergoing 3-snip procedure were included.

Mitomycin C (MMC) is a chemotherapeutic agent. It was isolated from *Streptomyces caespitosus*. It inhibits DNA synthesis in all phases of the cell cycle. Cross linkage of the DNA base pairs adenine and guanine is the main mechanism of action. It also causes breakage of single stranded DNA. Rapidly dividing cells are preferentially sensitive to these effects.²

This study was done to assess the efficacy of intraoperative mitomycin C in improving the success rate of the 3-snip punctoplasty procedure for punctal stenosis.

Corresponding Author:-Dr Deepak Choudhury.

Address:-MS, Senior Resident, Regional Institute of Ophthalmology, SCB Medical College, Cuttack.

Material and Methods:-

A non-randomised prospective interventional study involving 36 eyes of 22 patients who have undergone 3-snip punctoplasty in the Ophthalmology OT of a tertiary health care centre in western Odisha from April 2014 to April 2015 spanning across 13 months. Study was done after taking informed consent from patients and approval from Ethical Committee of the Institution. 84 eyes of 56 patients with punctal stenosis were examined during that period. Detail history was taken giving preference to topical medication. Complete ocular examinations were performed in all patients using Slit-lamp. Patients in which Bowman's Lacrimal probe size 00 can't be entered through the punctum were classified as having punctal stenosis. Punctum dilatation was done using Nettelship's punctum dilator. Lacrimal passage irrigation was done to ensure the patency of lacrimal drainage system. Patients were evaluated after 1 month. 36 eyes of 22 patients showed recurrence of punctal stenosis. They were included in the study. Routine laboratory investigations were done and they were hospitalized for 3-snip punctoplasty procedure. Patients were operated in the ophthalmology OT. 1ml of 2% lignocaine with 1 : 100000 epinephrine injected subcutaneously below lower punctum. Punctum dilated sufficiently to allow the posterior wall of ampulla to be grasped with toothed microforceps. Vannas scissors used to excise posterior wall of the ampulla with three snips, the first two downwards on each side of the forceps and the third across the bottom. The procedure was done without mitomycin C in 14 eyes and with mitomycin C 0.01% intraoperatively for 2 min in 22 eyes under local anaesthesia. Follow up was done after 3 months.

Inclusion Criteria: Patients with recurrence of punctal stenosis at the end of 1 month after punctal dilatation.

Exclusion Criteria: Patients with associated lacrimal passage obstruction.

Results:-

36 eyes of 22 patients underwent 3-snip punctoplasty. Figure 1 shows the patient with punctal stenosis. Figure 2 shows the punctum being dilated with the punctum dilator. Figure 3 shows the 3 snip punctoplasty procedure. Age range was from 16 to 63 years. Maximum patients were in the age range from 30 to 50 years comprising of 68% of total patients. Graph-1 shows the age distribution of all patients with recurrent punctal stenosis. Mean age 38.45 ± 12.08 years. 68.2 % patients were female. Graph- 2 shows the sex distribution. In group without mitomycin c, 4 of 14 (28.6%) eyes had complete anatomic obstruction and scarring of their puncta after surgery. All 22 eyes in group with mitomycin c had patent puncta and there was no scarring following surgery at follow up after 3 month. The difference was statistically significant ($P=0.03$). No significant complications were observed after surgery.

32 eyes (88.9%) out of 39 showed almost complete disappearance of dye on the fluorescein dye-disappearance test (FDDT) at the end of 3 months.

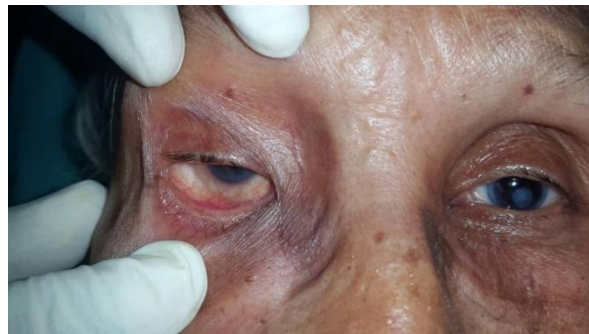

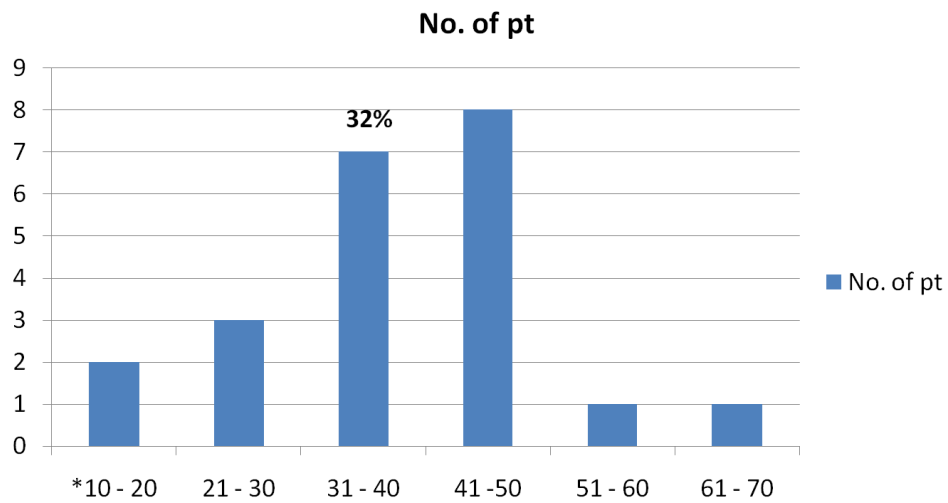
Fig-1:- Patient with punctal stenosis in right eye.

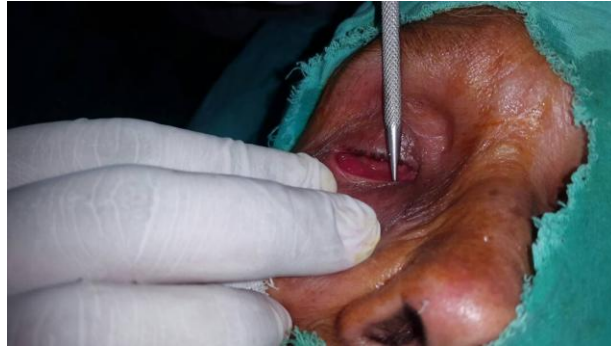

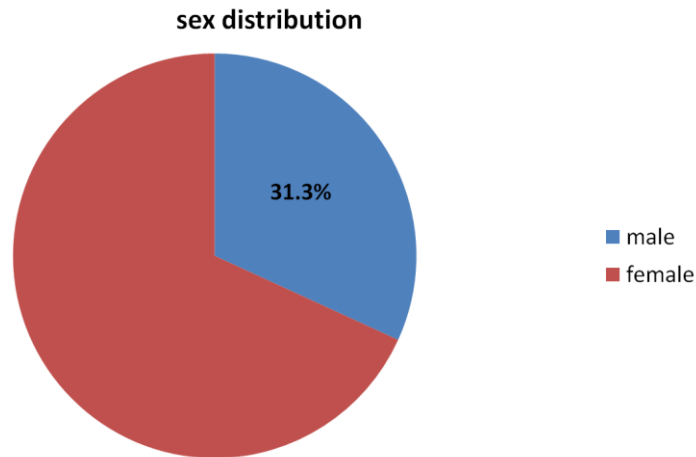
Fig-2:- Punctum was dilated with punctum dilator.

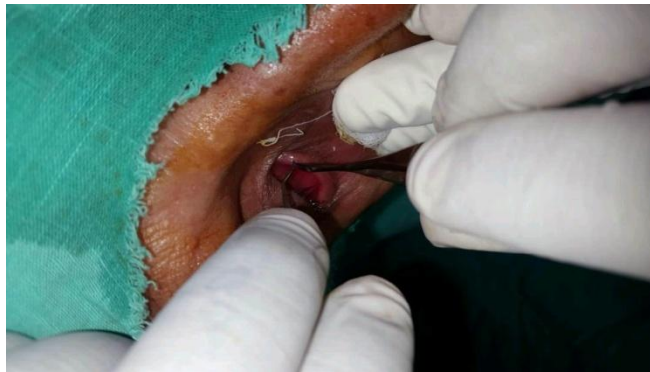

Fig 3:- 3 snip punctoplasty was done



Graph1:- Age Distribution.



Graph2:- Sex distribution.

Discussion:-

Caesar et al found in a study the age range was from 9 to 89 years with a mean of 56 years. A total of 74% of patients were female. The success rate following 3 snip punctoplasty was 92%.³ In our study the mean age group was 38.45 year which is on the lower side of this study. Female were more involved in our study which is comparable. Success following 3- snip punctoplasty is also comparable. According to Billing et al topical mitomycin C for ocular surface neoplasia has been associated with punctal stenosis.⁴ Hamush et al showed beneficial effect of adjunct intraoperative mitomycin c in corrective posterior punctectomy. In this study 5 of 26 (19.2%) eyes had complete anatomic obstruction and scarring of their puncta after punctoplasty surgery without mitomycin c, compared with 0 of 25 (0.0%) eyes in group with adjunct mitomycin c. The difference was statistically significant ($P < 0.02$).⁵ In our study the results are comparable with this study.

Conclusion:-

Mitomycin C appears to be a safe and effective adjunct therapy in preventing recurrent punctal stenosis.

References:-

1. Ronald K. Treatment of Lacrimal Punctal Stenosis with a One-Snip Canaliculotomy and Temporary Punctal Plugs. Arch Ophthalmol. 1988;106(7):878-9.
2. Kopp D, Seregard S. Epiphora as a side effect of topical mitomycin c. Br J Ophthalmol. 2004 Nov; 88(11): 1422-4.
3. Caesar H, McNab A. A brief history of punctoplasty: the 3-snip revisited. Eye. 2005; 19: 16-8.
4. Billing K, Karagiannis A, Selva D. Punctal-canalicular stenosis associated with mitomycin-C for corneal epithelial dysplasia. Am J Ophthalmol. 2003;136(4):746-7.
5. Ma'luf RN, Hamush NG, Awwad ST, Noureddin BN. Mitomycin C as adjunct therapy in correcting punctal stenosis. Ophthal Plast Reconstr Surg. 2002;18(4):285-8.