



Journal Homepage: -www.journalijar.com
**INTERNATIONAL JOURNAL OF
 ADVANCED RESEARCH (IJAR)**

Article DOI:10.21474/IJAR01/3201
 DOI URL: <http://dx.doi.org/10.21474/IJAR01/3201>



RESEARCH ARTICLE

CASE REPORT : ORBITAL CELLULITIS IN OLD PATIENT WITH HISTORY OF OCULAR INTERVENTION.

Dr. Fatima al.mulhim¹, Dr .Anoud al-jamaan¹, Dr.kauser², Dr.Abdulmohsin al-mulhim³, Dr.Muslem Al-besher¹, Hussain Al-Sinni⁴, Dr. Eman Al kishi¹ and Dr. Ahmed Al-esmael³.

1. Ophthalmology Resident , Aljaber Eye And ENT Hospital, Kingdom Of Saudi Arabia.
2. Ophthalmology Specialist, Aljaber Eye And ENT Hospital, Kingdom Of Saudi Arabia.
3. ER Resident, King Fahd Hospital, Kingdom Of Saudi Arabia.
4. ENT Resident, Aljaber Eye And ENT Hospital, Kingdom Of Saudi Arabia.

Manuscript Info

Manuscript History

Received: 09 December 2016
 Final Accepted: 15 January 2017
 Published: February 2017

Key words:-

orbital cellulitis , periosteal abscess ,
 proptosis , sinusitis associated
 ophthalmomology

Abstract

Orbital cellulitis is considered as an ocular emergency which needs urgent evaluation and proper quick action to save the patient vision or even life

The aim of this report is to present a case about orbital cellulitis with the presence of multiple risk factors as sinusitis and ocular intervention and how to approach such patients

Copy Right, IJAR, 2017,. All rights reserved.

Introduction:-

Orbital cellulitis is an inflammation of the soft tissues of the eye socket posterior the orbital septum,It most commonly occurs when bacterial infection spreads the adjacent paranasal sinuses or other nearby structures such as the face , eyelids or the lacrimal drainage system through the blood streamAlso , It can be caused by a direct trauma to the orbit ,in which traumas may introduce an infectious materials into the orbitother causes were reported such as direct inoculation of the orbit from surgery or Hematogenous spread from bacteremiaOrbital cellulitis is an ocular emergency that not only threatens vision but also can lead to life-threatening complications if left untrated such as cavernous sinus thrombosis, meningitis, and brain abscess.'Careful history taking and physical examination must be done for fast disease recognition and proper management

Case Report:-

86 years old Female presented to our hospital ER , complaining of right eye Pain , Redness and Swelling of the eyelid for 3 daysIt was gradual in onset , Progressed rapidly within these 3 days with significant decrease of vision .

Regarding her Past history the patient is Known hypertensive for long time on antihypertensive medication with regular follow ups in PHC .

Also ,she reported History of chronic arthritis .

Regarding her Past ocular history , she was diagnosed with nasolacrimal duct obstruction in a previous visit and She underwent right syringing probing in our hospital 5 days prior to the admission .

Corresponding Author:-Dr. Fatima al.mulhim.

Address:-Ophthalmology Resident , Aljaber Eye And ENT Hospital, Kingdom Of Saudi Arabia.

The patients Clinical findings were as follows:-

Her Vision in the Right Eye was counting fingers at 2 METERS and the left eye 0.5 both without correction
Intraocular pressure was normal in both eyes Right eye examination revealed Upper and lower eyelid tender swelling along with conjunctival congestion and Chemosis.

There was also Non axial proptosis pushing the globe slightly outward and downwards with restriction of ocular movements in all directions .

On slit lamb Anterior segment examination:-**Right Eye:-**

There was Grade 1 RAPD
Immature cataract

Fundus: WNL

Left Eye:-

Anterior segment-
Immature cataract

Fundus: within normal level

The patient was admitted to the hospital:-**Investigations:-****CT-scan:-**

Axial and coronal CT scan was done with and without contrast done , revealed sub periosteal abscess in the upper medial wall of the orbit originating from the ethmoid sinus which showed signs of sinusitis.

The patient was given the following Treatment:-**Medical treatment in the form of:**

Injection IV Ceftriaxone 1 gm BID
Ciprofloxacin Eyedrops q4 hourly
Chloramphenicol Eye ointment HS
Tablet Brufen 400 mg BID
Tablet Ranitidine 150 mg BID

After the CT scan results came, Surgical treatment started:-

The sub periosteal abscess was drained under general anesthesia through the caruncular approach and the pus was sent for culture and sensitivity.

A swab was also taken.

Postoperative treatment:

Injection IV Ceftriaxone 1gm BID
Injection Vancomycin 500mg q6hrs
Injection Flagyl 500mg TID
Tab Prednisolone 50 mg PO OD
Tab Brufen 400 mg BID
Tab Ranitidine 150 mg BID

Postoperative picture:-**1ST post operative day**

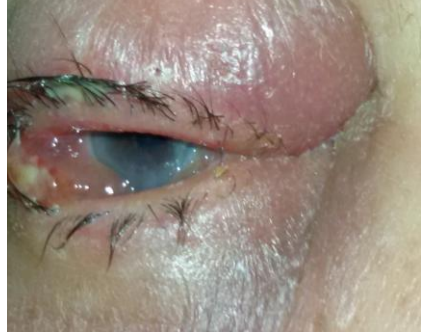the general condition of the patient improved

Vision: counting fingers 3 meters

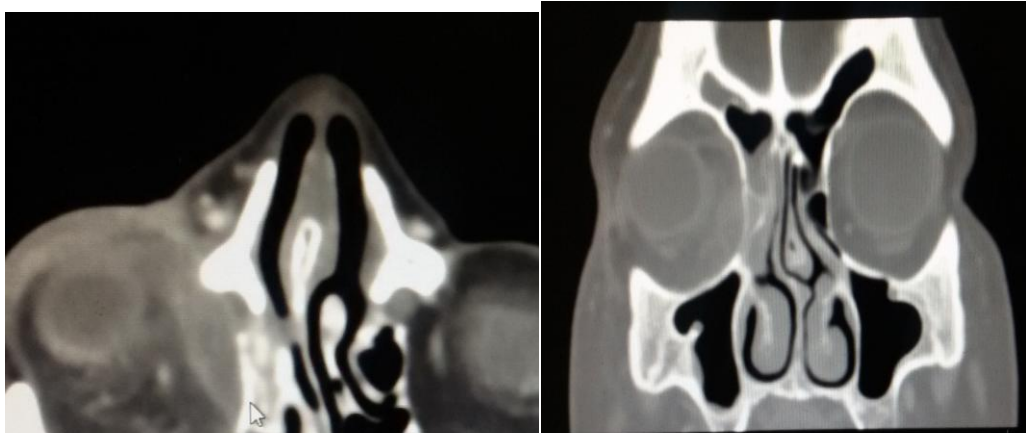
The pain was relieved

The lid edema and the chemosis were reduced

The ocular movements had improved



Right eye examination revealed Upper and lower eyelid tender swelling along with conjunctival congestion and Chemosis .



CT Scan without contrast revealed sub-periosteal abscess in the upper medial wall of the orbit originating from the ethmoid sinus which showed signs of sinusitis

Discussion:-

Displacement of the globe may be due to an increase in the orbital contents. the orbit has rigid bony walls except its anterior wall , such displacement usually manifests predominantly as forward protrusion of the globe which is called proptosis , which is the hallmark of orbital disease.

orbital cellulitis may due to an injury perforating the orbital septum.

The Inflammation process can be noticed within the first 48-72 hours after injury, it may be delayed for several months if retained orbital foreign body.

Some orbital cellulitis cases were reported after surgical procedures, such as orbital decompression, DCR, blepharoplasty, squint surgeries, retinal surgery, and glaucoma surgery.

The diagnosis of orbital cellulitis is usually based on clinical findings with the aid of radiological findings sometimes

Usually , The presence of orbital signs such as proptosis, pain during eye movements , ophthalmoplegia, optic nerve involvement as well as fever and high WBC count confirm the diagnosis. Age, medical history , the presence of trauma and the mechanism of injury play an important role in determining the causative organism of orbital disease. Staphylococcus species, Streptococcus species and Bacteroides species are the most common organisms detected in adult orbital cellulitis , while unvaccinated children can present with sequelae from Haemophilus influenzae. To be noticed , some organisms can be detected In all age groups with specific conditions , for example , dental abscess with mixed, aggressive aerobic and/or anaerobic infection must be considered if a suggestive history is elicited. Gram-negative rods are likely to be the causative organism recovered in abscesses

secondary to trauma. Fungal infections, including mucormycosis/zygomycosis and aspergillosis , especially in diabetic or immunocompromised hosts.

Age of the patient	Microbiology results	Surgical management
Less than 9	No growth or one anaerobic microorganism	Not indicated
From 9 to 14	Mixed aerobic and anaerobic microorganism	Possible
More than 14	Mixed or only anaerobics	Indicated

Conclusion:-

Orbital cellulitis due to Subperiosteal abscess is a well-described infectious process that affects the bones supporting the globe. It can cause rapid clinical deterioration of the bone and intracranial extension. Careful clinical monitoring, serial ophthalmologic examinations and comparative radiologic screening of persons must be done , followed by prompt and appropriate treatment. Thses details are necessary to decrease the risk of complications, such as permanent vision loss, cavernous sinus thrombosis and cerebral abscesses.

Orbital cellulitis is considered as an ocular emergency which needs urgent evaluation and proper quick action to save the patient vion or even life.

References:-

- John Forrester Andrew Dick Paul McMenamin Fiona Roberts Eric Pearlman , The eye , page 1,2,3,4,
- Richard S. Snell, Michael A. Lemp clinical anatomy of the eye page 70
- Kanski's Clinical Ophthalmology, 6th Edition , A Systematic Approach page 175, 176
- Vaughan, Daniel & Asbury, Taylor. *General Ophthalmology*. Los Altos, CA. Lange Medical Publications, 1958. (15th edition 1999, with Riordan-Eva, P. Appleton, Lange) chapter 13 , the orbit
- Renu Jogi , basic ophthalmomlogy , the orbit page 439
- British Journal of Ophthalmology, 1989, 73, 205-208 Orbital cellulitis: review of 23 cases from Saudi Arabia
- American Academy of Ophthalmology. *Basic and Clinical Science Course*. San Francisco, CA A.A.O. 1940-2000 eyewiki. Orbital cellulitis