

Cornual Ectopic Pregnancy: A Case Report

by Jana Publication & Research

Submission date: 15-Feb-2025 12:20PM (UTC+0700)

Submission ID: 2576796691

File name: IJAR-50269.docx (222.42K)

Word count: 986

Character count: 5901

Cornual Ectopic Pregnancy: A Case Report

² Abstract

Cornual ectopic pregnancy (CEP) is a rare but high-risk form of ectopic pregnancy, accounting for 2–4% of all ectopic pregnancies. Due to its location in the highly vascularized uterine cornu, CEP poses a significant risk of massive hemorrhage and maternal mortality upon rupture. Early diagnosis is crucial but challenging due to nonspecific symptoms and its ability to grow longer than other ectopic pregnancies before presenting complications.

¹ Introduction

Ectopic pregnancy (EP) is a condition in which the embryo implants outside the uterine cavity, most commonly in the fallopian tubes. Among atypical locations, cornual ectopic pregnancy (CEP)—where implantation occurs in the uterine cornu—is particularly rare, accounting for approximately 2–4% of all ectopic pregnancies (em-consulte.com).

CEP is particularly dangerous due to the high vascularity of the uterine cornu, which predisposes it to massive hemorrhage when rupture occurs. Mortality rates associated with ruptured CEP can reach 2.5%, making it one of the most life-threatening forms of ectopic pregnancy. Early diagnosis and timely intervention are critical in preventing severe maternal complications.

⁴ Case Presentation

We report the case of a 21-year-old woman from Fès, admitted to CHU Hassan II for diffuse abdominal pain lasting one day.

The patient had no significant medical history, with no hypertension, diabetes, nephropathy, cardiac disease, tuberculosis, or known infectious exposure.

Gynecologically, she was G3P1, with one previous miscarriage and one living child born vaginally.

On admission, the patient was conscious but hemodynamically unstable, with hypotension (BP 70/40 mmHg), tachypnea, pale conjunctivae (suggesting anemia), and a normal temperature (36.8°C).

Abdominal examination revealed diffuse tenderness, while gynecological assessment showed:

- No vaginal bleeding on speculum examination.
- A palpable left adnexal mass on bimanual examination.

Blood tests showed:

- Hemoglobin at 7.8 g/dL → Indicating severe anemia.
- Leukocytosis (WBC 36,000/mm³) and elevated CRP, suggesting inflammation.
- β-HCG level of 31,480 IU/L, confirming pregnancy.
- Blood type: A+.

Pelvic ultrasound revealed:

- An empty uterine cavity with a normal-sized uterus.
- A gestational sac located in the cornual region.
- A large amount of free fluid reaching Morrison's pouch, suggesting massive hemoperitoneum.

Based on these findings, ruptured cornual ectopic pregnancy was suspected, and the patient was taken for emergency surgery.

A laparotomy was performed, revealing massive hemoperitoneum (~1 liter of blood).

A ruptured left cornual ectopic pregnancy was identified. Given the extent of the rupture and ongoing hemorrhage, a left salpingectomy was performed.

The patient was transfused with 2 units of O+ packed red blood cells and 4 units of fresh frozen plasma to stabilize her condition.

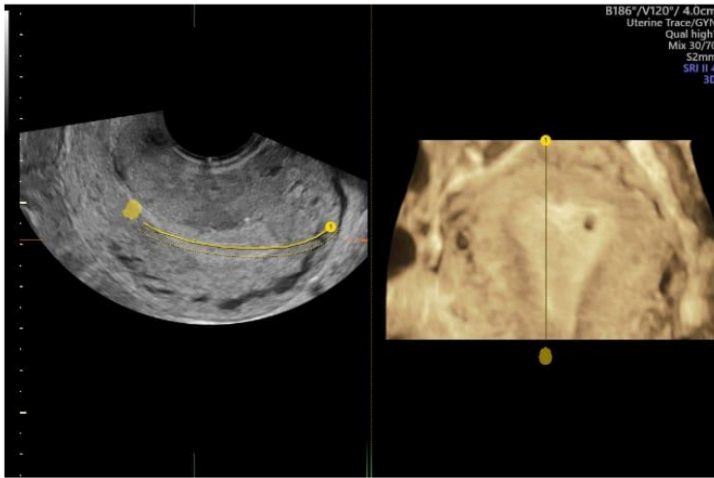


FIGURE 1 : 3D ultrasound images showing the presence of a left cornual ectopic pregnancy with an empty uterine cavity.

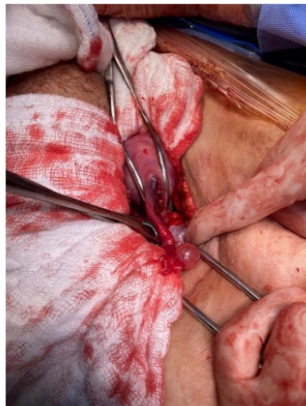


FIGURE 2 : Laparotomy image showing a ruptured left cornual ectopic pregnancy with a healthy left fallopian tube.

Discussion

Cornual ectopic pregnancy is a rare but highly dangerous form of ectopic pregnancy due to late presentation, delayed diagnosis, and increased risk of rupture.

The cornual region of the uterus has a thick myometrial layer and a rich blood supply from both the uterine and ovarian arteries. While this allows the pregnancy to grow longer before symptoms arise, it also increases the risk of severe hemorrhage upon rupture.

Risk factors for cornual pregnancy include:

- Previous ectopic pregnancy.
- Tubal surgery or salpingectomy.
- History of in-vitro fertilization (IVF) or assisted reproductive techniques.
- Use of an intrauterine device (IUD).
- Uterine anomalies (e.g., bicornuate uterus).

Cornual pregnancy often presents later than typical tubal ectopic pregnancy, sometimes as late as 8–12 weeks of gestation. The nonspecific symptoms—such as mild abdominal pain, minimal bleeding, or delayed menses—can lead to delayed diagnosis.

Ultrasound is the gold standard for diagnosis. The classical sonographic findings include:

- An empty uterine cavity.
- A gestational sac located in the cornual region.
- A thin surrounding myometrium (<5mm).
- Increased vascularity on Doppler imaging (the “ring of fire” sign).

However, in emergency cases, hemoperitoneum may be the only clue, as seen in our patient.

Management depends on hemodynamic stability and gestational age:

- Medical management (Methotrexate) is an option in early, stable cases but carries a high failure rate for cornual pregnancies.

- Minimally invasive techniques (laparoscopic resection or cornuostomy) are preferred in stable patients to preserve fertility.
- Laparotomy with cornual resection or hysterectomy is necessary for ruptured cases with severe hemorrhage, as seen in this patient.

At CHU Hassan II in Fès, a retrospective study of 161 ectopic pregnancy cases between 2010 and 2014 found an overall incidence of 1.32% (chu-fes.ma). However, specific data on cornual pregnancies was not detailed.

Prognosis and Future Fertility

Fertility outcomes after CEP depend on the extent of surgical intervention.

- Cornual rupture increases the risk of uterine rupture in future pregnancies.
- Patients should be counseled about the need for cesarean delivery in subsequent pregnancies due to the risk of uterine rupture.
- Hysteroscopic repair or laparoscopic suturing may improve future reproductive outcomes in selected cases.

Conclusion

⁵ This case highlights the importance of early diagnosis and prompt surgical intervention for cornual ectopic pregnancy. Due to its high risk of rupture and massive hemorrhage, delayed management can be fatal.

⁶ Clinicians must maintain a high index of suspicion, especially in young women presenting with abdominal pain, anemia, and a positive pregnancy test. Early ultrasound assessment and timely surgical intervention remain the cornerstone of management.

References

1. Cornual ectopic pregnancy: Management, future fertility, and histopathological analysis
 - a. Overview of surgical vs. medical management and reproductive outcomes after cornual resection.
 - b. em-consulte.com
2. Laparoscopic management of ectopic pregnancy: A case series of 18 cases
 - a. Retrospective study on laparoscopic treatment of ectopic pregnancies at CHU Hassan II, Fès.
 - b. chu-fes.ma
3. Ectopic pregnancy at the CHU Hassan II obstetrics unit: 161 cases
 - a. Retrospective analysis of 161 cases between 2010-2014.
 - b. chu-fes.ma
4. French National Guidelines on Ectopic Pregnancy Management (CNGOF, 2003)
 - a. Detailed recommendations for the diagnosis and treatment of ectopic pregnancy.
 - b. cngof.asso.fr
5. Case Report: Ruptured Cornual Ectopic Pregnancy
 - a. Diagnostic and management challenges of a left cornual ectopic pregnancy.
 - b. hsd-fmsb.org

Cornual Ectopic Pregnancy: A Case Report

ORIGINALITY REPORT

16%

SIMILARITY INDEX

11%

INTERNET SOURCES

11%

PUBLICATIONS

2%

STUDENT PAPERS

PRIMARY SOURCES

1	link.springer.com Internet Source	2%
2	hematology.conferenceseries.com Internet Source	2%
3	www.coursehero.com Internet Source	2%
4	www.pubfacts.com Internet Source	1%
5	www.ruralneuropractice.com Internet Source	1%
6	Christopher M. Janson, Maully J. Shah. "Supraventricular Tachycardia in Adult Congenital Heart Disease", Cardiac Electrophysiology Clinics, 2017 Publication	1%
7	Mamta Dagar, Mala Srivastava, Indrani Ganguli, Punita Bhardwaj, Nidhish Sharma, Deepak Chawla. "Interstitial and Cornual Ectopic Pregnancy: Conservative Surgical and Medical Management", The Journal of Obstetrics and Gynecology of India, 2017 Publication	1%
8	Thakur Y. "Laparoscopic and ultrasound- guided transcervical evacuation of cornual ectopic pregnancy: an alternative approach",	1%

Journal of Obstetrics & Gynaecology,
10/1/2004

Publication

9	repositorium.sdum.uminho.pt Internet Source	1%
10	www.ijcasereportsandimages.com Internet Source	1%
11	"E-Posters, EP13", BJOG An International Journal of Obstetrics & Gynaecology, 2013. Publication	1%
12	Geetha Krishnamoorthy, Thasneem Mohamed Arif. "INTERSTITIAL PREGNANCY- A CASE REPORT", Journal of Evolution of Medical and Dental Sciences, 2018 Publication	1%
13	Lodhi, W.. "Laparoscopic cornuectomy revisited: a case series of 3 patients using the Multifire Endo GIA Stapler", European Journal of Obstetrics and Gynecology, 201112 Publication	1%

Exclude quotes On

Exclude matches Off

Exclude bibliography On