

# COMBINED THERAPY: PLATE CRYOLIPOLYSIS AND AUSSIE CURRENT FOR CLINICAL BODY HARMONIZATION PROTOCOL

*by* Jana Publication & Research

---

**Submission date:** 03-Feb-2025 12:22PM (UTC+0700)

**Submission ID:** 2578235308

**File name:** IJAR-50129.docx (956.42K)

**Word count:** 4663

**Character count:** 27236

## COMBINED THERAPY: PLATE CRYOLIPOLYSIS AND AUSSIE CURRENT FOR CLINICAL BODY HARMONIZATION PROTOCOL

### ABSTRACT

**Background:** Criolipólise is a technology widely used for aesthetic treatments that aim to reduce the layer of subcutaneous tissue. The application using plates revolutionized the protocols, once it favored the treatment of different body areas, difficult to treat with suction applicators. **Objective:** The objective of this study was to evaluate an integrative aesthetic treatment protocol, uniting different technologies and therapeutic approaches, including combined cryolipolise and Aussie current therapy, with the aim of achieving body harmonization through completely non-invasive methods. **Methods:** A female patient, 31 years old, with localized fat in the anterior and posterior trunk region, butt and coxa region was selected. The treatment protocol recommends an integrative approach such as the use of cryolipolise of plates associated with Aussie current, complemented by ultrasonic and radiofrequency technologies. The methods used to evaluate body weight, waist circumference, quadrilateral and digital photography for comparison before and after treatment. **Results:** The results demonstrate better body contour, resulting in harmonization. By means of circumference measurements, it was possible to observe a reduction in the abdominal region, including upper, middle and lower waist, of 15.63%, 21.13% and 12.82% respectively, followed by a reduction of 8.82% in the region do quadril. **Conclusion:** It is possible to conclude that non-invasive therapeutic resources are effective in achieving results of body harmonization, with expressive reduction of subcutaneous tissue content.

**Keywords:** cryolipolysis, plate applicator, body fat, body harmonization

## **INTRODUCTION**

Cryolipolysis is an aesthetic procedure widely used to reduce localized fat by freezing subcutaneous tissue. The development of this technology arose from clinical observations of fat reduction when adipocytes were exposed to cold. These cells are more responsive to cold and are capable of undergoing apoptosis when their internal content, triglycerides, undergo crystallization after a period of time exposed to low temperatures (1–4).

With the emergence of this treatment approach, mainly focused on aesthetic treatment, different scientific aspects were investigated, with the intention of proving such effects (5–9). The literature points to several clinical protocols aimed at treating different body areas that present localized fat. In addition, currently two important additional factors that contribute to the final result of the treatment have been described, one related to improving skin sagging and the other aimed at inducing body thermogenesis (10–12).

In an integrative therapeutic assessment, it is necessary to observe different aspects in the anamnesis, which include not only the amount of localized fat, but also the patient's health conditions and lifestyle. In general, to promote a body harmonization procedure, we must consider the muscular system, subcutaneous tissue and cutaneous tissue. Muscular tissue can directly contribute to increased metabolism through the oxidation of triglycerides, in addition to improving tissue oxygenation and promoting improved tissue support through strengthening. Adipose tissue, on the other hand, has the function of storing lipids that serve as an energy reserve, but it also acts to induce thermogenesis. In turn, the quality of the skin tissue also reflects on the final appearance of the treatment, requiring an intervention focused on reestablishing the matrix through collagen synthesis (3,13–17).

Due to the evolution of scientific knowledge about the clinical aspects of cryolipolysis as well as its action in the biological environment, the view on clinical protocols has been modified, thus emerging the proposal of body harmonization.

Interesting advantages are observed because it is a non-invasive, safe, painless approach, without the need for long recovery periods, and that uses the cellular mechanisms themselves to obtain the results (2). To this end, the main strategy is to prepare all tissues involved, using therapeutic hypopressive exercises to assist in the mobility and support of the abdominal and postural region, endermotherapy for myofascial release with improved local oxygenation, and electrotherapy considered the gold standard to induce muscle strengthening and lipolysis (18–21), and then using the freezing strategy in sequential mode to induce thermogenesis, which will act directly on increasing metabolism, favoring the reduction of fat content (3,10).

However, despite the effects described on each of the techniques described, this strategy of association in two distinct stages to achieve body harmonization is not yet evidenced in the literature, and is therefore an innovative strategy that can revolutionize the area of aesthetics through an integrative approach. <sup>19</sup> Therefore, the objective of this study was to evaluate an integrative aesthetic treatment protocol, combining different technologies and therapeutic approaches, including the combined therapy of cryolipolysis and Aussie current, with the purpose of achieving body harmonization through completely non-invasive methods.

## METHODS

### Type and Location of Research

This case study was carried out in partnership with the Brazilian medical equipment industry - IBRAMED under <sup>4</sup> the approval of the ethics committee number 6.909.656.

### Participants:

The participant <sup>4</sup> was selected based on the assessment of the clinical condition. The exclusion criteria for choosing the case study were diabetes mellitus, metabolic and/or liver diseases, pregnancy, postpartum or breastfeeding women, sensitivity or allergy <sup>13</sup> to cold such as urticaria, Raynaud's disease, chilblains, dermatitis; keloids, hernias, excessive skin sagging, scars at the treatment sites, bleeding disorders, recent surgery at the treatment site; regular use of anti-inflammatory drugs; liposuction, mesotherapy or abdominoplasty. The initial evaluation detected aesthetic changes related to the <sup>14</sup> accumulation of localized fat in the abdomen, flanks, thighs and hips.

### **Clinical picture**

A 31-year-old female patient with localized fat in the infra and supra umbilical region, lateral and posterior region of the trunk, as well as regions of the breast, back, hips, and thighs. As a result, the body contour was consequently altered, modifying the harmonization of the body curves related to the waist and hips. It is worth noting that the physical examination did not reveal the presence of abdominal hernias that would compromise the application of the clinical protocol with cryolipolysis.

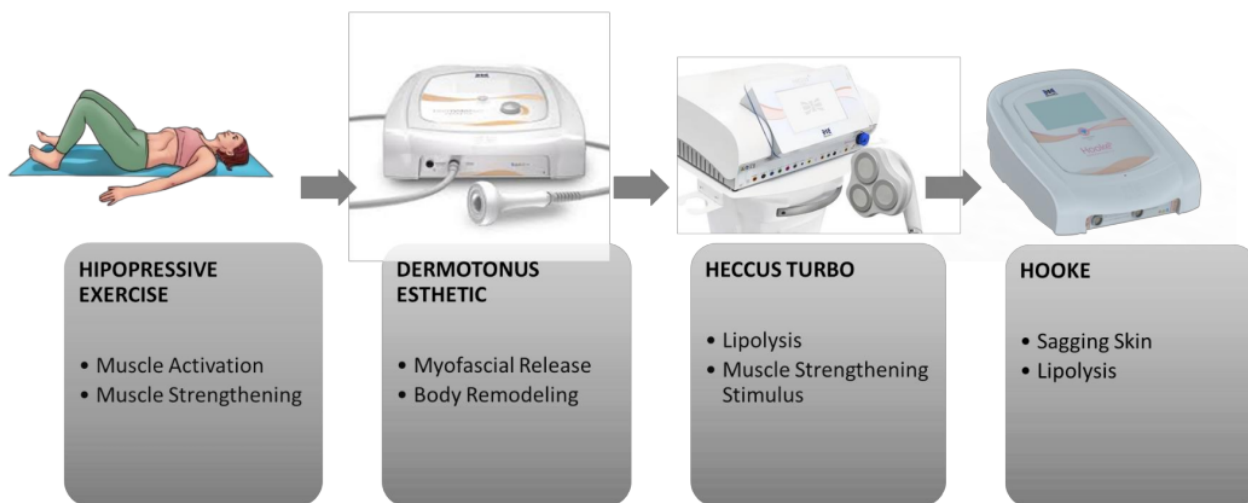
### **Clinical Treatment Protocol**

The treatment protocol used advocated a comprehensive and integrative approach. To this end, after the patient's medical history, she was referred to a nutritionist who recommended a diet to help with the body's inflammation and improve the gastrointestinal tract. Subsequently, the clinical approach focused on aesthetic treatment was initiated with the aim of preparing the patient before exposure to the cryolipolysis protocol for body harmonization. The integrative protocol, considering the total treatment approach, lasted 4 months.

### **Preparation before the cryolipolysis procedure**

For the aesthetic protocol, the sessions began with hypopressive exercises, guided in the clinic and performed in home care, throughout the evolution of the treatment, aiming at improving tissue oxygenation and muscle strengthening. In addition, five treatment sessions were performed in the clinic. The sessions began with cleaning the abdominal area with 5% alcoholic chlorhexidine, followed by light tissue exfoliation with a neutral cosmetic. Then, a myofascial release protocol was applied in four different quadrants, being the right and left supraumbilical and the right and left infraabdominal, using the Dermotonus Esthetic equipment (IBRAMED) with a pressure of 50 mmHg and a time of 5 minutes. Immediately after, combined therapy was applied using ultrasound associated with electrostimulation with *Aussie* current, present in the pre-programmed protocols of the Eccus turbo equipment (IBRAMED) for 4 min in each quadrant, aiming at both stimulating lipolysis and muscle strengthening in the same session. Subsequently, radiofrequency was applied through the monopolar applicator, associated with a dispersive electrode (positioned 20 cm away from the treatment region), using the Hooke equipment (IBRAMED), in the region of the linea alba for three minutes, at a temperature of 40°C, for specific

stimulation of flaccidity. Finally, the active muscle strengthening protocol was applied, using *Aussie* current. The electrodes were positioned in the region of the muscular belly of the rectus abdominis muscles and, with each stimulus sent by the current, the patient was asked to perform the hypopressive exercise maneuver, contracting the abdominal muscles to activate their fibers, aiming at strengthening the abdominal region (rectus and oblique muscles), for 25 min. Finally, the therapist performed manual maneuvers with local body drainage stimuli throughout the trunk and abdomen region.



**Figure 1.** - Demonstration of the steps with the respective technologies and their main clinical effects.

### **Cryolipolysis protocol with induction of thermogenesis**

In this stage, the patient was exposed to the cryolipolysis protocol aiming at thermogenesis. For this, plate cryolipolysis was used with the Polarys Plaxx equipment, developed by the Brazilian Medical Equipment Industry (IBRAMED) equipment for 3 consecutive days. The temperature used was  $-8^{\circ}\text{C}$  with an exposure time of 60 minutes per treated area, and every 15 minutes, the plates were removed from the tissue for local


tissue reperfusion maneuver through manual massage for 1 minute. For a better understanding of the clinical evolution of this protocol, the treatment stages are described in detail below. It is worth mentioning that the execution of the application of plate cryolipolysis associated with electrostimulation in the same treatment region and at the same time is only possible due to a specific protocol presented by the Polarys Plaxx – IBRAMED. The method of application of the treatment protocol with its respective strategies is described in detail below and is divided into different days.

**First day** - Application of 2 cryolipolysis plates with electrostimulation in the infraumbilical abdominal region for 60 minutes. For this stage, the parameters used were: Duet mode: cryolipolysis associated with Aussie current in simultaneous application. In addition, two self-adhesive electrodes were positioned in the region of the rectus femoris muscle belly in each of the lower limbs (right and left) using Aussie current to promote muscle strengthening, with the intensity adjusted depending on the patient's sensory.

**Second day** – On the second day, the same protocol as on day 1 was followed, but in the supra-umbilical abdominal region, with the plates positioned side by side. Two cryolipolysis plates were used in association with electrostimulation with Aussie current in the supra-umbilical region, at a temperature of -8 degrees, for 60 min. In addition, two self-adhesive electrodes were positioned in the region of the rectus femoris muscle belly on each of the lower limbs (right and left) using Aussie current to promote muscle strengthening, with the intensity adjusted depending on the patient's sensory level.

**Third day** - On the last day of application, the same protocol was used, but in the posterior body region, encompassing flanks with application of Aussie current for muscle strengthening using the electrodes in the posterior region of the lower limbs.

It is worth noting that throughout the treatment protocol, the cryolipolysis temperature was maintained at -8 °C for a fixed time of 60 minutes, with reperfusion performed every 15 minutes to check the condition of the tissue and restore microcirculation.



### Evaluations

For the evaluation, data were first collected from the patient to determine whether they met the inclusion criteria for the study. Next, anamnesis was performed to collect weight, perimetry, adipometry, photographic images for comparison of before and after measurements, and a patient satisfaction questionnaire. Data collection was always performed in the morning by the same evaluator (blinded to the treatment) at different times to record the evolution of the clinical condition. The collections were performed one week before treatment; fifteen, thirty, sixty, ninety, and one hundred and twenty days after the start of treatment.

The standardization of the evaluation site for the adipometry methodologies was determined at two different points selected in each quadrant of the abdomen. The demarcation of the points was made 5 centimeters laterally in relation to the linea alba for both the right and left sides. For the assessment of perimetry, three demarcations were established, with the midline of the navel region being considered the first, high



waist located 5 centimeters (cm) above the navel and low waist located 5 cm below the navel.

### **Anamnesis of the treatment area**

During the evaluations, an anamnesis form prepared exclusively for this study was completed. This form collected anthropometric measurements as well as personal data, lifestyle habits, medications, type of diet, information related to the inspection of the treatment area, history of aesthetic procedures performed in the treatment area, skin color and type, and a patient satisfaction questionnaire regarding the treated area.

### **Body circumference analysis**

The analysis was performed to measure body perimeters using a tape measure. The measurement was taken on the abdominal circumference respecting the horizontal lines previously determined and described in the application method. Therefore, a measurement was taken above the umbilical scar, a measurement 5 centimeter (cm) above and a mean 5 cm below (Lee, 2010).

### **Adipometry Analysis**

For this analysis, a clinical adipometer was used on two skin folds, one 5 cm above and one 5 cm below the umbilical line on both the right and left abdomen, using the marking of the first application point as a reference. Three consecutive measurements were performed, and then an average was attributed as the final value, thus determining the value of the fat fold.

### **Photographic analysis**

After the area to be photographed has been cleaned, the patient will be positioned standing 70 cm away from the wall and 2 meters from the camera, and will be instructed to keep her body positioned with her gaze directed towards the horizon. A digital camera (Canon EOS Rebel T3I, Canon USA INC., Melville, NY, USA) will be used to capture the images, fixed to a tripod 1 meter and 5 centimeters from the floor, centered, with the Zoom maintained at 1x. The lighting will be standard with a central focus of white light. Escala Visual Analógica Subjetiva

To assess pain in the application region, a subjective visual analogue scale of 0-10 was used, where 0 = there was no sensation of pain or heat, 1-4 = mild pain or heat, 5-7 = moderate pain or heat, 8-10 = intense pain or heat.

### Assessment of satisfaction and quality of life

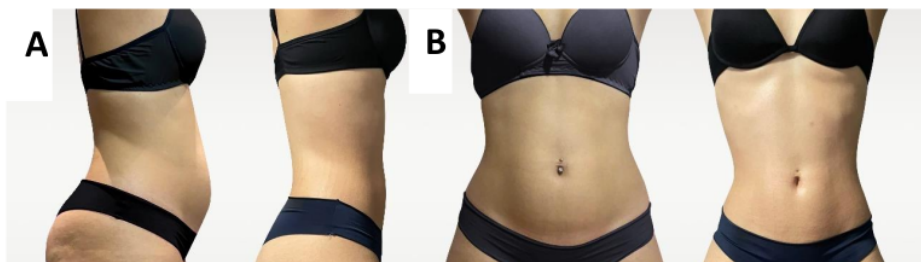
1 Patient satisfaction will be assessed using a questionnaire using the Global Aesthetic Improvement Scale – GAIS, by Narins (2003), which is used to classify response to treatments, allowing a comparative assessment at different times after the therapeutic intervention.

### Statistical analysis

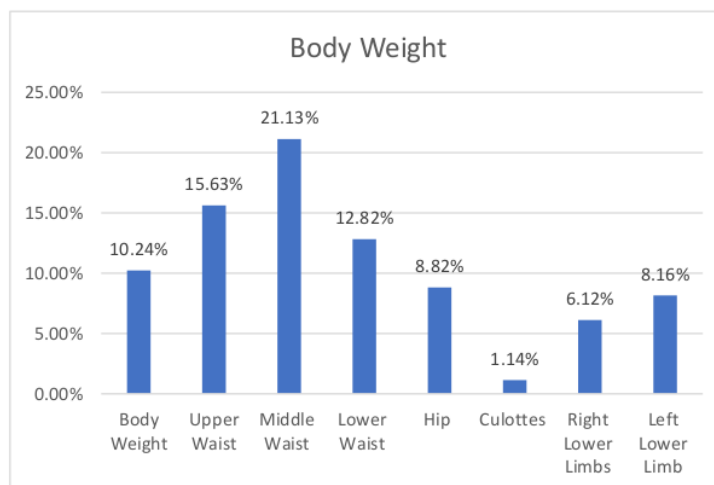
2 Descriptive analysis was used with frequency tables for categorical variables and descriptive statistics (mean, standard deviation, median, minimum and maximum values) for continuous or numerical variables.

## RESULTS

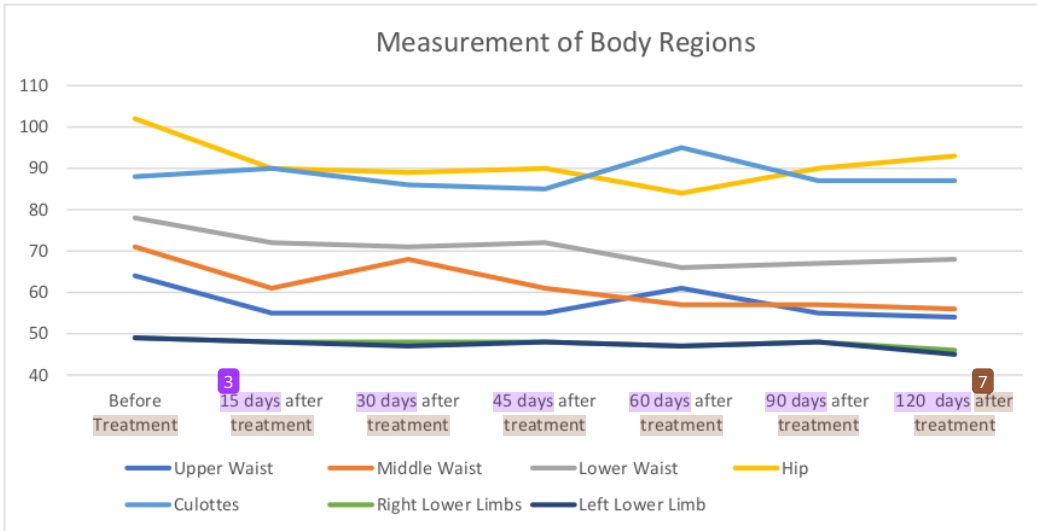
3 In the evaluation of the evolution of the clinical condition studied, important factors were recorded. When comparing the before and after photos with the patient in the orthostatic position in the frontal and lateral positions, it was possible to observe a significant difference in relation to the body contour. In addition, other aspects are relevant, such as the reduction in abdominal circumference with abdominal retraction, demonstrating an improvement in both body composition and muscle support, and the significant improvement in relation to the reduction in hip circumference associated with the reduction of cellulite content in the gluteal region, evidenced in figure A. Considering another angle of evaluation, in the frontal position, shown in figure B, it is also possible to observe the reduction in both abdominal and hip circumference, which significantly affects the waist-hip ratio. In addition, it is worth highlighting the significant improvement in body contour.



Graph 1 shows a 10.24% reduction in body weight during the course of treatment, starting with 72.3 kg and ending the protocol with 64.9 kg (Table 1). In the evaluation of the body measurements presented in Graph 2, it is possible to observe that the greatest reduction occurred in the abdominal region, including the upper, middle and lower waist, 15.63%, 21.13% and 12.82% respectively, followed by a reduction of 8.82% in the hip region. Interestingly, the hip region showed the smallest reduction, 1.14%, followed by the right (6.12%) and left (8.16%) lower limbs, which, despite reducing, were not as significant as the other body regions described previously.

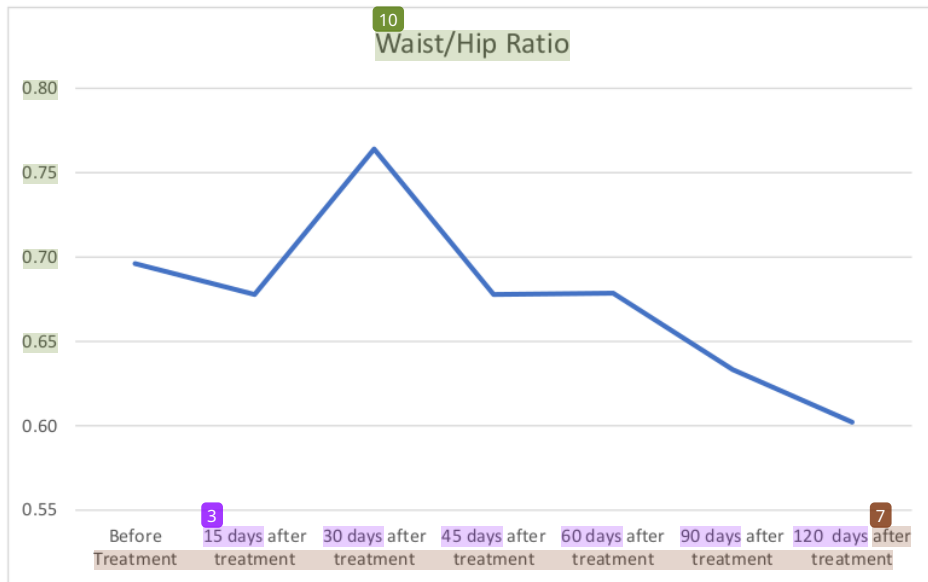


**Graph 1** - Representative graph body weight reduction during the treatment periods evaluated



**Graph 2** - Representative graph referring to body measurements during the treatment periods evaluated

Based on the findings at the end of the treatment protocol, it was possible to identify that the values referring to the waist/hip ratio also showed interesting changes, with a reduction of 13.49% at the end of the treatment (Graph 3).



**Graph 3** - Representative graph of the waist/hip ratio during the treatment period

## DISCUSSION

Cryolipolysis is a technology used worldwide in aesthetic protocols, presenting good results regarding the reduction of localized adiposity (2,8,22) In addition, it is known that previous approaches performed clinically to prepare this patient for exposure to cold, inducing effective thermogenesis, have contributed to achieving body harmonization (23–27). Therefore, the objective of the present study was to evaluate an integrative aesthetic treatment protocol combining different technologies, including cryolipolysis, with the purpose of achieving body harmonization through completely non-invasive methods.

Overall, adaptive thermogenesis is a mechanism activated by brown adipose tissue as a protective mechanism when the body is exposed to intense cold. This type of tissue has an increased metabolic capacity when compared to white adipose tissue, due to its ability to dissipate a greater amount of energy by decoupling mitochondrial respiration from ATP production. However, there was controversy regarding the functionality of this organ in adults, but scientific studies have identified that this type

of tissue, despite being smaller, remains active (10,28–30). Considering this, the frequent activation of this tissue in an appropriate manner contributes to increased energy expenditure, which physiologically triggers increased local fat consumption. Furthermore, an increase in the activity of enzymes belonging to energy metabolism has been identified in immunohistochemical analysis (Hassi, 1997).

This case study identified a significant reduction in localized fat, mainly in the abdominal region. Given the findings, the physiological action mediated by the increase in metabolism in a systemic manner, in addition to the reduction promoted by locally induced cellular apoptosis, is evident. These factors lead to the hypothesis that exposure to cold, on consecutive days in different areas of the body, can significantly increase basal metabolism, with an increase in the use of energy generally produced by the consumption of stored fat, as occurs when the individual is exposed to extreme cold. In addition, local cellular mechanisms also occur concomitantly, with the main mechanism of action being cold-induced panniculitis, which results in cellular apoptosis associated with muscle activation provided by the use of electrostimulation. It is worth noting that some facts are still interesting to highlight in this clinical case, such as the improvement in postural condition and significant retraction of the abdominal region, possibly resulting from the association of electrostimulation for muscle strengthening and hypopressive exercises.

It is already well established in the literature that cryolipolysis enables the activation of this metabolism depending on its therapeutic strategy. Currently, there are possibilities of action with two application modes, cryolipolysis with suction and cryolipolysis of plates. With this, it is easy to expose different body areas. In addition, the author (.....) proposes that the exposure of different body areas on consecutive days of treatment is capable of inducing the desired effects since physiologically the body understands that it needs to activate the metabolism to meet such demand. In addition, it is a technology designed for the permanent reduction of localized fat, since the inflammation called panniculitis promotes cellular apoptosis. In a brief association of these two essential factors, cellular apoptosis and increased metabolism as a whole, a more pronounced reduction of localized fat is hypnotized, which depending on the application strategy can become an interesting non-invasive approach, since it does not require specific monitoring after the procedure.

In turn, electrostimulation is a well-known modality applied in physiotherapy protocols aiming at therapeutic effects such as muscle strengthening, reduction of

edema and pain, tissue repair and reduction of atrophy. Among the existing electrical currents, the *Aussie* current has peculiar characteristics because it is an alternating current with a frequency of 1000 Hz with short bursts in the range of 2 to 4 ms, and is therefore considered more comfortable in terms of patient sensitivity. Electrostimulation is also frequently used in the aesthetic area both to improve muscle tone and to induce lipolysis (31,32).

The last decades have been marked by the association of technology with the aim of expanding clinical results through the specific association of interactions that reach similar pathways, but in different ways. This fact was verified in studies that combined the action of a mechanical wave from therapeutic ultrasound, capable of inducing cavitation in the subcutaneous tissue that leads to lipolysis, with electrostimulation capable of, through its interaction with the cell membrane, also triggering lipolysis in the same application, in addition to helping to increase metabolism through muscle contraction (33).

In addition to the contribution from extrinsic stimuli through the use of different technologies, active muscle activation effectively helps to increase cellular metabolism and maintain its hypertrophy and strengthening. In this sense, the use of hypopressive exercises, through active activation performed by respiratory maneuvers without the need for loads and aimed at increasing the tone of the most intrinsic muscles of the abdominal regions, has been growing in recent years. The benefits of this technique include postural, urinary and sexual improvements, as well as reduced waist circumference and improved respiratory function (Resende et al., 2018). Caufriez et al., (2006), describes the creation of negative pressure within the abdominal cavity, which promotes involuntary activation of abdominal fibers and the pelvic floor. Costa et al., found an improvement in perineal strength after 3 sessions with hypopressive treatments. Jose-Vaz et al., reported a significant improvement in function in UI symptoms and an **improvement in quality of life after 12 weeks** of treatment.

Despite the literature reports proving the positive effects of protocols that use different technologies, it is clear that there is still a large gap to be filled when it comes to the combination of treatments, as well as the integrative vision in aesthetic approaches to achieve results similar to those of invasive surgery. To our knowledge, this is the first scientific case study that addresses different technologies for an integrative therapeutic strategy. In order to construct a clinical protocol like the one used in this study, it is necessary to consider some specific points in the initial

anamnesis, such as the amount of localized fat, type of tissue, areas likely to be exposed to cold, body contour, waist-to-hip ratio, age, lifestyle and postural changes. In order to establish which technological combinations will be indicated, prior biological knowledge of their indications is essential.

In a brief discussion based on the clinical picture discussed in this study, it is possible to inquire that cryolipolysis was the chosen resource to act systemically through thermogenesis and locally directly on the subcutaneous tissue. The association of cold with modulated electrostimulation for muscle strengthening was interesting mainly in the abdominal region to stimulate muscle tone, which together with hypopressive exercises resulted in a significant modification of both posture and stabilization of the abdominal muscles, which associated with the reduction of subcutaneous tissue described above caused a significant modification in the improvement of body contour. After a careful analysis of the metabolic pathways and the clinical result presented, it is possible to conclude that it is possible to achieve clinical results of body harmonization by non-invasive means when using cryolipolysis associated with Aussie current.

## References

1. Krueger N, Mai S V., Luebberding S, Sadick NS. Cryolipolysis for noninvasive body contouring: Clinical efficacy and patient satisfaction. *Clin Cosmet Investig Dermatol*. 2014;7:201–5.
2. Manstein D, Laubach H, Watanabe K, Farinelli W, Zurakowski D, Anderson RR. Selective cryolysis: A novel method of non-invasive fat removal. *Lasers Surg Med*. 2008;40(9):595–604.
3. Nelson AA. Cooling for fat. *Fat Remov Invasive Non-invasive Body Contouring*. 2015;101–19.
4. Stevens WG, Gould DJ, Pham LD, Jimenez Lozano JN. Molecular and Histological Evidence Detailing Clinically Observed Skin Improvement Following Cryolipolysis. *Aesthetic Surg J*. 2022;42(1):56–67.
5. Alizadeh Z, Halabchi F, Mazaheri R, Abolhasani M, Tabesh M. Review of the mechanisms and effects of noninvasive body contouring devices on cellulite and subcutaneous fat. *Int J Endocrinol Metab*. 2016;14(4).



6. Bernstein EF. Longitudinal evaluation of cryolipolysis efficacy: Two case studies. *J Cosmet Dermatol*. 2013;12(2):149–52.
7. Bernstein EF, Bloom JD, Basilavecchio LD, Plugis JM. Non-invasive fat reduction of the flanks using a new cryolipolysis applicator and overlapping, two-cycle treatments. *Lasers Surg Med*. 2014;46(10):731–5.
8. Murphrey M, Garibyan L. Cryolipolysis: The future of cryolipolysis. *J Cosmet Dermatol*. 2023;22(S3):37–47.
9. Palauro CRT. No Title. *J Cosmet dermatology* [Internet]. 2023;1(1473–2165):1. Available from: <https://onlinelibrary.wiley.com/doi/full/10.1111/jocd.16002>
10. van Marken Lichtenbelt WD, Vanhomerig JW, Smulders NM, Drossaerts JMAFL, Kemerink GJ, Bouvy ND, et al. Cold-Activated Brown Adipose Tissue in Healthy Men. *N Engl J Med*. 2009;360(15):1500–8.
11. Scotney H, Symonds ME, Law J, Budge H, Sharkey D, Manolopoulos KN. Glucocorticoids modulate human brown adipose tissue thermogenesis in vivo. *Metabolism* [Internet]. 2017;70:125–32. Available from: <http://dx.doi.org/10.1016/j.metabol.2017.01.024>
12. Carruthers J, Stevens WG, Carruthers A, Humphrey S. Cryolipolysis and skin tightening. *Dermatologic Surg*. 2014;40:S184–9.
13. Finlin BS, Confides AL, Zhu B, Boulanger MC, Memetimin H, Taylor KW, et al. Adipose Tissue Mast Cells Promote Human Adipose Beiging in Response to Cold. *Sci Rep*. 2019;9(1):1–10.
14. Hwang IC, Kim KK, Lee KR. Cryolipolysis-induced abdominal fat change: Split-body trials. *PLoS One* [Internet]. 2020;15(12 December):1–11. Available from: <http://dx.doi.org/10.1371/journal.pone.0242782>
15. Nakhuda A, Josse AR, Gburcik V, Crossland H, Raymond F, Metairon S, et al. Biomarkers of browning of white adipose tissue and their regulation during exercise- And diet-induced weight loss. *Am J Clin Nutr*. 2016;104(3):557–65.
16. Wachsmuth NB, Aberer F, Haupt S, Schierbauer JR, Zimmer RT, Eckstein ML, et al. The Impact of a High-Carbohydrate/Low Fat vs. Low-Carbohydrate Diet on Performance and Body Composition in Physically Active Adults: A Cross-Over Controlled Trial. *Nutrients*. 2022;14(3):1–15.
17. Brobakken MF, Krogsæter I, Helgerud J, Wang E, Hoff J. Abdominal aerobic endurance exercise reveals spot reduction exists: A randomized controlled trial. *Physiol Rep*. 2023;11(22):1–11.

18. Jalian HR, Avram MM. Body Contouring: The Skinny on Noninvasive Fat Removal. *Semin Cutan Med Surg* [Internet]. 2012;31(2):121–5. Available from: <http://dx.doi.org/10.1016/j.sder.2012.02.004>
19. Loap S, Lathe R. Mechanism Underlying Tissue Cryotherapy to Combat Obesity/Overweight: Triggering Thermogenesis. *J Obes*. 2018;2018.
20. Moreno-Muñoz MDM, Hita-Contreras F, Estudillo-Martínez MD, Aibar-Almazán A, Castellote-Caballero Y, Bergamin M, et al. The effects of abdominal hypopressive training on postural control and deep trunk muscle activation: A randomized controlled trial. *Int J Environ Res Public Health*. 2021;18(5):1–13.
21. Kim J, Kim DH, Ryu HJ. Clinical effectiveness of non-invasive selective cryolipolysis. *J Cosmet Laser Ther*. 2014;16(5):209–13.
22. Friedmann DP. Cryolipolysis for Noninvasive Contouring of the Periumbilical Abdomen with a Nonvacuum Conformable- Surface Applicator. *Dermatologic Surg*. 2019;45(9):1185–90.
23. Abboud S, Hachem JP. Heat Shock Lipolysis: Radiofrequency Combined with Cryolipolysis for the Reduction of Localized Subcutaneous Fat. *Dermatol Res Pract*. 2020;2020:14–8.
24. Abdel-Aal NM, Elerian AE, Elmakaky AM, Alhamaky DMA. Systemic Effects of Cryolipolysis in Central Obese Women: A Randomized Controlled Trial. *Lasers Surg Med*. 2020;52(10):971–8.
25. Boey GE, Wasilenchuk JL. Enhanced clinical outcome with manual massage following cryolipolysis treatment: A 4-month study of safety and efficacy. *Lasers Surg Med*. 2014;46(1):20–6.
26. Boey GE, Wasilenchuk JL. Fat reduction in the inner thigh using a prototype cryolipolysis applicator. *Dermatologic Surg*. 2014;40(9):1004–9.
27. Faulhaber J, Sandhofer M, Weiss C, Sattler G, Sadick NS. Effective noninvasive body contouring by using a combination of cryolipolysis, injection lipolysis, and shock waves. *J Cosmet Dermatol*. 2019;18(4):1014–9.
28. Huttunen P, Hirvonen J, Kinnula V. The occurrence of brown adipose tissue in outdoor workers. *Eur J Appl Physiol Occup Physiol*. 1981;46(4):339–45.
29. Himms-Hagen J. Does Brown Adipose Tissue (BAT) Have a Role in the Physiology or Treatment of Human Obesity? *Rev Endocr Metab Disord*. 2001;2(4):395–401.
30. Aherne W, Hull D. The Site of Heat Production in the Newborn Infant. *J R Soc*

Med. 1964;57(12):1172-3.

31. Hamida ZH, Comtois AS, Portmann M, Boucher JP, Savard R. Effect of electrical stimulation on lipolysis of human white adipocytes. *Appl Physiol Nutr Metab.* 2011;36(2):271-5.
32. Ringer E, Russ U, Siemen D.  $\beta$ 3-Adrenergic stimulation and insulin inhibition of non-selective cation channels in white adipocytes of the rat. *Biochim Biophys Acta - Biomembr.* 2000;1463(2):241-53.
33. Laubach HJ, Makin IRS, Barthe PG, Slayton MH, Manstein D. Intense focused ultrasound: Evaluation of a new treatment modality for precise microcoagulation within the skin. *Dermatologic Surg.* 2008;34(5):727-34.

# COMBINED THERAPY: PLATE CRYOLIPOLYSIS AND AUSSIE CURRENT FOR CLINICAL BODY HARMONIZATION PROTOCOL

## ORIGINALITY REPORT

7%

SIMILARITY INDEX

5%

INTERNET SOURCES

5%

PUBLICATIONS

0%

STUDENT PAPERS

## PRIMARY SOURCES

1	<a href="http://classic.clinicaltrials.gov">classic.clinicaltrials.gov</a> Internet Source	1%
2	<a href="http://www.clinicaltrials.gov">www.clinicaltrials.gov</a> Internet Source	1%
3	<a href="http://www.healthproductsforyou.com">www.healthproductsforyou.com</a> Internet Source	1%
4	"XXVI Brazilian Congress on Biomedical Engineering", Springer Science and Business Media LLC, 2019 Publication	1%
5	Montserrat Ponga-Manso. "Ultrasound assessment of abdominal adipose panniculus in patients treated with a single session of cryolipolysis in a clinical setting", Journal of Cosmetic Dermatology, 2021 Publication	<1%
6	<a href="http://www.ncbi.nlm.nih.gov">www.ncbi.nlm.nih.gov</a> Internet Source	<1%
7	<a href="http://slidetodoc.com">slidetodoc.com</a>	

---

Internet Source

<1 %

---

8

[www.hindawi.com](http://www.hindawi.com)

Internet Source

<1 %

---

9

Asma Irshad, Rabia Ismail Yousuf, Muhammad Harris Shoaib, Faaiza Qazi et al. "Effect of starch, cellulose and povidone based superdisintegrants in a QbD-based approach for the development and optimization of Nitazoxanide orodispersible tablets: Physicochemical characterization, compaction behavior and in-silico PBPK modeling of its active metabolite Tizoxanide", Journal of Drug Delivery Science and Technology, 2022

Publication

<1 %

---

10

[d-nb.info](http://d-nb.info)

Internet Source

<1 %

---

11

Patricia Froes Meyer, Rodrigo Marcel Valentim da Silva, Glenda Oliveira, Maely Azevedo da Silva Tavares et al. "Effects of Cryolipolysis on Abdominal Adiposity", Case Reports in Dermatological Medicine, 2016

Publication

<1 %

---

12

[uknowledge.uky.edu](http://uknowledge.uky.edu)

Internet Source

<1 %

13	Internet Source	<1 %
14	<a href="http://www.mdpi.com">www.mdpi.com</a> Internet Source	<1 %
15	<a href="http://www.skinclinicfremantle.com.au">www.skinclinicfremantle.com.au</a> Internet Source	<1 %
16	Joanna Wolska, Haidar Hassan. "Noninvasive lipolysis modalities in aesthetic medicine", <i>Journal of Cosmetic Dermatology</i> , 2023 Publication	<1 %
17	Robert Baran, Howard I. Maibach. "Textbook of Cosmetic Dermatology", CRC Press, 2019 Publication	<1 %
18	Yalong Zhang, Xinyu Du, Chenchen Wang, Gangqiang Zhang. "Tribological properties of titanium alloy with micro-nano multiscale texturing against bone under simulated implant contact conditions", <i>Tribology International</i> , 2024 Publication	<1 %
19	<a href="http://pmc.ncbi.nlm.nih.gov">pmc.ncbi.nlm.nih.gov</a> Internet Source	<1 %
20	<a href="http://s3.amazonaws.com">s3.amazonaws.com</a> Internet Source	<1 %

---

Exclude quotes      On

Exclude matches      Off

Exclude bibliography      On