

1
2
3
4
5
6
7
8
9
10
11
12
13
14
15
16
17
18
19
20
21
22
23
24
25
26

Isolated Tuberculosis of the Wrist : a case report

Abstract :

Osteoarticular tuberculosis accounts for 2-5% of all tuberculosis cases, with vertebral tuberculosis being the most frequent localization (50%). Peripheral joint involvement comes second, mainly affecting weight-bearing joints (hip and knee); wrist involvement is rare (< 1%). We report a case of a 42-year-old female with a history of pulmonary tuberculosis treated 10 years ago, presented with an isolated right hand swelling for a 4-month duration. His initial imaging and CT scan showed multiple destructive lesions in the carpal bones associated with multiple fluid collections, His histology and microbiological studies were positive for TB with no other concurrent evidence of TB elsewhere.

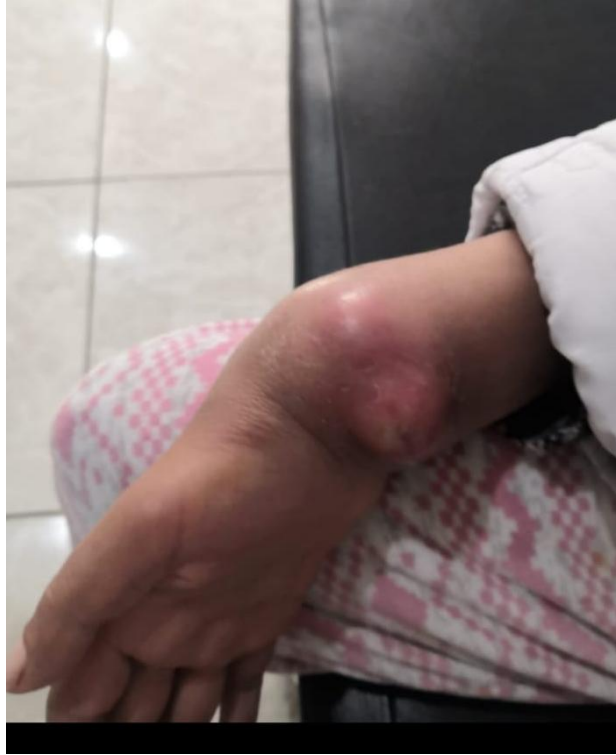Keywords : wrist , tuberculosis , carpal bones

Introduction :

Osteoarticular tuberculosis (OAT) accounts for 2-5% of all tuberculosis cases, and 11-15% of extra-pulmonary cases (1). The main site is vertebral tuberculosis, which accounts for at least 50% of cases. Peripheral articular tuberculosis comes second, mainly affecting weight-bearing joints (hip and knee); osteoarthritis of the wrist is rarer.

Case report :

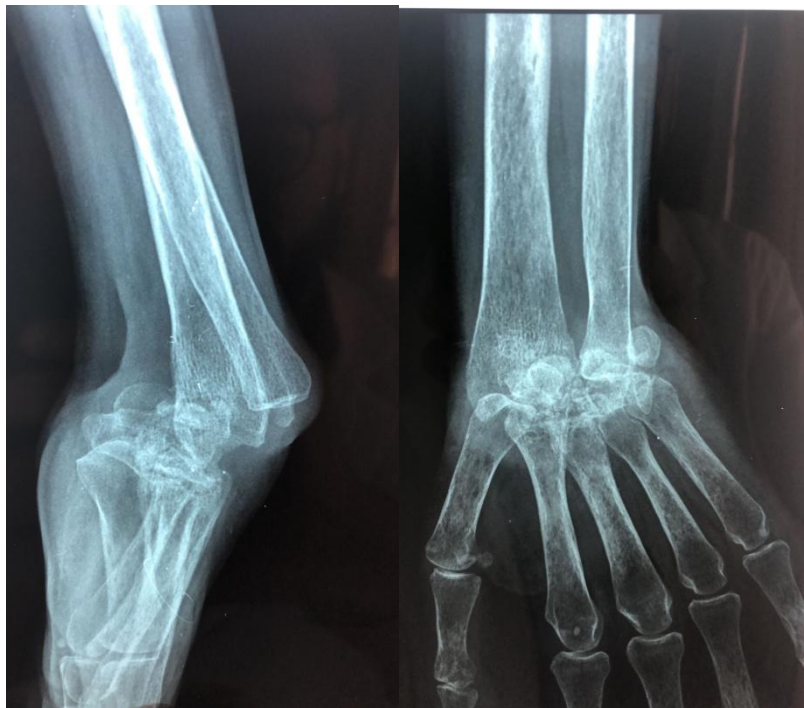
A 42-year-old female with a background history of diabetes and hypertension for 14 years presented with right side (non dominant) isolated hand swelling for a 7-month. Its progressive enlargement was associated with pain and restriction of movements. There were no other small or large joint symptoms. she did not have episodes of fever, and he maintained good physical well-being in terms of appetite and weight. She has past history of pulmonary tuberculosis 10 years ago. The physical examination founded a swelling right wrist with a obvious deformity , associated with multiple sub cutaneous collections with inflammatory sign (Figure 1) Flexion extension and circumduction movements were reduced.



27

28 Figure 1 : clinical image showing swelling wrist associated with inflammatory signs

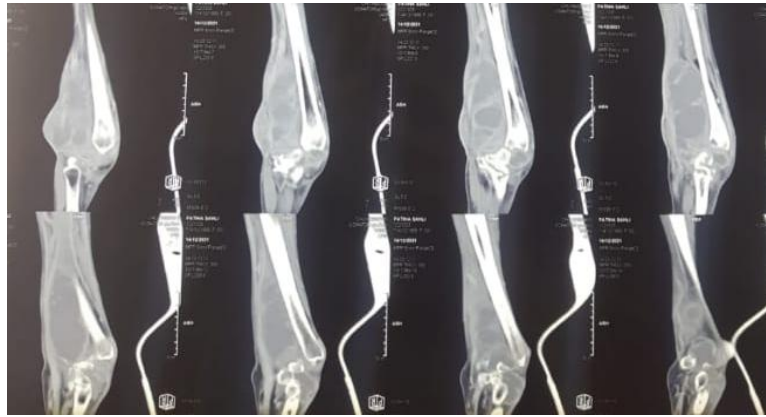
29 Initial digital X-ray (Figure 2) of the hand showed destructive type lytic lesions involving
30 mainly the carpal bones , a CT scan of the wrist (figure 3) was performed showed a total
31 destruction of carpal bone and volar dislocation of the wrist associated with multiple
32 collection in the volar aspect of the wrist with intra-articular extension.



33

34

Figure 2 : x rays showing total destruction of carpal bones



35

36

Figure 3: sagittal Ct scan of the wrist showing multiple collection

37

38

39

40

41

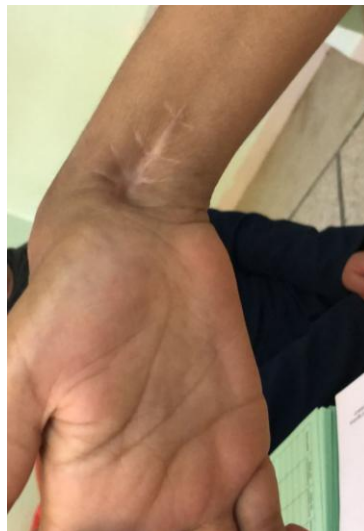42

The patient was admitted to operation room and Under general anesthesia and using a Henry approach debridement and curettage of the right wrist were performed. The purulent discharge was connected to the the subcutaneous layer at the ulnar border and involved the carpal tunnel. Carpal tunnel release was also performed for the eradication of necrotic tissue in view of the extension of the infection. The carpal bones were eroded and fragmented. The wrist was immobilized using a thermoplastic splint postoperatively.

43

44

Upon follow-up at six weeks, the wound was completely healed (figure 4) and the patient refused further surgical interventions.



45

46

Figure 4 : wound healed

47

Discussion :

48

49

50

Osteoarticular tuberculosis is classically divided into four main types: spinal involvement (the typical form of which is pott's sore), peripheral arthritis and tuberculous osteoarthritis, osteomyelitis, and tenosynovitis and bursitis (2).

51

52

The spine is the most commonly affected site in 50 to 60% of cases, with arthritis and osteoarthritis coming second and predominating in the lower limbs, which are affected in 60

53 to 80% of cases. In the upper limbs, the shoulder (4-11%) and the elbow (5-15%) may be
54 affected (1). Localization of tuberculosis to the hand is a rare entity (3), occurring in only 2%
55 to 4% of osteoarticular tuberculosis cases (4), wrist involvement is much rarer <1% (5, 6).
56 Tuberculosis of the wrist is often associated with another site. It is a chronic condition with a
57 slow, insidious course, often leading to delayed diagnosis (6).

58 Plain radiography of the wrist and chest is needed to establish the diagnosis appropriately.
59 Typically, plain radiography shows sclerosis and osteolytic lesions in the bones involved.
60 This is nonspecific and can be present in conditions such as pyogenic osteomyelitis,
61 inflammatory arthritis, and malignancy (7). Sometimes, this condition can be misleading as
62 patients also have bone destruction similar to that which can be found in that particular
63 disease, whereas chronic bone infection should have sequestrum, involucrum, and cloaca in
64 the radiograph six weeks or more following acute osteomyelitis (8). CT and MRI scans are
65 also nonspecific. However, they are useful in determining the extent of the swelling. In this
66 case, we used ultrasound to evaluate the extent of the swelling since the consistency was
67 fluctuant and there was purulent discharge on wrist movement.

68 The diagnosis can be confirmed by recognition of *Mycobacterium tuberculosis* in cultures and
69 a histological pattern that is typical for tuberculosis. This is usually described as necrotizing
70 granulomatous inflammation composed of epithelioid histiocytes surrounding a central
71 necrotic zone with multinucleated giant cells and lymphocytes (9)

72 Treatment of tuberculosis is generally non-operative and involves a combination of anti-
73 tuberculous medications that consist of a two-month-long intensive phase using a combination
74 of rifampicin, isoniazid, ethambutol, and pyrazinamide followed by a continuation phase of
75 rifampicin and isoniazid for another four months, as suggested by the World Health
76 Organization in 2017 (10)

77 Surgical treatment is mainly reserved for abscesses, nerve compressions, and reconstructive
78 options in wrist and hand involvement by tuberculosis

79 Conclusion :

80 Tuberculosis is still a major healthcare burden that needs medical professionals' attention.
81 The knowledge on tuberculosis and its different presentations is important to arrive at a
82 diagnosis especially with its extrapulmonary involvement. Tuberculosis is a rare cause of
83 chronic inflammatory swelling of the hand, but it should be considered in African countries
84 where the disease prevalence is high

85

86

87

88

89

90 References :

91

92 1. Pertuist E. Tuberculose ostéoarticulaire extravertébrale. Rev Rhum 2006 ; 73 : 387-93.

93 2. Boussel L, Marchand B, Blineau N, Pariset C, Hermier M, Picaud G, Emin M, Coulon
94 A, Pagnon P, Rode A, Pin-Leveugle J, Boibieux A, Berthezène Y. Imagerie de la
95 tuberculose ostéoarticulaire. J Radiol 2002 ; 83: 1025-34. 3.

96 3. Benkeddache Y, Sidhoum SE, Derridj A. Les différents aspects de la tuberculose de la
97 main (45 cas). Ann Chir Main 1988 ; 7 : 166-75. 4.

98 4. Dumontier C, Maylin V, SautetA, Lenoble E, Urban T, Apoil A. Rupture à la paume
99 des tendons fléchisseurs d'origine tuberculeuse. Rev Chir Orthop 1996 ; 82: 668-71.

100 5. 5. Bodur Hu, Erbay A, Bodur Ha, Yilmaz O, Kulacoglu S. Multifocal tuberculosis
101 presenting with osteoarticular and breast involvement. Ann Clin Microbiol Antimicrob
102 2003 ; 2 : 6.

103 6. Benchakroun M, El Bardouni A, Zaddoug O, Kharmaz M, El Yaacoubi M, Ouadghiri
104 M, El Manouar M. Tuberculose du poignet : symptômes et évolution de 11 ans. Rev
105 Chir Orthop 2004 ; 90 : 337-45.

106 7. Spiegel DA, Singh GK, Banskota AK: Tuberculosis of the musculoskeletal system.

107 Tech Orthop. 2005, 20:167-178. 10.1097/01.bto.0000167745.24646.dc

108 8. Chuah SK, Bajuri MY, Mohd Nor F: Chronic osteomyelitis revisited: a case report
109 Cureus. 2019, 11:e5023. Accessed: May 3, 2020:

110 9. Mustafa Karakaplan, MD Muhammed Koroğlu, MD Zeynep Maraş Özdemir, MD
111 Kadir Ertem, MD: Isolated Tuberculosis of capitate and triquetrum. J Wrist Surg.
112 2017, 6:70-73.

113 10. Guidelines for treatment of drug-susceptible tuberculosis and patient care (2017
114 update). (2017). Accessed: April 9,
115 2020: https://www.who.int/tb/publications/2017/dstb_guidance_2017/en/.

116

117

118