



Journal Homepage: - www.journalijar.com
**INTERNATIONAL JOURNAL OF
 ADVANCED RESEARCH (IJAR)**

Article DOI: 10.21474/IJAR01/7723
 DOI URL: <http://dx.doi.org/10.21474/IJAR01/7723>



RESEARCH ARTICLE

EFFECT OF VARIOUS ROUTES OF ADMINISTRATION OF METHYL PREDNISOLONE ON SWELLING, TRISMUS AND PAIN IN IMPACTED MANDIBULAR THIRD MOLAR SURGERY.

Amartya Prakash Srivastava, Ravinder Singh Bedi, Jitender Kumar Aurora, Puneet Wadhvani, Himanshu Chauhan, Aprajita Srivastava and Shrikant Chakrawarti.

Manuscript Info

Manuscript History

Received: 21 July 2018

Final Accepted: 27 August 2018

Published: September 2018

Keywords:-

Impacted lower third molars, masseter muscle, methylprednisolone..

Abstract

Aim: The post-surgical sequelae like swelling, trismus and pain are often encountered when impacted mandibular third molars are extracted surgically. The study was aimed to evaluate the efficacy of three specific routes of administration of 20 mg methylprednisolone as a single dose with respect to control group, considering the above mentioned complications.

Methods: This study included 12 patients in each group (total 48 patients) undergoing surgical extraction with respect to mandibular third molar. All patients were randomly assigned among four groups as: Group I (control; no steroids), Group II (Intramuscular Injection of steroids). Group III (Intra venous injection) and Group IV (oral tablets). In group II, patients were administered 20mg methyl prednisolone acetate in masseter muscle through intra-oral approach. In group III, intra venous administration was done by injecting 20 mg methylprednisolone succinate. Oral administration of methyl prednisolone Tab 20 mg was done in group IV while group I received no steroids. Apart from control group, each group was administered 20 mg of drug via above mentioned different routes one hour preoperatively as a single dose. All three parameters were assessed and tabulated.

Results: The patients who were administered methylprednisolone preoperatively, showed superior effects with respect to swelling, trismus and pain than control group.

Conclusion: The study concluded that pre-operative administration of 20 mg of methylprednisolone via any route is found to be more effective than postoperative administration however intramuscular route seems to be more efficient than other routes.

Copy Right, IJAR, 2018,. All rights reserved.

Introduction:-

Studies indicate that with progression of age, mandibular third molars get more difficult to remove or may take longer time for its removal, leading to increased risk for complications associated with its extraction. Age of 25-30 years is reported in a few studies to be a critical time, before which extraction is indicated to avoid post-operative residual pocket formation especially in cases of horizontally impacted molar¹.

Therefore American Association of Oral and Maxillofacial Surgeons (AAOMS) favors for surgical management of erupted and impacted third molar teeth firmly, despite the teeth are asymptomatic².

Extraction of third molar by surgical approach is very common procedure performed by maxillofacial surgeons. Swelling, trismus and pain are contemplated as transient postoperative complications regarding this procedure as soft tissue and hard tissue both undergo violation followed by release of inflammatory mediators.

Corticosteroids inhibit phospholipase A2 enzyme, which diminishes arachidonic acid release. Thus, prostaglandins and leukotrienes are less synthesized along with reduction in accumulation of neutrophils (Hirschman 1986).

Traditionally, dexamethasone and methylprednisolone are more often used as they are 4–5 times more efficacious than the natural compound cortisol and can be administered orally or IM or IV.

Methylprednisolone possess least mineralocorticosteroid activity and attains a therapeutic plasma level within initial postoperative days and have been utilized in different molecules, vivid dosages, routes and time of administration.

Only a few studies have been done for efficacy comparison of methyl prednisolone when administered alone by various routes. While many studies have documented the use of 40–80 mg methylprednisolone, we administered methylprednisolone 20 mg considering the adverse effects found in these studies. Present study aimed to weigh the efficacy of methyl prednisolone on swelling, pain and trismus on peculiar days following mandibular impacted third molar extraction.

Material and Methods:-

This study was a randomized, prospective, and controlled study. The patients reporting to outpatient department of Oral and Maxillofacial Surgery, Saraswati Dental College & Hospital, Lucknow (U.P) between January 2016 to November 2017; in whom surgical removal of impacted mandibular third molar was indicated, were thoroughly assessed in terms of inclusion and exclusion criteria. Among the patients who satisfied the criteria, a total number of 48 patients were randomly selected. Individuals of both genders of age group between 18-45 years were selected irrespective of their religion, cast, race or socioeconomic status.

Healthy patients aged between 18 to 45 years devoid of systemic disease having impacted lower third molars with any combination of class I, II position A and B(as per Pell–Gregory classification) were included.

Patient having any medications (Erythromycin, Clarithromycin, or Troleandomycin) that could interfere with methylprednisolone, adverse habits like smoking and conditions like pregnancy or lactation were not included in the study.

This study was undertaken after obtaining approval from the “Institutional Research and Development Committee” and “Institutional Human Ethical Committee” of Saraswati Dental College & Hospital Lucknow. All selected patients were informed about the purpose and experimental nature of the study. A written informed consent was obtained from the study subjects for participation in the study. General health of the patients was evaluated by taking detailed history, thorough clinical examination, hematological and radiological investigations preoperatively. Patients were picked randomly and recruited among four groups.

Thus 12 patients constituted as group I or control group. In the same fashion, 3 study groups of 12 patients each were assigned and termed as group II, III, and IV respectively in following manner. **Group I- Control group-** In this group, steroids were not administered. **Group II- IM group-**In this group, 0.5 ml of 40mg/2ml methyl prednisolone acetate; constituting 20mg was administered in masseter muscle via intra-buccal approach 1 hour pre operatively. **Group-III-I.V group** In this group, Intra venous administration was done by injecting 0.5 ml of 40mg/2ml methylprednisolone succinate constituting 20mg, one hour before the procedure. **Group IV- Oral group-** In this group, oral administration of methyl prednisolone Tab 20mg 1hour before procedure as a single dose was done.

Pain was evaluated using a 15cm long handmade numeric and pictorial visual analogue scale (VAS) ranging from 0 to 10 indicating no pain to worst pain respectively.

Maximal inter incisal opening was evaluated by measuring the gap between incisal edges of upper & lower central incisors at unassisted full mouth opening using carbon fiber composite made digital vernier's caliper (Accuracy 0.1mm or 0.01 inch, noncontact linear CAP measuring system with LCD display CR20323V/SR44/LR44)

Swelling was evaluated using mean of 2 facial lines-(Fig 1)

1. Distance from lower border of tragus to the soft tissue pogonion (T-P)
2. Distance between external canthus of eye to the gonion angle (C-G)

All three parameters were assessed for each patient on pre-operative, 1st, 3rd, 7th and 14th post-operative days respectively.

In patients of Intramuscular group; drug was administered using 2ml syringe fitted with 24 gauge needle. Injection was given into the mid-region of the masseter muscle, in such a manner that the syringe being above and parallel to the occlusal surfaces of the mandibular molars. In patients of I.V group, methylprednisolone succinate was administered in subclavian vein considering antecubital fossa.

All the patients were given pre medication (Tab. Amoxicillin with clavulanic acid 625 mg) a night prior as per the requirement. Patients were told to gargle with 0.2% chlorhexidine gluconate mouthwash for 2 minutes prior to administration of local anaesthesia.

Local anaesthesia was attained by administering 2% lignocaine hydrochloride with adrenaline (1:200000) as inferior alveolar nerve block supplemented by lingual and long buccal nerve block.

Ward's incision was marked and placed. To raise a full thickness mucoperiosteal flap. The buccal guttering was initiated at a fixed RPM under copious irrigation using 0.9% normal saline followed by elevation of impacted tooth. Extraction process was completed using extraction forceps. The socket was then curretted and the bony spicules, if any, were removed. Socket was irrigated with povidone iodine diluted in normal saline (1:4). Primary closure was achieved by 3-0 round body black braided silk. All patients received standard post-operative instructions.

Antibiotics (Tab Amoxicillin and clavulanic acid 625mg/eight hourly) and 2 Tabs of Ketorol-DT 10 mg (12 hourly) were prescribed for 5 days. Patients were advised to rinse after every meal with 0.2% chlorhexidine gluconate solution. Intra oral sutures were cut and removed on 7th post-operative day. To eliminate the surgeon's bias, all the procedures in all patients were performed by the same surgeon.

Statistical Analysis:-

All collected data in this study were analyzed using descriptive statistics and making comparisons between two groups of treated patients, with respect to various parameters. Categorical (discrete) data was summarized in form of proportions, percentages (%) and Mean \pm SD (standard deviation). Data analysis and statistical analysis was done with Statistical Package for Social Sciences (SPSS version 17.0 for windows) & MS Office Excel software for windows. The following statistics were calculated in the present analysis: The chi square test was used to find association between categorical variables.

The one-way analysis of variance (ANOVA) was used to evaluate any significant differences among the means of various (more than two) independent groups. Bi-group comparisons were performed by Tukey HSD (honest significant difference) test. The level of significance was set as $P < 0.05$ for each parameter.

Results:-

The mean age of control group patients, IM group patients, IV group patients and oral group patients was 26.33 ± 8.57 years, 26.50 ± 5.85 years, 26.08 ± 7.43 years and 27.17 ± 6.66 years respectively. According to ANOVA-test no statistical significant difference ($p=0.985$) was found among the mean ages of the groups. Hence the age of the selected subjects was almost indifferent for each group.

The female –male ratio of the control group, IM group, I.V group and Oral group was 41.7: 58.3 %, 25.0: 75.0%, 25.0 : 75.0% and 33.3 : 66.7% respectively. On application of chi square test, no significant difference was found in

the female-male ratio among the four groups ($p=0.785$) statistically. Hence the subjects selected were gender matched for the four groups.

The mean difficulty index of control group patients, IM group patients, I.V group patients and Oral group patients was 3.92 ± 0.67 , 4.83 ± 1.59 , 4.83 ± 1.27 and 4.58 ± 1.17 respectively. On applying ANOVA-test, no statistical significant difference ($p=0.223$) was found among the mean difficulty indices of the groups. Hence the subjects selected for the four groups had same level of difficulty regarding extraction.

Swelling, Trismus and Pain:-

In our study on 1st and 3rd postoperative day, statistically significant reduction of swelling with respect to control group was observed among all the study groups. However the mean increase in swelling on 1st and 3rd postoperative day was least in IM group whereas it was profound in control group. On 7th postoperative day, the mean increase in swelling was least in IV group whereas prominent in control group. Rest of the intragroup comparison revealed no statistical difference in reduction of edema (Tab 1).

The interincisal opening decreased on 1st, 3rd, 7th postoperative day in all groups. However the magnitude of reduction in mean mouth opening was statistically significant in only IM group patients on 1st postoperative day. The decrease in the mean mouth opening on 3rd post op day was most prominent in control group and was least in IM group. On 7th, and 14th postoperative day rest of the intragroup comparison revealed no statistically significant discrepancy in terms of mean mouth opening (Tab 2).

The postoperative pain was less in study group as compared to the control. On first postoperative day, there was marked increase in pain in patients of control group whereas least pain was reported in IM group which was statistically significant. However there seemed to be no statistical difference in post-operative pain among all the four groups on the 3rd and 7th day. Although IM administration seemed to be comparably more efficacious than other routes in reduction of post-operative pain but the difference was statistically insignificant. On 14th postoperative day in our study, with respect to control group, all other groups proved to be better in terms of mean pain score while IM, IV and Oral group provided almost similar results (with a negligible difference of 0.08 on VAS score). It may be due to shorter half-life as well as single dose of the drug. (Tab 3)

Discussion:-

Swelling

Postsurgical edema is tough to quantify appropriately because it entails three dimensions of measurement with an convex and uneven surface, and might manifest itself internally and externally. As subjective observation is concerned, lean patients seem to have extra swelling than sufferers who are "plump," "stout," or overweight (Messer and Keller⁴). They also stated that redheaded, blonde, and fair-skinned patients are more prone for swelling as compared to dark-complexioned patients.

Hupp J.R.et al.³ noted that oedema is variably distributed and it accumulates towards loose connective tissues whereas least occurs in tightly bound tissue structures.

Surgical expertise and level of difficulty are recognized as deciding factors in the occurrence and severity of postoperative complications including edema. (Hupp JR³, Peterson LJ, Sisk AL⁵, MacGregor AJ⁶, Laskin DM). Surgical difficulty among all four groups was statistically insignificantly ($p=0.223$) in our study.

The precise duration of edema in response to surgical procedure in oral and maxillofacial region is not well documented and is probably variable for each patient and procedure. Laskin states that edema is maximum on 24 to 48 hours, but Peterson says it is maximum on 48 to 72 hours and usually resolves after 7 days. He further stated that any swelling after operation which keeps on expanding after 3 days, is not postoperative swelling but it may be associated with infection.

A time span of 2 to 3-days is most frequently cited and is consistent with various published studies. Huffman et al⁷ reported a statistically significant reduction in edema in patients who were administered 125 mg of intravenous methylprednisolone immediately before surgery, but after 7 days there was no difference noted.

Hargreaves and Costello observed 62% reduction in release of immune reactive bradykinin, 3 hours after surgery when 125 mg of methylprednisolone was used.

Pedersen A et al⁸ noted a 50% depletion in swelling on the second postoperative day when 4 mg of intramuscular dexamethasone was used but no significant difference on the seventh postoperative day was noted.

When a single dose of 20 mg methylprednisolone was used preoperatively, Milles and Desjardins⁹ noted a 42% reduction in swelling on the first postoperative day, 34% less on the second, but only 19% less on the third postoperative day.

Various studies have used various methods for the measurement of oedema, like computed tomography, malleable metal rods, etc. Other modalities like clinical observation, subjective palpation, compass, photographic techniques, stereophotography has also been applied to assess the amount of swelling. Actually each method has its own pros and cons.

According to Emin Esen et al¹⁰ ultrasound and CT are among the most accurate diagnostic techniques. These techniques made it possible to perform precise measurements of the facial soft tissues. However, during examination of the soft tissue with ultrasound, some alterations can occur in the measurement because the transducer is applied with a slight pressure.

The method we used in our study to measure facial swelling (stickers and silk thread embedded with stoppers) is a modification of Mastumara et al¹¹ It is also easy to use, inexpensive, valid and convenient for repeatability of the method.

Our study demonstrated similar findings where postoperative edema was consistent till 3rd postoperative day among all four groups and the results were highly significant ($p < 0.001$), however all groups (IM, IV and oral) were significantly efficacious in reducing postoperative edema on 1st and 3rd postoperative day as compared to the control group. But no significant difference among all four groups was noted on 7th and 14th postoperative days in intra group comparison.

Trismus

In this study, we have preferred to use digital vernier caliper over mechanical caliper owing to its better accuracy. The mean reduction in inter-incisal opening on first post-operative day for all three groups of methylprednisolone was observed to be 14.83 % as compared to control group.

Statistically significant findings have been documented when corticosteroids are used in combination with drugs like Diclofenac potassium for reducing pain and swelling, but not in reference to trismus by Bamgbose BO et al¹²

López-Carriches C et al²⁶ in his study using methylprednisolone and diclofenac, concluded that the trismus may retain for up to 10 days after surgery.

In studies of Moore et al¹³, Mico-Llorens et al¹⁴, Graziani et al¹⁵ and Buyukurt et al¹⁶ in 2006, Zandi et al¹⁷, Vegas-Bustamante et al¹⁸ and Laureano Filho et al¹⁹ in 2008, Chopra et al³³ in 2009, corticosteroid was found to be significantly effective in reduction of postoperative trismus on 2nd postoperative day (p value below 0.05) while on the 7th post op day there was no statistical difference observed. Similarly, in our study, statistically significant difference was observed in reduction of postoperative trismus on the first postoperative day ($p=0.048$) but no statistically significant difference was noted on 7th postoperative day ($p=0.811$).

In a study performed by Vaibhav et al²⁰, where he compared the efficacy of intravenous, intramuscular (in masseter muscle), submucosal and oral routes of administration of 20 mg methylprednisolone for decrease in postoperative trismus in patients undergoing lower 3rd molar surgery. He found no statistically significant difference in mean inter incisal opening on 2nd and 7th postoperative day ($p = 0.37$), ($p = 0.29$) while in our study, intra group comparison showed statistically significant difference ($p=.048$) in mean inter incisal opening on the 1st postoperative day. Although no significant difference was noted on the 3rd, 7th and 14th postoperative day among all groups however inter group comparison showed intramuscular route to be significantly ($p = .044$) more efficacious in reducing

trismus on 1st postoperative day. Whereas all routes of administration showed no significant difference when compared to the control group on 3rd, 7th and 14th postoperative day.

In a study done by G. Koger et al²¹ it was observed that mouth opening following the masseter injection, i.v. injection and oral tablet of methylprednisolone on postoperative days 2 and 7 was significantly greater than in the control group ($P < 0.05$). Among the groups, mouth opening was greater in the i.v. injection group compared to the oral tablet and masseter injection groups on day 2, although the results were statistically insignificant ($P > 0.05$). In our study, it coincides with results of first postoperative day where all groups were significantly efficacious in improving postoperative mouth opening when compared to control group in which inter incisal opening was significantly reduced ($p=0.048$) whereas no statistical difference among all groups was noted on 3rd, 7th and 14th postoperative days.

In terms of postoperative inter incisal opening intra group comparison exerted no significant difference among all four groups, whereas inter group comparison between IM and control group on the first day after surgery; was proved to be statistically significant ($p=0.044$), however both IV and oral group seemed comparably efficacious in improving postoperative trismus when compared to control group but the result was statistically insignificant. However similar to the results of study by G. Koger et al²¹ our study also showed no statistical difference among all corticosteroid groups on 3rd, 7th and 14th postoperative days.

Chugh et al²² suggested that probably steroids play a role in prevention of trismus. But it was because of the direct impact of steroid or was a result of reduction in swelling needs verification.

On 7th day of surgery, swelling and trismus had back to baseline levels among all groups, indicating that the advantage of the medicine turned into at a maximum on initial 3 postoperative days.

Our study also correlates as trismus and swelling almost returned to baseline on 7th postoperative day in all four groups and the difference between them was statically insignificant.

All the groups were almost similar in their efficacy to reduce postoperative trismus on the 3rd, 7th and 14th postoperative day, which could be attributed to administration of postoperative analgesic Tab Ketorol-DT for 5days in our study. As it has already been stated by Moore PA et al⁹⁸ in their study that trismus is partially associated with postoperative pain.

Pain

Postoperative pain and oedema are maximum around 48–72 h after surgery. The usage of corticosteroids to prevent postoperative pain is controversial. Some studies suggest that the swelling makes the tissue tense and ultimately causes tension pain, while reduced when swelling is reduced by the steroids (A. Chugh et al²³).

Actually Pain is a subjective sensation which can be influenced by plethora of factors like patient's anxiety age, gender, and surgical difficulty (Capuzzi P et al²³).

One study suggests the possibility of CS treatment to increase patient's reaction to pain, as a result of suppression of endorphin β levels. Koger et al²¹ in his study using 20 mg of methylprednisolone neither measured nor compared pain probably due to subjective nature of pain sensation.

Vegas-Bustamante et al¹⁸ evaluated the effect of a 40-mg injection of methylprednisolone within the masseter muscle considering oedema, trismus, and pain, following third molar surgery. They discovered that pain and swelling both were markedly reduced on 2nd and 7th postoperative days in study group with respect to control group. However, they concluded that pain being subjective in nature, an objective result should not be observed. Therefore they did not considered pain during the study (Vegas Bustamante²⁹ 2008). Our results also show the same thing.

A number of authors have reported a statistically significant reduction ($p < 0.05$) in pain after the postoperative administration of CS (Micó-Llorens JM et al¹⁴, Buyukkurt MC et al¹⁶ Chopra D et al²⁴). These results were formulated using 40 mg of methylprednisolone (Micó-Llorens JM et al¹⁴), 25 mg prednisolone (Buyukkurt MC et al¹⁶) or 0.5 mg of betamethasone (Chopra D et al²⁴).

Ustun et al²⁵ weighed the efficacy of 1.5 and 3 mg/kg of methylprednisolone via the i.v route and found that these doses were insufficient to afford significant pain reduction.

A study involving three groups of patients (control and the administration of 10 and 20 mg of prednisolone) presented insignificant differences in pain among the groups (Kang SH et al²⁶).

In our study, we observed statically significant mean difference in post op pain among all four groups ($p=0.010$). On first post op day, there was marked pain increase in control group whereas least pain was reported in IV group.

Intra-group comparison of mean pain score at 3rd day was done between the groups. There was no significant difference in mean pain score between control, IM, IV and oral group ($p=0.119$) the result of our study was similar to results in study of Vaibhav et al²⁰.

Intra-group comparison of mean pain score at day 7th was also done. Although there was marked increase in pain reported by the patients of control group and least in IM group, there was no statistically significant difference in mean pain score between control, IM, IV and oral group ($p=.270$). Our results somewhat differed from results of Vaibhav et al²⁰ as the mean pain score was significantly different on 7th postoperative day.

On 14th post op day in our study, with respect to control group, all other groups proved to be better in terms of mean pain score while IM, IV and Oral group provided almost similar results (with a negligible difference of 0.08 on VAS score). It may be due to shorter half life as well as single dose of the drug.

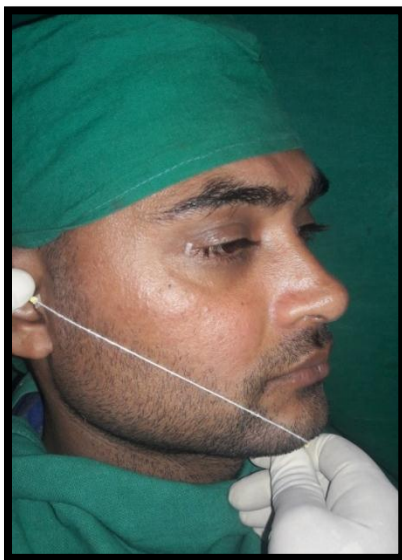In a study done by Jorge Chaurand Lara et al²⁷ with 20 mg methylprednisolone, significant decrease in pain and swelling was observed just after surgery on first operative day. Other authors like Majid O W et al²⁸ and Nupert III et al²⁹ (although used dexamethasone) also concluded similarly. So results of our study corroborate with their results.

Conclusion:-

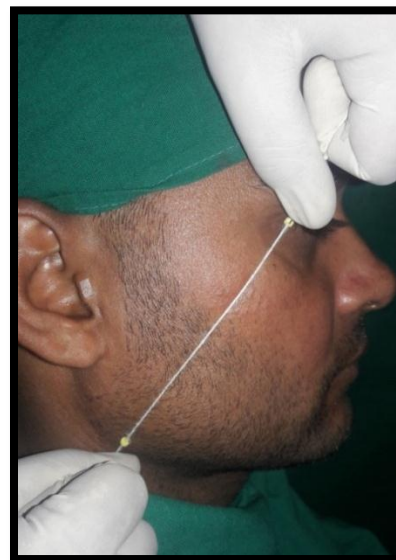Our study indicates that an intramassetric injection of methylprednisolone is most effective in reducing postoperative sequelae because it acts as a depot. Further studies with larger samples are needed to obtain more reliable results and to minimize these undesirable effects among patients.

Competing Interests

Author has no acknowledged conflicts of interest regarding this publication.

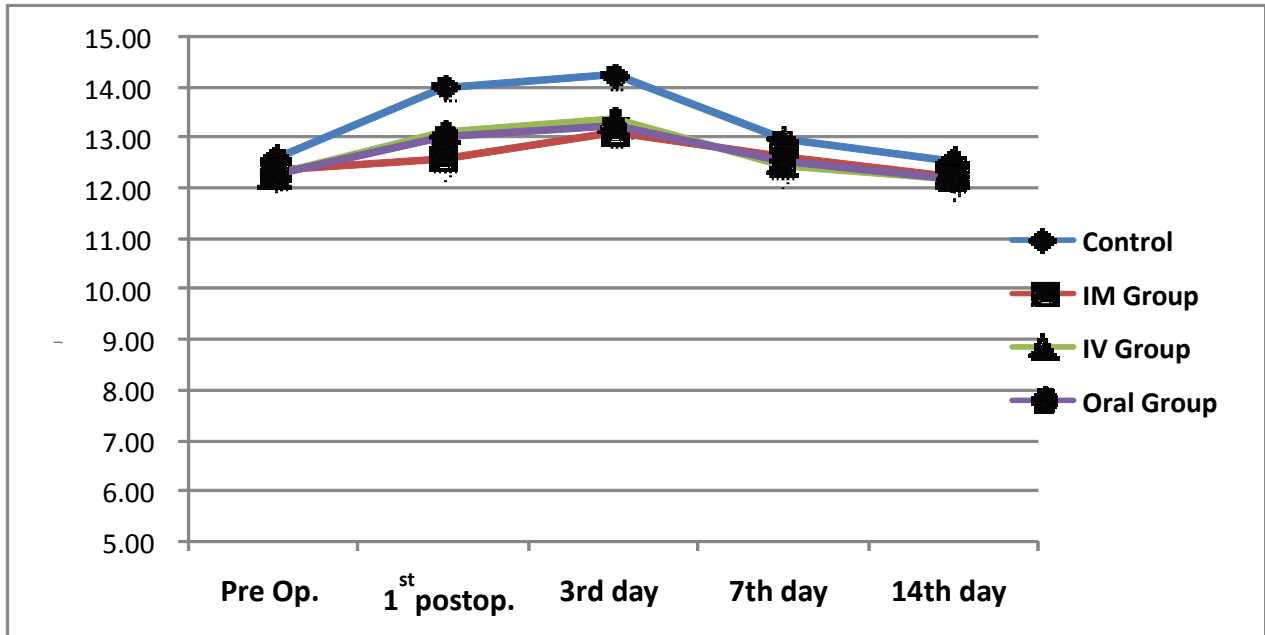


Tragus to Pogonion (T-P)

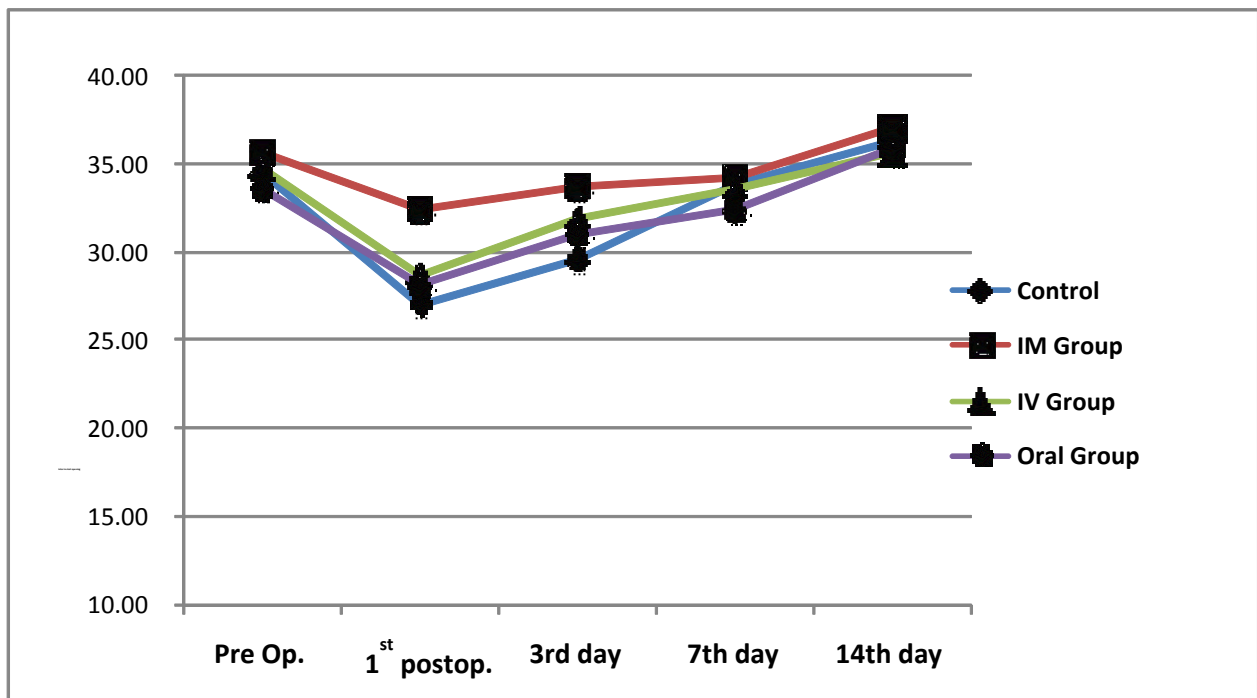


Lateral canthus to gonion (C-G)

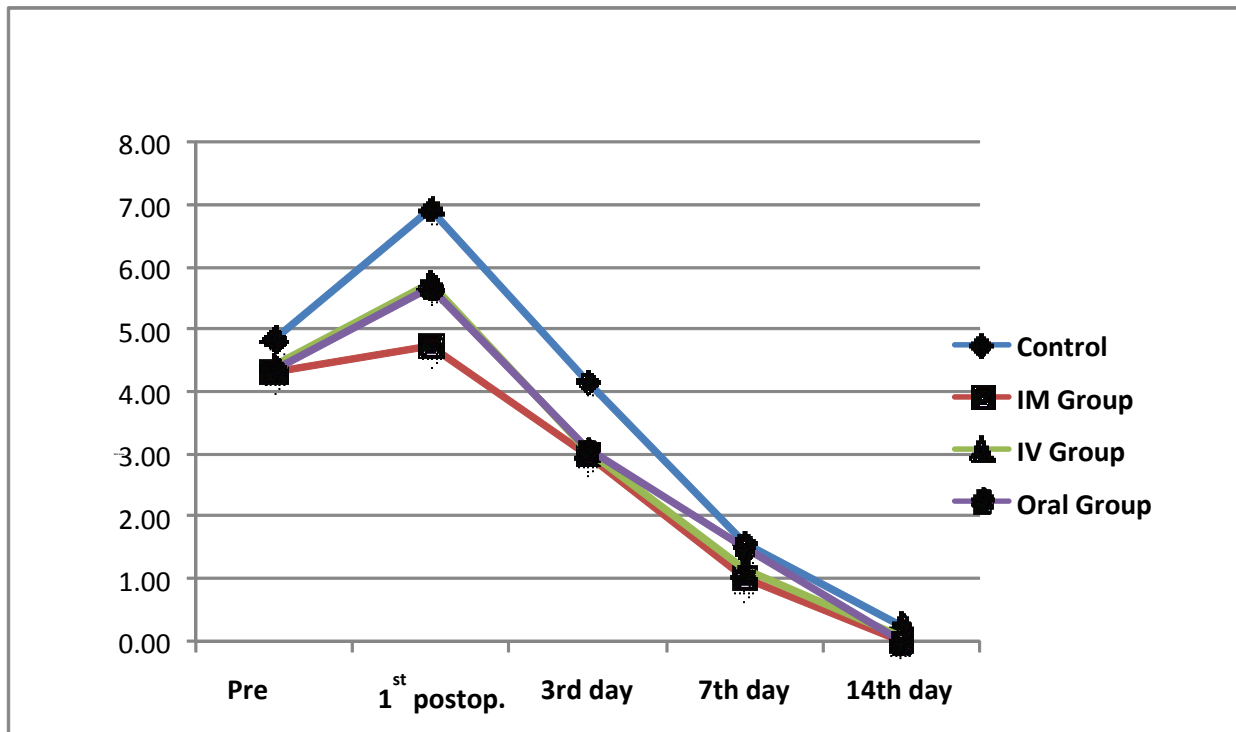
Fig 1:-Measurement of swelling using facial landmarks using thread and stopper



Tab 1:-Comparison of Swelling among the groups at various follow ups:-



Tab 2:-Comparison of Inter-incisal opening among the groups at various follow ups



Tab 3:-Comparison of pain score among the groups at various follow ups

Reference:-

1. Kugelberg CF, Ahlström U, Ericson S, et al: Periodontal healing after impacted lower third molar surgery in adolescents and adults. A prospective study. *Int J Oral Maxillofac Surg* 20:18, 1991
2. Evidence Based Third Molar Surgery, *journal of AAOMS*, November 10, 2011
3. Hupp JR. Principles of surgery. In: Peterson LJ, Ellis E, Hupp JR, Tucker MR, editors. Contemporary oral and maxillofacial surgery. 3rd ed. St Louis: Mosby; 1998. p. 56.
4. Eugen'e J. Messer and John J. Keller, Great Lakes md Libertyzqille, Ill, The use of intraoral dexamethasone after extraction of mandibular third molars, *Oral Surg*. November, 1975
5. Allen L. Sisk, and Gerald J. Bonnington; Evaluation of methylprednisolone and flurbiprofen for inhibition of the postoperative inflammatory response; *ORAL SURG. ORAL MED. ORAL. PATHOL.* 60~137-145, 1985)
6. MacGregor AJ, Addy A. Value of penicillin in the prevention of pain, swelling and trismus following the removal of ectopic mandibular third molars. *Int J Oral Surg* 1980;9:166-72.
7. Huffman GG. Use of methylprednisolone so-dium succinate to reduce postoperative edema after removal of impacted third molars. *J Oral Surg* 1977;35:198-9.
8. Pederson A. Decadron phosphate in the relief of complains after third molar surgery. *Int J Oral Maxillofac Surg*. 1985; 14: 235-40.
9. Milles M, Desjardins PJ. Reduction of postoperative facial swelling by low-dose methylprednisolone: an experimental study. *J Oral Maxillofac Surg*. 1993; 51: 987-91.
10. Esen E, Tasar F, Akhan O. Determination of the anti-inflammatory effects of methylprednisolone on the sequelae of third molar surgery. *J Oral Maxillofac Surg* 1999;57:1201-6.
11. Gabka J, Matsumara T. Measuring techniques and clinical testing of an anti-inflammatory agent (tantum). *Munch Med Wochenschr* 1971;13:198.
12. Bamgbose BO, Akinwande JA, Adeyemo WL, Ladeinde AL, Arotiba GT, Ogunlewe MO. Effects of co-administered dexamethasone and diclofenac potassium on pain, swelling and trismus following third molar surgery. *Head Face Med*. 2005;1:11.
13. Moore PA, Brar P, Smiga ER, Costello BJ. Preemptive rofecoxib and dexamethasone for prevention of pain and trismus following third molar surgery. *Oral Surg Oral Med Oral Pathol Oral Radiol Endod*. 2005;99:E1-7.

14. Micó-Llorens JM, Satorres-Nieto M, Gargallo-Albiol J, Arnabat- Domínguez J, Berini-Aytés L, Gay-Escoda C. Efficacy of methylprednisolone in controlling complications after impacted lower third molar surgical extraction. *Eur J Clin Pharmacol*. 2006;62:693-8.
15. Graziani F, D'Aiuto F, Arduino PG, Tonelli M, Gabriele M. Perioperative dexamethasone reduces post-surgical sequelae of wisdom tooth removal. A split-mouth randomized double-masked clinical trial. *Int J Oral Maxillofac Surg*. 2006;35: 241-6.
16. Buyukkurt MC, Gungormus M, Kaya O. The effect of a single dose prednisolone with and without diclofenac on pain, trismus, and swelling after removal of mandibular third molars. *J Oral Maxillofac Surg*. 2006;64:1761-6.
17. Zandi M. Comparison of corticosteroids and rubber drain for reduction of sequelae after third molar surgery. *Oral Maxillofac Surg*. 2008;12:29-33.
18. Vegas-Bustamante E, Micó-Llorens J, Gargallo-Albiol J, Satorres- Nieto M, Berini-Aytés L, Gay-Escoda C. Efficacy of methylprednisolone injected into the masseter muscle following the surgical extraction of impacted lower third molars. *Int J Oral Maxillofac Surg*. 2008;37:260-3.
19. Filho JRL, Maurette PE, Allais M, Cotinho M, Fernandes C. Clinical comparative study of the effectiveness of two dosages of dexamethasone to control postoperative swelling, trismus and pain after the surgical extraction of mandibular impacted third molars. *Med Oral Pathol Oral Cir Bucal*. 2008; 13:129-32.
20. Vaibhav Mukund, Sanjeev Kumar , Sukumar Singh , Rishi Rath , Siddharth Tevatia; Efficacy of various administrative techniques of methylprednisolone on oedema, trismus and pain after lower third molar surgery; *International Journal of Dental Research*, 5 (2) (2017) 186-190
21. G Koger E, Yuce a, Tuzuner Oncul, O Dereci, O. Koskan; Effect of the route of administration of methylprednisolone on oedema and trismus in impacted lower third molar surgery; *Int J Oral maxfac surg* 2014;43:639-643.
22. Chugh, A. Singh, Y. Mittal, V. Chugh; Submucosal injection of dexamethasone and methylprednisolone for the control of postoperative sequelae after third molar surgery: randomized controlled trial; *Int. J. Oral Maxillofac. Surg*. 2017.
23. Capuzzi P, Montebugnoli L, Vaccaro MA. Extraction of impacted third molars. A longitudinal prospective study on factors that affect postoperative recovery. *Oral Surg Oral Med Oral Pathol*. 1994;77:341-3.
24. Chopra D, Rehan HS, Mehra P, Kakkar AK. A randomized, double-blind, placebo-controlled study comparing the efficacy and safety of paracetamol, serratiopeptidase, ibuprofen and betamethasone using the dental impaction pain model. *Int J Oral Maxillofac Surg*. 2009;38:350-5.
25. Yakup Ustun, Ozgur Erdogan, Emin Esen and Ebru Denis karsli; Comparison of the effect of 2 doses of methylprednisolone on pain, swelling, and trismus after third molar surgery; (*Oral Surg Oral Med Oral Pathol Oral Red Endod* 2003;96:535)
26. Kang SH, Choi YS, Byun IY, Kim MK. Effect of preoperative prednisolone on clinical postoperative symptoms after surgical extractions of mandibular third molars. *Aust Dent J*. 2010;55:462-7.
27. Jorge Chaurand-Lara, Jose Alfredo Facio-Umaña; Methylprednisolone injection following the surgical extraction of impacted lower third molars: A split-mouth study; *Open Journal of Stomatology*, 2013, 3, 192-196 OJST
28. Majid OW, Mahmood WK. Effect of submucosal and intramuscular dexamethasone on postoperative sequelae after third molar surgery: comparative study. *Br J Oral Maxillofac Surg*. 2011; 49: 647-52
29. Neupert EA 3rd, Lee JW, Philput CB, Gordon JR. Evaluation of dexamethasone for reduction of postsurgical sequelae of third molar removal. *J Oral Maxillofac Surg*. 1992; 50:1177-82.