



Journal Homepage: -www.journalijar.com

INTERNATIONAL JOURNAL OF ADVANCED RESEARCH (IJAR)

Article DOI:10.21474/IJAR01/10919
DOI URL: <http://dx.doi.org/10.21474/IJAR01/10919>



RESEARCH ARTICLE

A STUDY OF BOTH-BONE FOREARM FRACTURES IN PEDIATRIC POPULATION - TREATED BY ELASTIC STABLE INTRAMEDULLARY NAILING WITH TITANIUM ELASTIC NAILING SYSTEM

Dr. K. Usha Sree and Dr. B. Someswara Reddy

Post Graduate, Professor and HOD, Department of Orthopedics, Santhiram Medical College and General Hospital, Nandyal.

Manuscript Info

Manuscript History

Received: 05 March 2020

Final Accepted: 07 April 2020

Published: May 2020

Key words:-

Both Bone Forearm, Elastic Stable Intramedullary Nailing, Titanium Elastic Nailing System

Abstract

Introduction: Diaphyseal fractures of the radius and ulna are one of the most common in the pediatric population estimated around 40% of all pediatric fractures. Conservative management with closed reduction and immobilization with above elbow cast can lead to malunion. The introduction of titanium elastic nailing system has changed the treatment scenario. The aim of this study is to evaluate the functional outcome of management of both bone forearm fractures by closed reduction and internal fixation with titanium elastic nail system.

Materials and Methods: A total of 20 patients aged 5-15 years with fracture of both radius and ulna were managed by internal fixation with titanium elastic nails. Closed reduction under image intensifier was achieved in most of the patients.

Results: Results were analysed in reference to union, range of movements of adjacent joints and symptoms. 86% showed excellent results, 8% showed good results, 6% showed fair results.

Conclusion: Better functional outcome with less complications were achieved with ESIN with TENS.

Copy Right, IJAR, 2020,. All rights reserved.

Introduction:-

Diaphyseal fractures of the radius and ulna are one of the most common in the pediatric population. About 75% of forearm fractures occur in the distal third, 15% occur in middle third, 5% occur in proximal third. Fractures of forearm of children are different than adults. Periosteum is thick and less likely to be torn. Greenstick and torus fractures occur exclusively in children. Conservative management with closed reduction and immobilization with above elbow cast can lead to malunion. The introduction of titanium elastic nailing system has changed the treatment scenario.

The titanium elastic nailing system (TENS) provides the following four properties: flexural stability, axial stability, translational stability, and rotational stability. All four properties are essential for achieving optimal results. The elastic stable intramedullary nailing has benefits of immediate stability to the involved bone segment which permits early mobilization and returns to normal activities with low complication rate.

Corresponding Author:- Dr. K. Usha Sree

Address:- Post Graduate, Professor and HOD, Department of Orthopedics, Santhiram Medical College and General Hospital, Nandyal.

Materials and Methods:-

A total of 20 patients aged 5-15 years with fracture of both radius and ulna were managed by internal fixation with titanium elastic nails. Closed reduction under image intensifier was achieved in most of the patients

Inclusion criteria:

1. a.Age 5-15 years
2. b.Displaced diaphyseal forearm fractures

Exclusion criteria:

1. a.Children <5 years and >15 years
2. b.Physal injury

Associated proximal and distal radioulnar joint disruption.

Surgical technique of tens nailing:

A patient was put in the supine position on operating table with the affected arm placed on a radiolucent arm table. Titanium elastic nails of appropriate diameter were chosen. The nail diameters were about half of the medullary isthmus of each bone. An awl was used to make entry point in the bones. Entry point in the radius was either just proximal to the radial styloid or through Lister's tubercle. The entry point in the ulna can be at the posterior aspect of the olecranon or a lateral approach through the proximal metaphysis. The retrograde entry point in the ulna was through the distal metaphysis. Because the radius is often more difficult to reduce, it should be splinted first. Radial nail was inserted manually with the inserter for TEN into the medullary canal, with the nail tip at right angles to the bone shaft. Then, the nail was rotated through 180° with the inserter and the nail tip was aligned with the axis of the medullary canal. The nail was advanced up to the fracture site. The radial nail tip was aligned with the medullary canal of the proximal fragment. Then, the nail was advanced into proximal fragment metaphysis. Ulna nail was then introduced and progressed in similar manner such as radius nail. When the nails were correctly positioned in the opposite metaphysis, protruding nail ends are cut approximately 1 cm from the bone. In most of our cases, closed reduction was done. In few cases, where closed reduction could not be achieved, mini- incision was given over fracture site for the reduction of fracture and internal fixation with titanium elastic nail done.

Postoperative:

POP given for 2 weeks for soft tissue healing. Early range of movements started.

Follow-up:

Every patient followed up at 4 weeks intervals till union occur.

Results:-

Results were analysed in reference to age, sex, mode of injury, time of union, complications.

Table 1:- Demographic Distribution.

AGE IN YEARS	NUMBER OF PATIENTS	%
5-10	6	30
11-15	14	70
TOTAL	20	100

Table 2:- Sex Distribution.

SEX	NUMBER OF PATIENTS	%
MALE	16	80
FEMALE	4	20
TOTAL	20	100

Table 3:- Mode Of Injury.

MODE OF INJURY	NUMBER OF PATIENTS	%
FALL	6	30
SPORTS	4	20

RTA	10	50
-----	----	----

Table 4:- Time Of Fracture Union.

TIME OF UNION	NUMBER OF PATIENTS	%
<10 WEEKS	8	40%
10-12WEEKS	10	50%
>12WEEKS	2	10%
TOTAL	20	100%

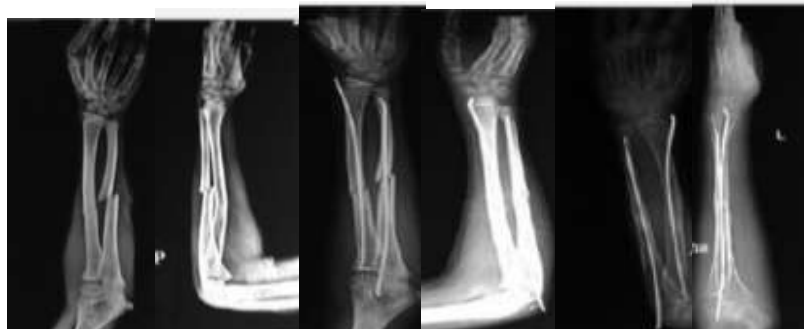
Table 5:- Complications.

COMPLICATIONS	NUMBER OF PATIENTS	%
INFECTION	2	10
REFRACTURE	0	0

Table 6:- Results Based On Price Et.Al Criteria.

RESULTS	NUMBER OF PATIENTS	%
EXCELLENT	16	80
GOOD	3	15
FAIR	1	5
POOR	0	0
TOTAL	20	100

Case 1:-



PRE OP XRAY

POST -OP

AFTER 3MONTHS

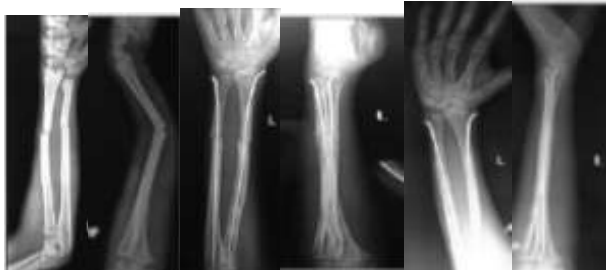


SUPINATION

PRONATION

FLEXION

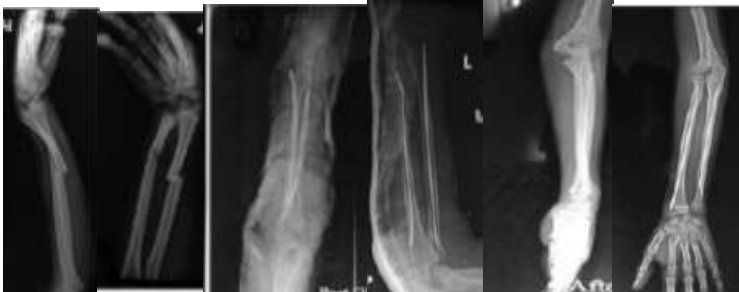EXTENSION

Case 2:

PRE-OP

POST-OP

AFTER 4 MONTHS

CASE 3:

PRE-OP

POST-OP

AFTER 12 WEEKS

Discussion:-

The forearm is a complex structure that play an important role in upper extremity function. The forearm bones can be considered struts linking the 2 halves of condylar joint formed by PRUJ and DRUJ. Any change in the geometry of radius and ulna alters the range of movements at the joint. Malunion especially causes functional problems at wrist and elbow.

The need for near perfect anatomical alignment is not always necessary because of the remodeling in the growing bone of child, and hence open reduction is rarely indicated.

The rule of thirds

1. If the fracture of the shaft is proximal to the insertion of the pronator teres, the forearm should be held in supination.
2. If the fracture is in the middle third, midprone position is advised.
3. If the fracture is held in the distal third, pronation is the position of choice.

Conclusion:-

Better functional outcome with less complications were achieved with ESIN with TENS.

Advantages of elastic nailing of paediatric forearm fractures is that it facilitates biological fixation of the fracture and promotes early fracture union.

The design of the Elastic nails does not interfere with periosteal circulation to the extent the plating does so, early union takes place and postoperative osteoporosis does not occur.

References:-

1. Jones K, Weiner DS. The management of forearm fractures in children A plea for conservatism. J PediatrOrthop1999;19:811-5.
2. Flynn JM, Waters PM, Skaggs DL. Rockwood and Wilkins Fractures InChildren. 8th ed. Philadelphia: Wolters Kluwer; 2015. p. 413-72.

3. Metaizeau JP, Ligier JN. Surgical treatment of fractures of long bones in children: Interference between osteosynthesis and physiological process of consolidations: Therapeutic indications. *J Chir (Paris)* 1984;121:527-37.
4. Johnson CW, Carmichael KD, Morris RP, Gilmer B. Biomechanical study of flexible intramedullary nails. *J Pediatr Orthop* 2009;29:44-8.
5. Dietz HG, Schmittenbecher P, Illing P. *Intramedullare Osteosynthesen im Wachstumsalter*. Munchen: Urban and Schwarzenberg; 1997.
6. Bellemans M, Lamoureux J. Indications for immediate percutaneous intramedullary nailing of complete diaphyseal forearm shaft fractures in children. *Acta Orthop Belg* 1995;61 Suppl 1:169-72.