



ISSN NO. 2320-5407

Journal homepage: <http://www.journalijar.com>

INTERNATIONAL JOURNAL
OF ADVANCED RESEARCH

RESEARCH ARTICLE

An atypical presentation of acrokeratosis verruciformis of Hopf- A case report

Rakesh Biswas¹, Th Bijayanti Devi²

1. Junior resident Department of Dermatology, Venereology, and Leprology, RIMS, IMPHAL

2. Professor and Head of the Department of Dermatology, Venereology, and Leprology, RIMS, IMPHAL

Manuscript Info

Manuscript History:

Received: 15 October 2015

Final Accepted: 22 November 2015

Published Online: December 2015

Key words:

Genodermatosis,

Acrokeratosisverruciformis of Hopf

*Corresponding Author

Rakesh Biswas

Abstract

Acrokeratosisverruciformis (AKV) of Hopf is a rare genodermatosis of keratinization disorder. It was first described by Hopf in 1931. It is usually present at birth and more common in males (M:F=5:1.3). Most common mode of inheritance is autosomal dominant. It is characterized by multiple flat topped skin colored wartykeratotic papules mainly over the dorsa of the hands and feet. We reported an atypical sporadic case of widespread AKV with minimal acral parts involvement in a 17-year-old girl due to its rarity.

Copy Right, IJAR, 2015.. All rights reserved

INTRODUCTION

Acrokeratosis verruciformis of Hopf (AKV) is a rare autosomal dominant (AD) cutaneous disorder first described by Hopf in 1931.^[1, 4, 5] It typically presents as multiple, small, flat, wart-like papules on right dorsa of hands and feet.^[2, 3, 4, 5, 6] The Nails may be whitish and thickened, and have longitudinal ridges breaking at distal edge.^[3, 4] Lesions are usually present at birth but may appear late in infancy or at puberty. It has unknown aetiology, affecting both sexes but is more common in males with male: female ratio of 5:1.3.^[4] An atypical sporadic case of widespread AKV with minimal acral parts involvement in a 17-year-old girl is hereby reported due to its rarity.

Case report:

A 17-year-old girl presented with numerous localized warty keratotic papular lesions all over the body with minimal acral parts involvement since birth. Family history was negative. Cutaneous examination showed multiple localized bilaterally symmetrical skin colored warty papules over the trunk, buttocks, extensor aspects of thighs, legs and flexural aspects of arms and forearms [Figure- 1, 2, 3] with minimal involvement of right dorsum of hand [Figure- 4, 5]. Oral mucosa, scalp, palmo-plantar areas, nails and acral parts of feet were not involved. Systemic examination was normal. Routine blood investigations were normal. Histopathology showed epidermal hyperkeratosis, regular acanthosis, focal papillomatosis resembling “church spire” like appearance [Figure- 6]. Dermis showed minimal pericapillary lymphocytic infiltration with no mucin or amyloid deposition.

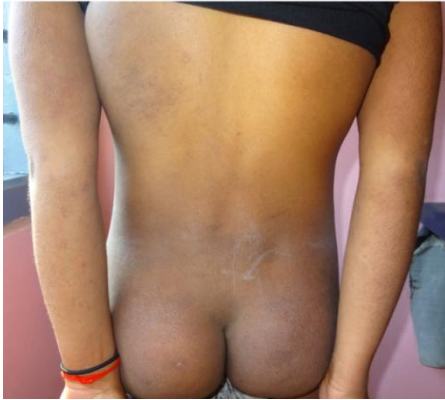

Fig.1 showing warty keratotic papules over the trunk, buttocks and extensors

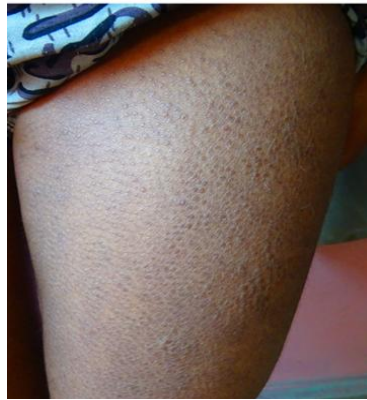

Fig.2 showing flat-topped warty papules

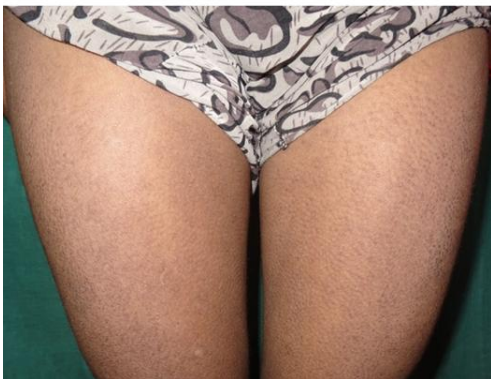

Fig. 3 symmetrical warty papules

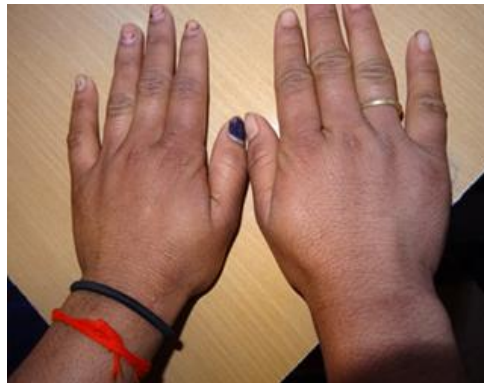

Fig.4 showing few warty papules over the dorsum of right lateral side of hand

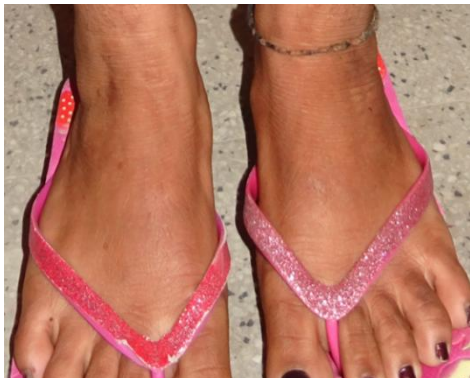

Fig.5 showing no involvement of feet

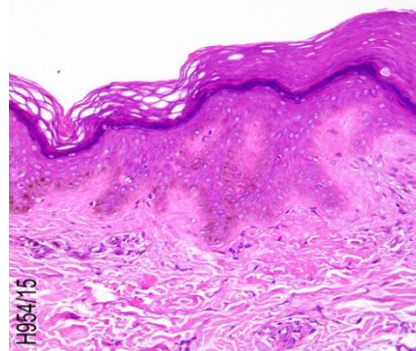


Fig.6 showing epidermal hyperkeratosis, regular acanthosis, resembling church spire appearance (H & E stain)

Discussion:

AKV is a disorder of keratinization, a genodermatosis with unknown aetiology. It is inherited by autosomal dominant mode of transmission with ATP2A gene mutation (Ca⁺ ATPase family) which is implicated in Darier's disease also.^[4, 5] AKV shows excessive but normal keratinization, whereas in Darier's disease keratinization is defective.^[1,3] Characteristic findings of AKV include asymptomatic, numerous, flat, hyperkeratotic, occasionally verrucous papules are present on the distal part of the extremities, predominantly on the dorsal aspects of the hands and feet. Small or isolated papules may develop on the knees, elbows, forearms and also on other parts of the body. The forehead, scalp, flexures, and the oral mucosa are never affected.^[1,4, 6] Histopathology classically shows considerable hyperkeratosis, an increased thickness of granular layer, acanthosis and slight papillomatosis. There is elevation of epidermis resembling church spire appearance.

No parakeratosis, dyskeratosis or viral cytopathic changes is seen.^[3,4,6] Clinically, this case was confused with flat warts, seborrheic keratosis, epidermodysplasia verruciformis, and acral Darier's disease, which was ruled out by histopathology. There is no curative treatment. Systemic and topical retinoids, keratolytic agents, and superficially ablative therapies such as peels, CO₂ or Nd:YAG laser, cryotherapy and acitretin can be used. Recurrence is quite frequent after the treatment.^[3,4,5,7]

Conclusion:

AKV of Hopf is a AD disease, which is characterized by multiple flat topped skin colored warty papular lesions occur typically on dorsal aspects of hands and feet.^[1,2,3,4,5,6,7] However in this case, there was predominant involvement of other body parts with minimal involvement of the right dorsum of hand with no family history.

We reported this case because of its rarity and atypical clinical presentation, which can be confused with the diseases like acral Darier's disease, seborrheic keratosis, ichthyosis vulgaris and keratosis pilaris.^[3] Furthermore, transformation to squamous cell carcinoma also has been reported.^[3,5]

References:

1. Nair PA. Acrokeratosiverruciformis of Hopf along lines of blaschko. *Indian J Dermatol* 2013;58(5):406.
2. Bang CH, Kim HS, Park YM, Kim HO, Lee JY. Non-familial acrokeratosiverruciformis of Hopf. *Anna Dermatol* 2011;23(11):S61-3.
3. Kalic B, Ozgun E. Isotretinoin treatment in Acrokeratosiverruciformis of Hopf. *J Turk Acad Dermatol* 2013;7(3):1373c3.
4. Ramesh M, Ramya N, MGGopal, Sharath BC, Nandini AS. Acrokeratosiverruciformis of Hopf: An association with polymorphic light eruption. *JEMDS* 2013;2(48):9310-4.
5. Potekar RM, Bhaswanth P, Ambica C, Arora S, Palur K. *JKIMSU* 2015;4(4):124-5.
6. Salman H and Osman W. Acrokeratosiverruciformis of Hopf (Hopf Disease). *J Infect Dis Ther* 2014;2(1):128.
7. Patel N, Diwan N, Nair PA. Nonfamilialacrokeratosiverruciformis of Hopf. *Indian Dermatol Online J* [serial online] 2015 [cited 2015 Nov 29];6(2):110-2.